

Effect of perioperative buccal fracture of the proximal segment on postoperative stability after sagittal split ramus osteotomy

Sang-Yoon Lee¹, Hoon Joo Yang^{1,2}, Jeong-Joon Han¹, Soon Jung Hwang^{1,2}

¹Department of Oral and Maxillofacial Surgery, Seoul National University Dental Hospital, School of Dentistry, Brain Korea Plus, Seoul National University, ²Dental Research Institute, Seoul National University, Seoul, Korea

Abstract (J Korean Assoc Oral Maxillofac Surg 2013;39:217-223)

Objectives: Buccal fracture of the mandibular proximal bone segment during bilateral sagittal split ramus osteotomy (SSRO) reduces the postoperative stability. The primary aim of this study is to evaluate the effect of this type of fracture on bone healing and postoperative stability after mandibular setback surgery.

Materials and Methods: Ten patients who experienced buccal fracture during SSRO for mandibular setback movement were evaluated. We measured the amount of bone generation on a computed tomography scan, using an image analysis program, and compared the buccal fracture side to the opposite side in each patient. To investigate the effect on postoperative stability, we measured the postoperative relapse in lateral cephalograms, immediately following and six months after the surgery. The control group consisted of ten randomly-selected patients having a similar amount of set-back without buccal fracture.

Results: Less bone generation was observed on the buccal fracture side compared with the opposite side ($P < 0.05$). However, there was no significant difference in anterior-posterior postoperative relapse between the group with buccal fracture and the control group. The increased mandibular plane angle and anterior facial height after the surgery in the group with buccal fracture manifested as a postoperative clockwise rotation of the mandible.

Conclusion: Bone generation was delayed compared to the opposite side. However, postoperative stability in the anterior-posterior direction could be maintained with rigid fixation.

Key words: Mandibular fracture, Sagittal split ramus osteotomy, Fracture healing, Postoperative stability

[paper submitted 2013. 7. 11 / revised 2013. 8. 14 / accepted 2013. 8. 28]

I. Introduction

Sagittal split ramus osteotomy (SSRO) is one of the most common techniques used in orthognathic surgery because its wide contact area provides post-operative stability in mandibular advancement and setback surgery. After its introduction by Trauner and Obwegeser¹, SSRO has been modified by several surgeons to improve the surgical technique and outcomes²⁻⁵.

Unexpected fracture or split with buccal fracture of the

proximal segment and lingual fracture of the distal segment during SSRO is one of the most common complications⁶⁻⁸. The incidence ranges from 0.5% to 5.4%⁸. Mehra et al.⁴ reported a 1.4% incidence of unfavorable lingual fracture (mostly in cases of impacted third molar of the mandible) and a 0.8% incidence of buccal fracture of the proximal segment. Another study reported a 4% incidence of proximal segment fracture⁶.

Considering the common bone healing process, unfavorable fracture can result in poor bone healing including delayed union, mal-union, or fibrous union⁴. It is thought to lead to post-operative instability after orthognathic surgery; note, however, that there has been no report of post-operative stability in cases with unexpected fracture, especially buccal fracture of the proximal segment.

The aims of this study were (1) to evaluate the difference in bone healing according to buccal plate fracture by comparing the fractured side with the unfractured side of a patient and; (2) to investigate post-operative stability in cases with

Soon Jung Hwang

Department of Oral and Maxillofacial Surgery, School of Dentistry, Seoul National University, 101, Daehak-ro, Jongno-gu, Seoul 110-768, Korea
TEL: +82-2-2072-3061 FAX: +82-2-766-4948
E-mail: sjhwang@snu.ac.kr

© This is an open-access article distributed under the terms of the Creative Commons Attribution Non-Commercial License (<http://creativecommons.org/licenses/by-nc/3.0/>), which permits unrestricted non-commercial use, distribution, and reproduction in any medium, provided the original work is properly cited.

Copyright © 2013 The Korean Association of Oral and Maxillofacial Surgeons. All rights reserved.

unexpected buccal fracture.

II. Materials and Methods

Ten patients who had complete buccal fracture of the proximal segment during orthognathic surgery were evaluated.(Fig. 1) The inclusion criteria were as follows: (1) undergoing SSRO to correct mandibular prognathism; (2) complete buccal fracture occurring on only one side of the mandible (those with incomplete or greenstick fractures were excluded); and (3) at least six months' post-operative follow-up. After the evaluation of post-operative computed tomography (CT), only the patients in whom the proximal segment was positioned to have direct contact with the cortical bone of the distal segment in the second molar area were selected. Therefore, the amount of dead space for new bone formation was similar in all patients. The patients consisted of five men and five women with mean age of 22.3 ± 4.8 years at the time of surgery. Seven patients underwent bimaxillary surgery, whereas three patients had SSRO only.

SSRO was performed according to the Wolford method⁹. Horizontal ramus osteotomy on the lingual side was done above the lingula. Sagittal osteotomy was carried out on the buccal cortex. Buccal vertical osteotomy was performed between the first and second molars. Splitting of the mandible was done using wedge osteotomes.

All cases of proximal segments with buccal plate fracture were stabilized using long mini-plate and monocortical screws with an additional bicortical positioning screw.(Fig. 1) The proximal segments were adjusted to the buccal side of the distal segment as intimately as possible by slightly

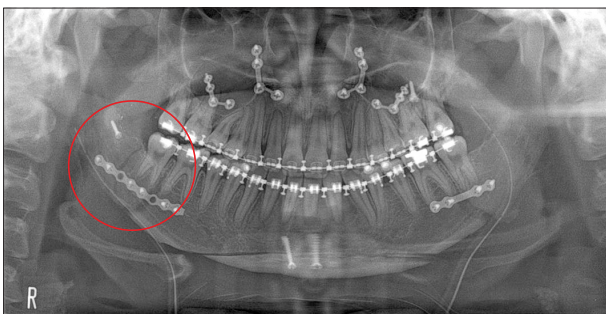


Fig. 1. Rigid fixation of a buccal fracture of the proximal segment. The buccal fracture on the right side was stabilized using long mini-plate and monocortical screws and additional bicortical positional screw (circle).

Sang-Yoon Lee et al: Effect of perioperative buccal fracture of the proximal segment on postoperative stability after sagittal split ramus osteotomy. J Korean Assoc Oral Maxillofac Surg 2013

bending the mini-plate to optimize bone healing. In addition, one positional bicortical screw was used to enhance the rigid stabilization of the proximal segment including the fractured segment.

1. Evaluation of bone healing

The fractured side was compared with the opposite side of the same patient. Bone regeneration between the proximal and distal segments was evaluated based on the axial images of post-operative CT, which was performed 3.5 ± 1.5 months after surgery (mean) using the image analyzing program Image J. Image J is freely available from the NIH Web site (<http://rsb.info.nih.gov/ij>) bundled with Java. Three axial cuts were evaluated, with the mean value calculated on each side. The axial cut demonstrating the widest intersegmental space was selected. Two additional axial cuts above and below the selected cut were then chosen. First, the total intersegmental area (threshold below 210 in the Image J program) between the proximal segment and distal segments was defined. Second, the area of newly formed bone (threshold from 190 to 210 in the Image J program) was extracted from the intersegmental area. Finally, the ratio of new bone area to the total intersegmental area was calculated.(Fig. 2)

2. Evaluation of post-operative stability

For the control group (CG), ten patients who did not have buccal plate fractures were randomly selected from patients who had similar amounts of mandibular setback movement compared to patients with buccal plate fractures, who were classified as the experimental group (EG).

All patients underwent standardized lateral cephalograms before surgery (T0), immediately after surgery (T1), and more than six months after surgery (T2). The lateral cephalograms were traced on acetate paper, which was superimposed by the same examiner to evaluate surgical movement (T1-T0) and post-operative stability (T2-T1).

Post-operative stability was evaluated by measuring changes in reference points and reference planes: sella (S), nasion (N), menton (Me), gonion (Go), point B (B), overjet (OJ), overbite (OB), x-axis (SN7, a line drawn 7° lower to the S-N line), y-axis (SN7V, a line on the nasion and perpendicular to SN7).(Fig. 3)

The horizontal reference plane (SN7) and vertical reference plane (SN7V) were drawn on acetate paper¹⁰⁻¹². The vertical distance from the horizontal reference plane to B (SN7-B

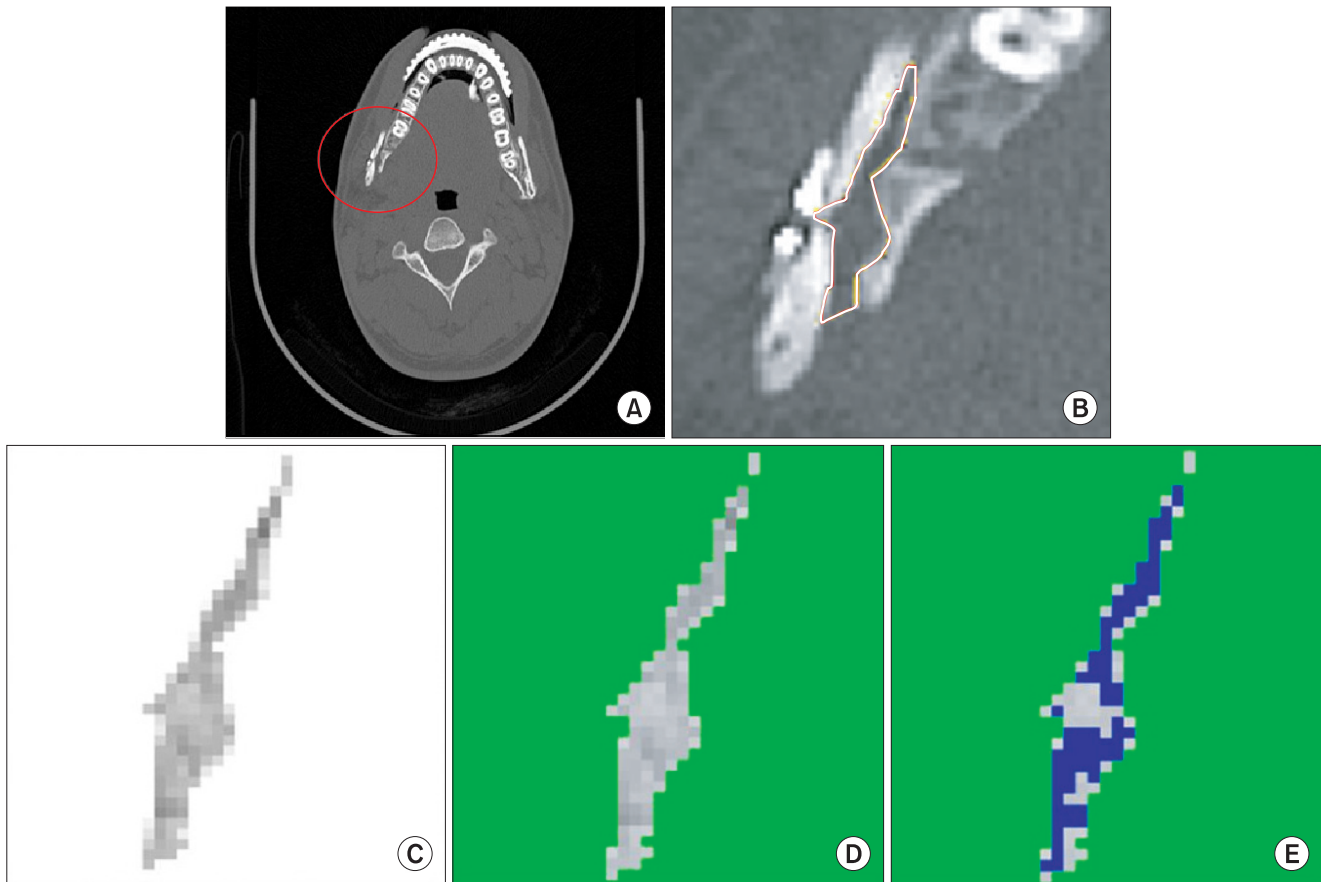


Fig. 2. Evaluation of bone regeneration using Image J. A. The buccal fracture was occurred on right proximal segment (circle). B. The total inter-segmental area between the proximal and distal segments was defined based on the axial computed tomography image. C. The total inter-segmental area was adjusted to the threshold below 210 in the Image J program, where the threshold of cortical and medullar bone was greater than 210. D, E. The area of newly formed bone (threshold from 190 to 210 in the Image J program) was extracted from the total inter-segmental area. Soft tissue and dead space (threshold below 190) were also removed. Finally, the ratio of new bone area to total inter-segmental area was calculated.

Sang-Yoon Lee et al: Effect of perioperative buccal fracture of the proximal segment on postoperative stability after sagittal split ramus osteotomy. *J Korean Assoc Oral Maxillofac Surg* 2013

vertical) and the horizontal distance from vertical reference plane to B (SN7V-B horizontal) were then calculated to analyze post-operative relapse (T2-T1). Other values such as mandibular plane angle (SN-MeGo), posterior facial height (S-Go), anterior facial height (N-Me), ratio between the posterior and anterior facial heights (S-Go/N-Me), SNB, OJ, and OB were also evaluated. The post-operative stability of EG was compared with CG.

3. Statistical analysis

We used PASW 18.0 software (IBM Co., Armonk, NY, USA) for statistical analysis. A Kolmogorov-Smirnov test was performed to compare the data to a standard normal distribution. Paired t test was used to compare bone regeneration on the fractured side with that of the non-fractured side. The Mann-Whitney U test was used to evaluate the effect of buc-

cal plate fracture on post-operative stability. A P -value < 0.05 was considered statistically significant.

III. Results

1. Bone regeneration

The average ratio of new bone formation on the fractured side was 0.53 ± 0.11 (0.39-0.76), and that of the non-fractured side was 0.68 ± 0.14 (0.54-1.00). The difference between the fractured side and non-fractured side was statistically significant ($P < 0.05$). (Fig. 4)

2. Post-operative stability

The mean surgical movement at point B was 2.13 ± 2.62 mm superiorly and 9.97 ± 3.72 mm posteriorly in EG and 078

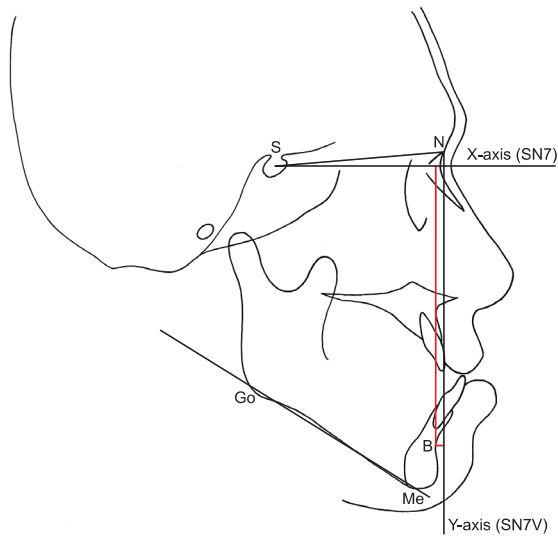


Fig. 3. Post-operative stability was evaluated by measuring the changes in reference points and reference planes: sella (S), nasion (N), x-axis (SN7, a line drawn 7° lower to the S-N line), y-axis (SN7V, a line on the N and perpendicular to SN7), point B (B), menton (Me), gonion (Go).

Sang-Yoon Lee et al: Effect of perioperative buccal fracture of the proximal segment on postoperative stability after sagittal split ramus osteotomy. J Korean Assoc Oral Maxillofac Surg 2013

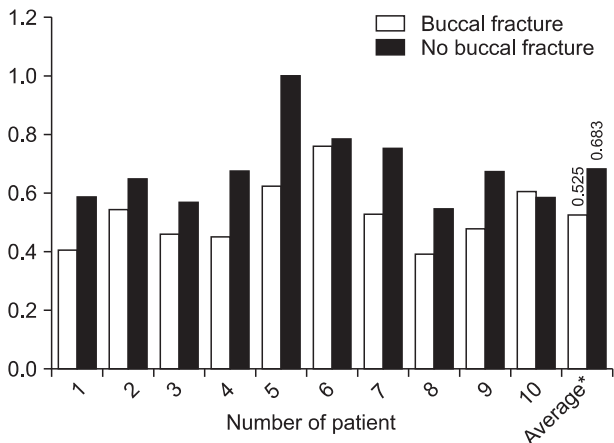


Fig. 4. Comparison of new bone formation between the buccal fracture side and non-fractured side. Bone healing was significantly delayed on the fractured side compared with the opposite side. * $P=0.019$.

Sang-Yoon Lee et al: Effect of perioperative buccal fracture of the proximal segment on postoperative stability after sagittal split ramus osteotomy. J Korean Assoc Oral Maxillofac Surg 2013

± 2.29 mm superiorly and 9.98 ± 3.63 mm posteriorly in CG. All parameters for surgical movement (B point, anterior and posterior facial heights and their ratio, SNB, OJ, and OB) showed no significant difference between the two groups. (Fig. 5)

Mean post-operative changes at point B were 0.29 ± 1.35 mm superiorly and 1.30 ± 2.19 mm anteriorly in EG and 1.36

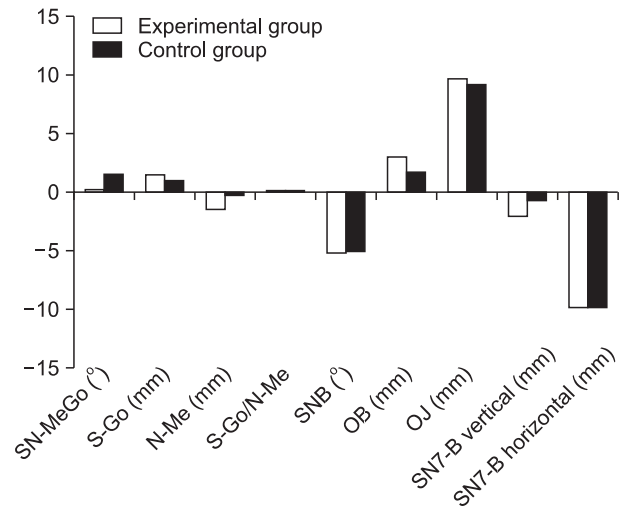


Fig. 5. Surgical movement in the experimental group and control group. There were no significant differences between the two groups ($P < 0.05$). (SN-MeGo: mandibular plane angle, S-Go: posterior facial height, N-Me: anterior facial height, SNB: SN to NB, OB: overbite, OJ: overjet, SN7-B vertical: vertical change of B point by surgery, SN7V-B horizontal: horizontal change of B point by surgery)

Sang-Yoon Lee et al: Effect of perioperative buccal fracture of the proximal segment on postoperative stability after sagittal split ramus osteotomy. J Korean Assoc Oral Maxillofac Surg 2013

± 1.19 mm superiorly and 1.99 ± 1.89 mm anteriorly in CG. There were no significant differences in horizontal or vertical relapse between the two groups. Note, however, that there were significant differences in the change of mandibular plane angle (SN-MeGo) and anterior facial height (N-Me) between EG and CG. The mandibular plane angle increased post-operatively in EG ($1.32 \pm 1.88^\circ$) but decreased in CG ($-0.54 \pm 1.34^\circ$) ($P < 0.05$). Anterior facial height decreased less in EG (-0.35 ± 1.23) than in CG (-1.57 ± 1.29) ($P < 0.05$). (Fig. 6) In terms of other post-operative changes, those in EG showed greater clockwise rotation of the mandible despite good anterior-posterior stability.

IV. Discussion

As previously mentioned, there is high incidence of buccal fracture in the SSRO procedure. Third molars, age at operation, sex, class of occlusion, and experience of the surgeon have been previously identified as risk factors for buccal fracture during SSRO. Still, some studies insist that the removal of the third molar at the same time as SSRO was the only predictive factor, and that there was no significant association with the others¹³. Others suggested the age at the time of the operation and the presence of third molars as predictors¹⁴. Literature shows that there is still controversy as to the risk

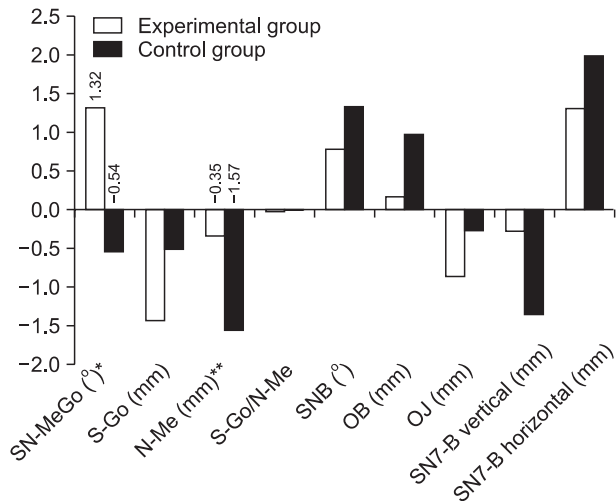


Fig. 6. Post-operative changes of parameters in the experimental group and control group six months after surgery (T2-T1). There were no significant differences between the two groups, except in mandibular plane angle (SN-MeGo) and anterior facial height (N-Me). $P < 0.05$, $*P = 0.015$, $**P = 0.029$. (S-Go: posterior facial height, SNB: SN to NB, OB: overbite, OJ: overjet, SN7-B vertical: vertical change of B point by surgery, SN7V-B horizontal: horizontal change of B point by surgery)

Sang-Yoon Lee et al: Effect of perioperative buccal fracture of the proximal segment on postoperative stability after sagittal split ramus osteotomy. *J Korean Assoc Oral Maxillofac Surg* 2013

factors for buccal fracture during SSRO.

In our study, the mean age of the patients with buccal fracture was 22.3 years (range, 18-34 years). Seven of ten patients with buccal fracture had a third molar on the fractured side. Six of them had an extracted third molar more than 1 year before surgery, and one underwent surgery with the third molar intact. The presence of a third molar, rather than the age, seems to increase the risk of buccal fracture.

Many studies have been performed to find ways to prevent and manage the unfavorable split of the mandible because there can be several complications such as infection, sequestration of bone fragment, delayed bone healing, pseudoarthrosis, post-operative instability, relapse, or dysfunction of the mandible with subsequent TMJ dysfunction^{4,14-19}. Among these, the disturbance of bony union is a main concern since this can cause the sequestration of the fractured segment and an increase in infection rate^{19,20}.

There are two basic fracture-healing processes: indirect (secondary) and direct (primary)²¹. As the most common form of fracture healing, indirect fracture healing consists of both endochondral and intramembranous bone²². Direct healing does not occur in the natural fracture healing process because it requires correct anatomical reduction of the fractured ends and rigid fixation. This type of healing is the primary

goal after open reduction and internal fixation²¹. Direct bone healing can occur through the direct remodeling of lamellar bone, Haversian canals, and blood^{21,23}. It can occur through contact healing (gap < 0.01 mm and interfragmentary strain < 2%) or gap healing (gap < 0.8 mm to 1 mm)^{24,25}. Interfragmentary gap size and resistance to strain by muscle force from surrounding tissue are important factors in the bone healing of an osteotomy gap; therefore, osteosynthesis with rigid fixation plays an important role in this process²⁶. Moreover, studies have suggested that rigid internal fixation results in a lower rate of infection and a lower risk of mal-union or non-union²⁷. A lower incidence of infection due to the absence of interfragmentary mobility has been reported²⁸.

We used additional positional screw and long mini-plate and monocortical screws to stabilize the segment for the decrease in inter-segmental gap size and increase in resistance to strain. There have been many studies on rigid fixation with plates and positional screws. Some studies reported no significant difference in the stability of the mandible after SSRO when comparing positional screws with plates²⁹. Note, however, that Hammer et al.³⁰ concluded that the screws in the area of overlapping bone should engage both fragments to increase the stability of mini-plate fixation. In their study, the group wherein only a mini-plate was fixed showed significantly decreased stability in comparison with the group using an additional positional screw. Nonetheless, there was no significant difference between the group that had a mini-plate with additional positional screw and the group employing three positional screws³⁰.

Bone healing on the fractured side was delayed in our study. Delayed bone healing may be influenced by reduced blood supply, osteogenic cells, and unstable fixation of the bone fragment. Therefore, some authors recommend inter-maxillary fixation (IMF) when a bad split occurs to ensure proper bone healing³¹. IMF should be considered carefully after the evaluation of extension and fixation of buccal plate fracture, since prolonged IMF may cause functional problems such as limitation of mouth opening²⁰. Moreover, a small buccal plate fracture does not usually require any change in the postsurgical treatment plan since this sort of split does not lead to functional impairment^{19,20}.

To enhance bone healing on the fractured side, the application of bone substitutes, stem cells, and growth factors including bone morphogenetic proteins should be considered³². Autogenic bone fragments derived from osteotomy can be crushed into particle bone and used as bone substitute. If this is not possible, demineralized bone matrix (DBM) is a good

option as allograft material, and growth factors are becoming more available; thus enhancing the osteoinductive properties³³. Because DBM lacks structural properties, it is recommended for use only as gap filler in non-weight-bearing areas³⁴. To supply osteoprogenitor cells, bone marrow stem cells can be used. Bone marrow contains osteoprogenitor stem cells that are able to form bone when combined with various elements incorporated into an osseous matrix³⁵.

Relapse caused by the clockwise (opening) rotation of the distal segment in the sagittal plane is one of the post-operative complications that are sometimes seen after SSRO. The force involved in this movement is primarily exerted by the masticatory and suprahyoid muscles³⁶. In our study, patients with buccal fracture showed increased mandibular plane angle and anterior facial height. Such clockwise rotation of the distal segment seems to be related to decreased post-operative stability.

V. Conclusion

In our study, there were no significant differences in the anterior-posterior relapse of the mandible between EG and CG. Additional rigid fixation using a positional screw holding the bone segments may have contributed to the stable result. Note, however, that there were significant differences in the mandibular plane angle and anterior facial height between EG and CG despite similar and small amounts of surgical movements in both parameters. EG had increased mandibular plane angle and anterior facial height compared with CG. Our results demonstrate that the mini-plate with additional bicortical positional screw is not sufficient to resist the post-operative clockwise rotation of the mandible.

References

1. Trauner R, Obwegeser H. The surgical correction of mandibular prognathism and retrognathia with consideration of genioplasty. I. Surgical procedures to correct mandibular prognathism and reshaping of the chin. *Oral Surg Oral Med Oral Pathol* 1957;10:677-89.
2. Dal pont G. Retromolar osteotomy for the correction of prognathism. *J Oral Surg Anesth Hosp Dent Serv* 1961;19:42-7.
3. Hunsuck EE. A modified intraoral sagittal splitting technic for correction of mandibular prognathism. *J Oral Surg* 1968;26:250-3.
4. Mehra P, Castro V, Freitas RZ, Wolford LM. Complications of the mandibular sagittal split ramus osteotomy associated with the presence or absence of third molars. *J Oral Maxillofac Surg* 2001;59:854-8.
5. Moos KF, Ayoub AF. The surgical correction of dentofacial deformities, past, present and future. *Egypt J Oral Maxillofac Surg* 2010;1:2-6.
6. van Merkesteyn JP, Groot RH, van Leeuwen R, Kroon FH. Intra-operative complications in sagittal and vertical ramus osteotomies. *Int J Oral Maxillofac Surg* 1987;16:665-70.
7. Bays RA, Bouloux GF. Complications of orthognathic surgery. *Oral Maxillofac Surg Clin North Am* 2003;15:229-42.
8. Falter B, Schepers S, Vrielinck L, Lambrechts I, Thijs H, Politis C. Occurrence of bad splits during sagittal split osteotomy. *Oral Surg Oral Med Oral Pathol Oral Radiol Endod* 2010;110:430-5.
9. Wolford LM, Bennett MA, Rafferty CG. Modification of the mandibular ramus sagittal split osteotomy. *Oral Surg Oral Med Oral Pathol* 1987;64:146-55.
10. Eggenesperger N, Smolka W, Rahal A, Iizuka T. Skeletal relapse after mandibular advancement and setback in single-jaw surgery. *J Oral Maxillofac Surg* 2004;62:1486-96.
11. Eggenesperger N, Smolka K, Luder J, Iizuka T. Short- and long-term skeletal relapse after mandibular advancement surgery. *Int J Oral Maxillofac Surg* 2006;35:36-42.
12. Yang HJ, Hwang SJ. Postoperative stability following maxillary downward movement with Le Fort I inclined osteotomy at the lateral nasal cavity wall. *J Craniomaxillofac Surg* 2012;40:793-8.
13. Mensink G, Verweij JP, Frank MD, Eelco Bergsma J, Richard van Merkesteyn JP. Bad split during bilateral sagittal split osteotomy of the mandible with separators: a retrospective study of 427 patients. *Br J Oral Maxillofac Surg* 2013;51:525-9.
14. Kriwalsky MS, Maurer P, Veras RB, Eckert AW, Schubert J. Risk factors for a bad split during sagittal split osteotomy. *Br J Oral Maxillofac Surg* 2008;46:177-9.
15. O'Ryan F. Complications of orthognathic surgery. *Oral Maxillofac Surg Clin North Am* 1990;2:593-601.
16. Patterson AL, Bagby SK. Posterior vertical body osteotomy (PVBO): a predictable rescue procedure for proximal segment fracture during sagittal split ramus osteotomy of the mandible. *J Oral Maxillofac Surg* 1999;57:475-7.
17. Tucker MR. Prevention and management of bad splits in sagittal split osteotomies. *J Oral Maxillofac Surg* 2004;62:14.
18. O'ryan F, Poor DB. Completing sagittal split osteotomy of the mandible after fracture of the buccal plate. *J Oral Maxillofac Surg* 2004;62:1175-6.
19. Chrcanovic BR, Freire-Maia B. Risk factors and prevention of bad splits during sagittal split osteotomy. *Oral Maxillofac Surg* 2012;16:19-27.
20. Veras RB, Kriwalsky MS, Hoffmann S, Maurer P, Schubert J. Functional and radiographic long-term results after bad split in orthognathic surgery. *Int J Oral Maxillofac Surg* 2008;37:606-11.
21. Marsell R, Einhorn TA. The biology of fracture healing. *Injury* 2011;42:551-5.
22. Gerstenfeld LC, Alkhiary YM, Krall EA, Nicholls FH, Stapleton SN, Fitch JL, et al. Three-dimensional reconstruction of fracture callus morphogenesis. *J Histochem Cytochem* 2006;54:1215-28.
23. LaStayo PC, Winters KM, Hardy M. Fracture healing: bone healing, fracture management, and current concepts related to the hand. *J Hand Ther* 2003;16:81-93.
24. Shapiro F. Cortical bone repair. The relationship of the lacunar-canalicular system and intercellular gap junctions to the repair process. *J Bone Joint Surg Am* 1988;70:1067-81.
25. Kaderly RE. Primary bone healing. *Semin Vet Med Surg (Small Anim)* 1991;6:21-5.
26. Augat P, Margevicius K, Simon J, Wolf S, Suger G, Claes L. Local tissue properties in bone healing: influence of size and stability of the osteotomy gap. *J Orthop Res* 1998;16:475-81.
27. Haranal SR, Neeli AS, Suryavanshi RK, Kotrashetti SM, Naresh N. Titanium lag screw osteosynthesis in the management of mandibular fractures. *Int Multidiscip Res J* 2012;2:5-8.
28. Assael LA. Evaluation of rigid internal fixation of mandible fractures performed in the teaching laboratory. *J Oral Maxillofac Surg* 1993;51:1315-9.
29. Nooh N. Stability of the mandible after bilateral sagittal split osteotomy: comparison between positioning screws and plate. *Saudi*

- Dent J 2009;21:123-6.
30. Hammer B, Ettlin D, Rahn B, Prein J. Stabilization of the short sagittal split osteotomy: in vitro testing of different plate and screw configurations. *J Craniomaxillofac Surg* 1995;23:321-4.
 31. Epker BN, Fish LC. *Dentofacial deformities*. Vol. 1. St. Louis: Mosby; 1986:232-4.
 32. Vertenten G, Gasthuys F, Cornelissen M, Schacht E, Vlamincck L. Enhancing bone healing and regeneration: present and future perspectives in veterinary orthopaedics. *Vet Comp Orthop Traumatol* 2010;23:153-62.
 33. Kao ST, Scott DD. A review of bone substitutes. *Oral Maxillofac Surg Clin North Am* 2007;19:513-21.
 34. Hoffer MJ, Griffon DJ, Schaeffer DJ, Johnson AL, Thomas MW. Clinical applications of demineralized bone matrix: a retrospective and case-matched study of seventy-five dogs. *Vet Surg* 2008;37:639-47.
 35. Tiedeman JJ, Connolly JF, Strates BS, Lippiello L. Treatment of nonunion by percutaneous injection of bone marrow and demineralized bone matrix. An experimental study in dogs. *Clin Orthop Relat Res* 1991;(268):294-302.
 36. Matsushita K, Inoue N, Totsuka Y. In vitro biomechanical evaluation of the effect of an additional L-shaped plate on straight or box plate fixation in sagittal split ramus osteotomy using a bioabsorbable plate system. *Oral Maxillofac Surg* 2011;15:139-46.