

## Removal of a broken needle using three-dimensional computed tomography: a case report

Jin-Ha Kim<sup>1</sup>, Seong-Yong Moon<sup>2</sup>

<sup>1</sup>Dental Clinic, The Third Logistic Support Command, Incheon,

<sup>2</sup>Department of Oral and Maxillofacial Surgery, School of Dentistry, Chosun University, Gwangju, Korea

**Abstract** (J Korean Assoc Oral Maxillofac Surg 2013;39:251-253)

Inferior alveolar nerve block obtained maximum anesthetic effect using a small dose of local anesthetic agent, which also has low a complication incidence. Complications of an inferior alveolar nerve block include direct nerve damage, bleeding, trismus, temporary facial nerve palsy, and etc. Among them, the major iatrogenic complication is dental needle fracture. A fragment that disappears into the soft tissue would be hard to remove, giving rise to a legal problem. A 31-year-old woman was referred for the removal of a broken needle, following an inferior alveolar nerve block. Management involved the removal of the needle under local anesthesia with pre- and peri-operative computed tomography scans.

**Key words:** Broken dental needle, Inferior alveolar nerve block, Cone-beam computed tomography, Foreign body migration

[paper submitted 2013. 7. 8 / revised 2013. 8. 28 / accepted 2013. 9. 13]

### I. Introduction

Inferior alveolar nerve block anesthesia is one of the most popular methods, and most clinicians use it effectively without serious side effects. Despite the low incidence, however, various complications can develop. Complications related to inferior alveolar nerve block anesthesia can be divided into two large groups, i.e., during and after operation<sup>1</sup>. Complications during operation are needle breakage, pain at injection, hypersensitivity or allergy, overdosage and toxicity, and lack of effect; those after operation include hematoma, trismus, postoperative paresthesia, or neuralgia<sup>1</sup>.

Among these complications during operation, needle breakage is a rare complication nowadays<sup>2</sup>. To date, however, a few cases, though not many, are continuously being reported. Actually, needle breakage has not been reported to cause severe complications such as damage to important anatomical

structures (blood vessels and nerve). Still, it causes a lot of fear to both dentists and patients<sup>3,4</sup>. The prevalence rate is low since most dentists know the causes of these complications, such as weakness of the alloy, narrowness of the needle, re-usage of the needle, incorrect technique, sudden movement of the patient or practitioner, manufacturing defects, and bending<sup>1,5-7</sup>.

As to the development of material, disposable dental needles are made of flexible stainless steel and are more durable than the previous ones<sup>8,9</sup>. Note, however, that the needle can be broken more easily when bent or improperly used with incorrect block anesthesia method<sup>7</sup>.

This is a case report of a broken dental needle due to sudden movement during inferior alveolar nerve block anesthesia, which was positioned between the coronoid process and condyle neck area. Management involved the removal of the needle under local anesthesia with pre- and peri-operative computed tomography (CT) scans.

### II. Case Report

A 31-year-old female patient was referred by a local clinic to the Department of Oral and Maxillofacial Surgery of the Chosun University Dental Hospital for the removal of a broken dental needle. When she underwent inferior alveolar block, she tilted her head quickly because of the shock sensa-

#### *Seong-Yong Moon*

Department of Oral and Maxillofacial Surgery, School of Dentistry, Chosun University, 309, Pilmun-daero, Dong-gu, Gwangju 501-759, Korea  
TEL: +82-62-220-3817 FAX: +82-62-228-7316  
E-mail: msygood@chosun.ac.kr

©This is an open-access article distributed under the terms of the Creative Commons Attribution Non-Commercial License (<http://creativecommons.org/licenses/by-nc/3.0/>), which permits unrestricted non-commercial use, distribution, and reproduction in any medium, provided the original work is properly cited.

Copyright © 2013 The Korean Association of Oral and Maxillofacial Surgeons. All rights reserved.

tion. The fragment disappeared into the tissues, and the dental clinician was unable to retrieve it.

Firstly, she referred to another hospital for removal of the broken needle, and they tried to remove the needle using CT images but failed, and then she was recommended general anesthesia from the doctor before visiting our department.

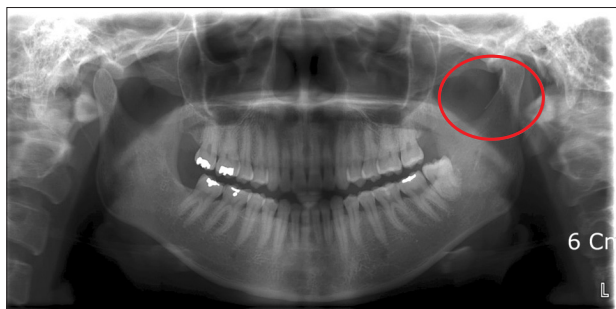
When she visited our department, she had a difficulty to open the mouth due to previous surgery. The fractured needle was found in the panoramic view (Fig. 1), which was located in the left condylar neck area. Likewise, cone beam CT was taken, and three-dimensional (3D) image was made.(Fig. 2)

Local anesthesia was performed via mandibular nerve block. We made about 6-7 cm vertical incision along the external oblique ridge, and then subperiosteal flap was elevated to expose the medial and lateral aspects of the ramus. The suture needle was positioned to the peri-condylar area

as the suspected location of the broken needle based on the pre-operative CT scan. Afterward, CT scan was performed. The location of the broken needle was identified in the peri-operative cone beam CT.(Fig. 3) Through blunt dissection around the peri-condylar area, we found the broken needle fragment and finally removed it. After removal, the patient took a panorama for the confirmation of the removal (Fig. 4), and the operation time was about 30 minutes.

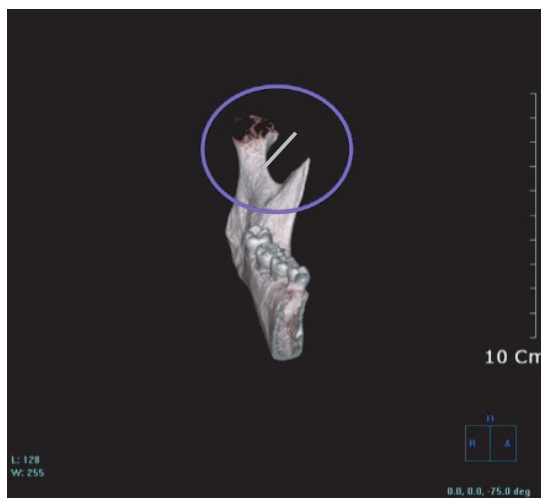
### III. Discussion

Needle breakages are well recognized to be more common with a small-diameter needle, often occurring at the hub<sup>5,8,9</sup>. In addition, bending the needle weakens it, as can any significant change in the direction of the needle located deep in the tissues. Finally, a 30-gauge needle often has to be inserted



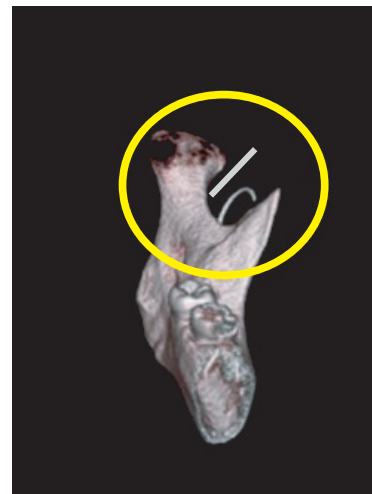**Fig. 1.** The broken needle was shown in the left mandibular peri-condylar area in panoramic view.

*Jin-Ha Kim et al: Removal of a broken needle using three-dimensional computed tomography: a case report. J Korean Assoc Oral Maxillofac Surg 2013*



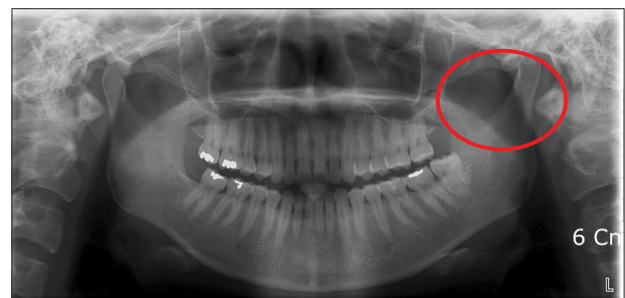
**Fig. 2.** The broken needle was shown in the left mandibular peri-condylar area in three-dimensional computed tomography view.

*Jin-Ha Kim et al: Removal of a broken needle using three-dimensional computed tomography: a case report. J Korean Assoc Oral Maxillofac Surg 2013*



**Fig. 3.** The broken needle was shown to be positioned in the left mandibular peri-condylar area in three-dimensional computed tomography view with the suture needle for localization during operation.

*Jin-Ha Kim et al: Removal of a broken needle using three-dimensional computed tomography: a case report. J Korean Assoc Oral Maxillofac Surg 2013*



**Fig. 4.** Panoramic view after the removal of the broken needle.

*Jin-Ha Kim et al: Removal of a broken needle using three-dimensional computed tomography: a case report. J Korean Assoc Oral Maxillofac Surg 2013*

into the hilt to deposit the local anesthetic in the appropriate position. All of the above can contribute to needle breakage; therefore, the use of a 30-gauge needle should be avoided when administering inferior alveolar nerve block<sup>1</sup>.

In case needle breakage does occur, every effort should be made to retrieve the needle immediately--if the tip is visible--using fine hemostats. In the unfortunate event of the tip not being visible, the patient should be informed, and arrangements should be made for appropriate referral to the Department of Oral and Maxillofacial Surgery. Prompt retrieval is strongly recommended to minimize symptoms of pain, dysphagia and trismus and to prevent the migration of the needle and potential damage to vital structures<sup>6</sup>. Note, however, that the retrieval of the needle in itself can lead to neurological and tissue damages during removal, and some suggest considering removal only if the patient develops symptoms<sup>6</sup>. As reported by Ethunandan et al.<sup>10</sup>, the subject patient had trismus and pain upon leaving the clinic; thus, the initial decision was to leave the needle in situ, but it was subsequently removed six months later after the local symptoms persisted. A reason for the prompt removal of the needle is its possible migration and the development of severe complications; another factor is psychological. Therefore, removal of the fragment as soon as possible is recommended<sup>10</sup>.

Various methods have been described to find a broken needle in the pterygomandibular space<sup>10</sup>. Plain radiographs are useful in confirming the broken needle and approximate position during the initial examination<sup>10</sup>. Nonetheless, they are unable to provide the accurate position of the broken needle and its relationship to adjacent structures<sup>10</sup>. 3D CT images can give us more precise information of the broken needle. A site for incisions and exploration can be determined from the available information on the CT scan. It accurately shows the position of the needle with recognizable anatomical landmark, especially with 3D reformatting<sup>10</sup>.

Most reports have suggested the use of vertical mucosal incision--often on the medial aspect of the mandible in the area penetrated by the needle--followed by blunt supra-periosteal

dissection to identify the needle<sup>5-9</sup>. This case located the broken needle in the peri-condylar area; we employed a vertical incision along the anterior border of the mandible, extending inferiorly to the external oblique ridge followed by subperiosteal dissection along the medial and lateral aspects of the ramus of the mandible. The initial subperiosteal dissection may help identify bony landmarks (such as lingula), which can be used as reference point during exploration; it also provide greater protection to the inferior alveolar and lingual nerves. Focused extra periosteal blunt dissection based on CT scan information can be subsequently performed without inadvertently damaging these nerves.

Therefore, in case of a broken dental needle during inferior alveolar nerve block anesthesia, prompt removal of the fragment with CT and guide-suture needle under local anesthesia make for an effective, successful method. This also prevents medicolegal issues from arising.

## References

1. Säkkinen J, Huppunen M, Suuronen R. Complications following local anaesthesia. *Nor Tannlegetoren Tid* 2005;115:48-52.
2. Augello M, von Jackowski J, Grätz KW, Jacobsen C. Needle breakage during local anesthesia in the oral cavity--a retrospective of the last 50 years with guidelines for treatment and prevention. *Clin Oral Investig* 2011;15:3-8.
3. Amies AB. Broken needles. *Aust J Dent* 1951;55:403-6.
4. Fraser-Moodie W. Location and localisation of metal in the tissues. *Br J Oral Surg* 1966;4:99-105.
5. Zeltser R, Cohen C, Casap N. The implications of a broken needle in the pterygomandibular space: clinical guidelines for prevention and retrieval. *Pediatr Dent* 2002;24:153-6.
6. Faura-Solé M, Sánchez-Garcés MA, Berini-Aytes L, Gay-Escoda C. Broken anesthetic injection needles: report of 5 cases. *Quintessence Int* 1999;30:461-5.
7. Bhatia S, Bounds G. A broken needle in the pterygomandibular space: report of a case and review of the literature. *Dent Update* 1998;25:35-7.
8. Marks RB, Carlton DM, McDonald S. Management of a broken needle in the pterygomandibular space: report of case. *J Am Dent Assoc* 1984;109:263-4.
9. Bedrock RD, Skigen A, Dolwick MF. Retrieval of a broken needle in the pterygomandibular space. *J Am Dent Assoc* 1999;130:685-7.
10. Ethunandan M, Tran AL, Anand R, Bowden J, Seal MT, Brennan PA. Needle breakage following inferior alveolar nerve block: implications and management. *Br Dent J* 2007;202:395-7.