

The treatment of malocclusion after open reduction of maxillofacial fracture: a report of three cases

Sung-Suk Lee, Su-Gwan Kim, Seong-Yong Moon, Ji-Su Oh, Jae-Seek You

Department of Oral and Maxillofacial Surgery, School of Dentistry, Chosun University, Gwangju, Korea

Abstract (J Korean Assoc Oral Maxillofac Surg 2014;40:91-95)

The posttraumatic complications of jaw fractures related to jaw function and facial deformity include nonunion, malunion, malocclusion, temporomandibular joint dysfunction and facial asymmetry. This report presents cases referred to our department for revision of malunion and malocclusion following inadequate reduction of jaw fractures. Three patients with posttraumatic malocclusions caused by malunion were treated with a LeFort I osteotomy in one case and re-fracture in two cases. All of the patients exhibited stable results without further complications (e.g., malunion or malocclusion). Accurate preoperative diagnosis and proper anatomical reduction of the fracture segments are essential to preventing post-surgical malunion and malocclusion.

Key words: Fractures, Malunion, Malocclusion

[paper submitted 2013. 12. 31 / revised 2014. 3. 17 / accepted 2014. 3. 31]

I. Introduction

The mandibular bone sustains fracture most frequently because it is located in the center of the face at a location prone to external injury¹. The goals of treatment are to ensure rapid healing through accurate reduction and fixation and to minimize disability and complications. Many techniques have been introduced over the years, including maxillomandibular fixation, which uses intraosseous wire, lag screw fixation, external rigid fixation and, recently, internal rigid fixation, such as stable internal fixation using a metal plate². These methods may cause such complications as infection, malunion, delayed union, nonunion, hypoesthesia, malocclusion and facial deformity³. Inappropriate union is attributable to the mechanical environment, which entails wide gap between segments and movement of segments, and a poor biological environ-

ment. The former condition is caused by a bone defect or displacement and overlap of the bone segment, whereas the latter condition is caused by decreased vascular supply, a nutritional disorder, inflammation and inhibiting factors of bone healing⁴.

It is necessary to consider the location and complexity of the fracture, the existence of teeth on the fracture line and infection presenting in an open fracture. The patient's poor oral hygiene may cause infection, which would require additional surgery⁵. Additional surgery causes the patient increased pain, recovery time and costs for hospitalization, as well as interruption of daily life. In treating mandibular fractures, it is necessary to make the utmost effort to minimize complications⁶.

The purpose of this study was to introduce cases in which revision surgery was necessitated by malunion occurring after reduction of a mandibular fracture and to discuss relevant complications.

II. Cases Report

We followed the Helsinki Declaration throughout this study. We obtained approval from the Chosun University Dental Hospital Clinical Trial Center Institutional Review

Su-Gwan Kim

*Department of Oral and Maxillofacial Surgery, School of Dentistry, Chosun University, 309, Pilmun-daero, Dong-gu, Gwangju 501-759, Korea
TEL: +82-62-220-3815 FAX: +82-62-228-7316
E-mail: sgckim@chosun.ac.kr*

©This is an open-access article distributed under the terms of the Creative Commons Attribution Non-Commercial License (<http://creativecommons.org/licenses/by-nc/3.0/>), which permits unrestricted non-commercial use, distribution, and reproduction in any medium, provided the original work is properly cited.

Copyright © 2014 The Korean Association of Oral and Maxillofacial Surgeons. All rights reserved.

Board (CDMDIRB-1325-146).

1. Case 1

A 50-year-old man was admitted to the emergency room of this hospital after he fell at his worksite from a height of 2 m and sustained an injury to the maxillofacial area. Based on the clinical and radiological examination results, the patient was diagnosed with fractures in both lateral orbital walls and in the left lower and interior orbital walls, a zygomatico-maxillary complex fracture, a right temporal bone fracture and a mandibular symphysis fracture, as shown in the initial picture.(Fig. 1) In Department of Otolaryngology, open reduction was performed for internal fixation using a metal plate in the area of the left orbit and at the site of the mandibular symphysis; in this surgical approach, the temporal bone was used to preserve the right facial nerve. Two months later, the patient visited this hospital with the primary complaint of malocclusion and was transferred to our department. During examination, spacing caused by malunion was found between the central incisors on both sides of the mandibular symphysis and malocclusion was found on both sides.(Figs. 2, 3) Revision surgery to adjust the occlusion was performed under general anesthesia. The existing metal plate was removed, and a chisel was used to re-fracture the mandibular symphysis site. After the occlusion was adjusted to the original position as much as possible, a miniplate was used for the re-fixation, and an arch bar was used to perform the maxillomandibular fixation.(Fig. 4) After the surgery was

completed, the patient reported good occlusion on both sides. The patient had hypoesthesia of the lower lip and discomfort during mouth opening.

2. Case 2

A 22-year-old man was diagnosed with a nasoethmoidal complex fracture, a LeFort II fracture and a subcondylar fracture of the right mandible that were sustained in a motorcycle accident. The patient was hospitalized in the plastic surgery department and open reduction was performed on the nasoethmoidal complex and maxilla using an absorbable plate. No treatment was performed for the subcondylar fracture. Five weeks later, the patient visited this department with the primary complaint of malocclusion and was diagnosed with malunion of the maxilla.(Fig. 5. A) The absorbable

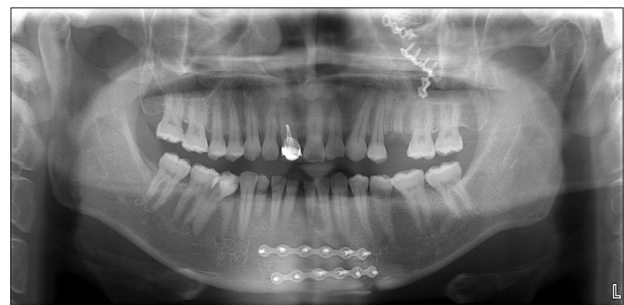

Fig. 2. Panoramic view two months after surgery in Department of Otolaryngology.
Sung-Suk Lee et al: The treatment of malocclusion after open reduction of maxillofacial fracture: a report of three cases. J Korean Assoc Oral Maxillofac Surg 2014

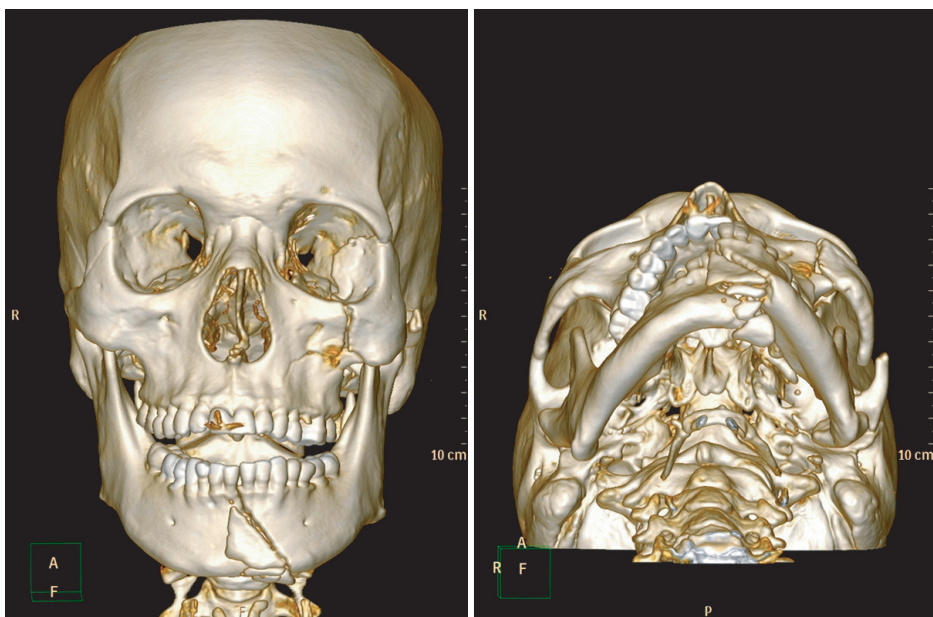


Fig. 1. Three-dimensional computed tomography of the initial examination.
Sung-Suk Lee et al: The treatment of malocclusion after open reduction of maxillofacial fracture: a report of three cases. J Korean Assoc Oral Maxillofac Surg 2014

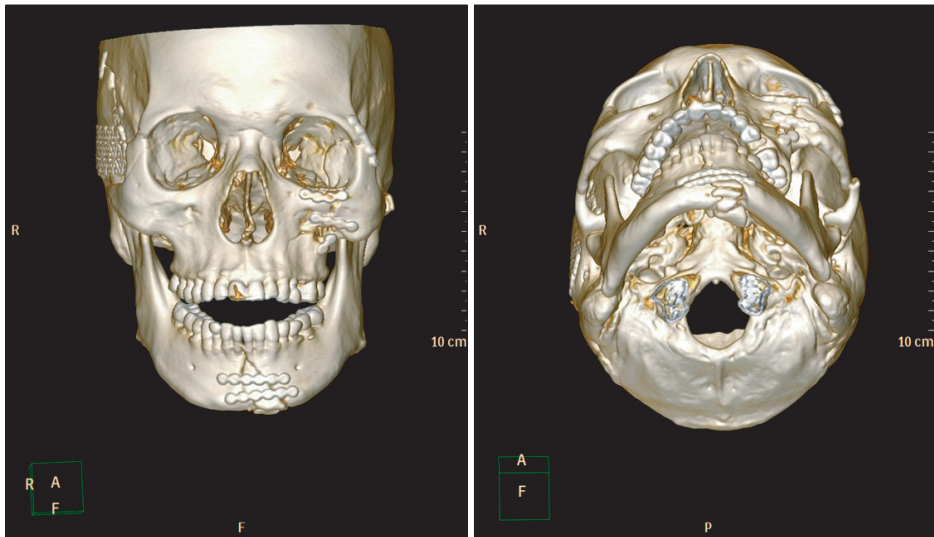


Fig. 3. Computed tomography two months after surgery in Department of Otolaryngology.
Sung-Suk Lee et al: The treatment of malocclusion after open reduction of maxillofacial fracture: a report of three cases. J Korean Assoc Oral Maxillofac Surg 2014

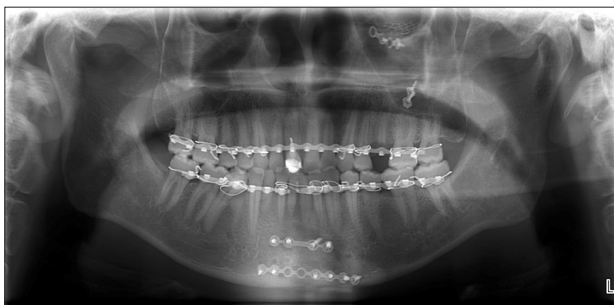

Fig. 4. Panoramic view after revision surgery.
Sung-Suk Lee et al: The treatment of malocclusion after open reduction of maxillofacial fracture: a report of three cases. J Korean Assoc Oral Maxillofac Surg 2014

plates were removed under general anesthesia, and a LeFort I osteotomy was performed for maxillomandibular fixation to ensure proper occlusion and a miniplate was used for re-fixation. The patient healed without particular discomfort or complications.(Fig. 5. B)

3. Case 3

The third patient was a 38-year-old man who visited this hospital after a traffic accident 10 months previously. The examination showed a fracture on the left parasymphysis and a subcondylar fracture.(Fig. 6) After re-fracture of the subcondylar and parasymphysis sites under general anesthesia, a miniplate was used for fixation with a block bone graft.(Fig. 7. A) The patient was lethargic from the traffic accident, and it was therefore difficult to perform a follow-up examination. The patient visited the hospital for revision surgery six months later. The examination results demonstrated malocclusion attributable to malunion. Re-fracture was performed

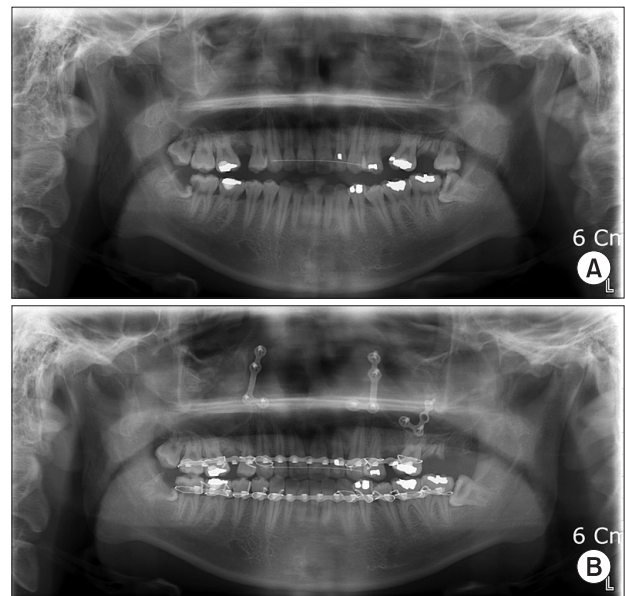


Fig. 5. A. Panoramic view after surgery in Department of Plastic Surgery. B. Panoramic view after revision surgery.
Sung-Suk Lee et al: The treatment of malocclusion after open reduction of maxillofacial fracture: a report of three cases. J Korean Assoc Oral Maxillofac Surg 2014

on the subcondyle and parasymphysis before a miniplate was used for fixation.(Fig. 7. B)

III. Discussion

The goal of treatment for mandibular fracture is accurate reduction of the bone segments to recover the pre-traumatic occlusion and to restore normal masticatory function, pronunciation, shape and sensation⁷. It is necessary to perform rigid fixation for the formation of the callus because integration occurs only under mechanically stable conditions, and

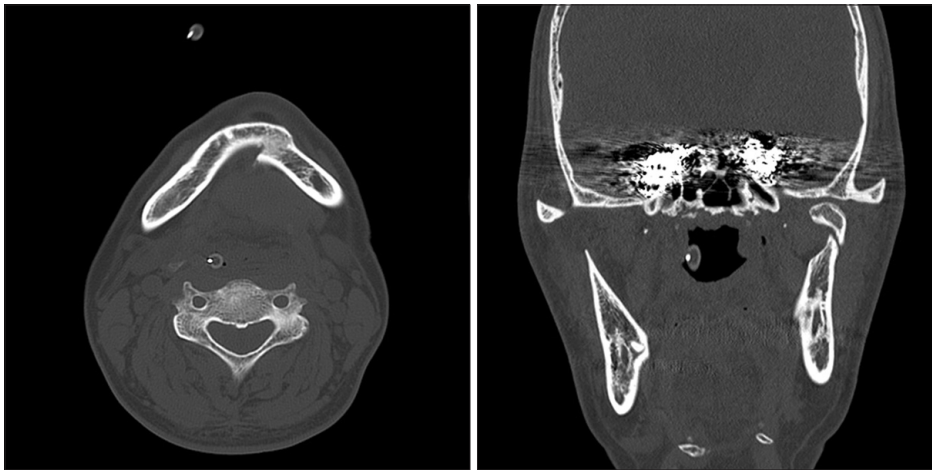


Fig. 6. Computed tomography at the hospital upon initial examination.

Sung-Suk Lee et al: The treatment of malocclusion after open reduction of maxillofacial fracture: a report of three cases. J Korean Assoc Oral Maxillofac Surg 2014

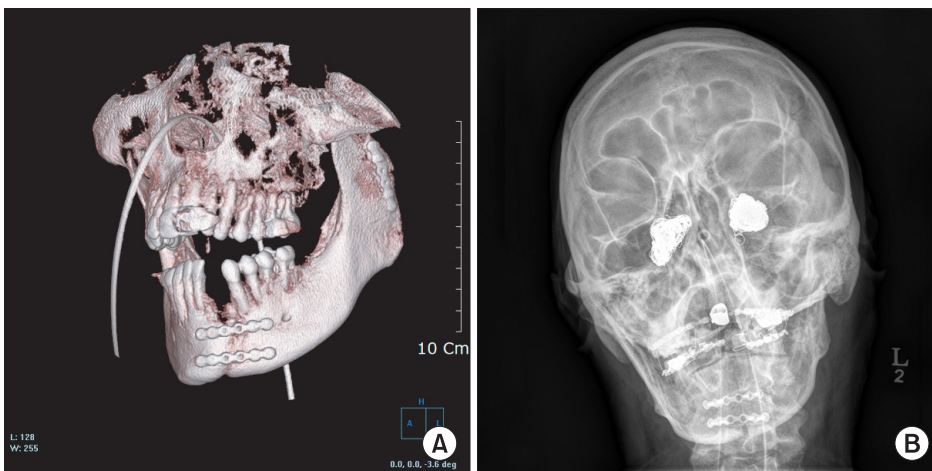


Fig. 7. A. Three-dimensional computed tomography after the first surgery. B. Skull posteroanterior view after the revision surgery.

Sung-Suk Lee et al: The treatment of malocclusion after open reduction of maxillofacial fracture: a report of three cases. J Korean Assoc Oral Maxillofac Surg 2014

mechanical stability is also indispensable to vascularization of the primary callus. Mechanical stability causes internal growth of the capillary process and removes fibrocartilage, which lead to osteon formation. Distortion and stress prevent such processes⁸.

Many techniques have been studied and developed to treat mandibular fracture, and it is necessary to consider potential complications for all techniques. Alpert et al.⁹ introduced four types of complications that were classified as follows: 1) complications that appear after proper treatment is conducted; 2) complications that are attributable to inappropriate treatment; 3) complications that are due to failure of surgical treatment; and 4) complications that occur because no treatment is conducted.

Mathog and Boies¹⁰ reported that the most significant factors causing malunion in mandibular fracture included inappropriate movement, incomplete reduction, infection, poor blood circulation, and metabolic change. The integration of normal bone typically occurs in 4-8 weeks, depending on the age of the patient, and malunion occurs if bone integration

does not take place in that time¹¹. Malunion occurs due to inappropriate reduction, agitation of the bone segment, non-compliance on the part of patient or improper internal fixation¹².

The mandible is prone to complications that occur after jaw fracture reduction due to the following reasons. The mandible is the only bone in the facial region that moves and it has less bone support than the facial bones; therefore, a fracture of the mandible generally results in greater degrees of instability. Because of the muscle attached to the mandible, mandible displacement may occur even after reduction and fixation. The mandible is located in the lower part of the oral cavity, which increases the possibility of infection. The mandible has lower blood circulation than the maxilla, which contributes to the occurrence of inappropriate integration⁴.

Physician misdiagnosis is another factor that can cause complications after mandible surgery and is attributable to inexperience or inadequate radiological examination equipment. Mandibular fracture is accompanied by edema and hemorrhage, which cause difficulty in precise diagnosis. The

occurrence of multiple fractures could result in a physician erroneously overlooking some bone fracture sites⁴.

For surgical management of such complications, a thorough and corrective examination prior to surgery is necessary. The pre-traumatic occlusion must be verified, and an osteotomy to perform internal fixation is required. It might be necessary to perform a new osteotomy on sites other than the malunion site for the recovery of occlusion⁷.

In this study, malunion after mandibular reduction led to malocclusion, and revision surgery provided satisfactory results. A precise pre-operative examination and appropriate surgical procedure followed by proper post-operative management are necessary to prevent post-surgical complications of jaw fracture fixation. Additional studies are warranted to investigate the surgical and non-surgical management of such complications.

Conflict of Interest

No potential conflict of interest relevant to this article was reported.

References

1. Killey HC, Banks P. Killey's fractures of the mandible. 3rd ed. Bristol: Wright-PSG; 1983.
2. Moraes RB, Landes CA, Luz JG. Fixation of mandibular fractures with plates or miniplates: prospective study. *Minerva Stomatol* 2010;59:159-66.
3. Mathog RH, Toma V, Clayman L, Wolf S. Nonunion of the mandible: an analysis of contributing factors. *J Oral Maxillofac Surg* 2000;58:746-52.
4. Li Z, Zhang W, Li ZB, Li JR. Abnormal union of mandibular fractures: a review of 84 cases. *J Oral Maxillofac Surg* 2006;64:1225-31.
5. Taher AA. Osteomyelitis of the mandible in Tehran, Iran. Analysis of 88 cases. *Oral Surg Oral Med Oral Pathol* 1993;76:28-31.
6. Assael LA. Evaluation of rigid internal fixation of mandible fractures performed in the teaching laboratory. *J Oral Maxillofac Surg* 1993;51:1315-9.
7. Punjabi AP, Thaller SR. Late complications of mandibular fractures. *Oper Tech Plast Reconstr Surg* 1998;5:266-74.
8. Schwimmer A. Mandibular pseudoarthrosis and non-unions. In: Greenberg AM, ed. *Craniomaxillofacial fractures: principles of internal fixation using the AO/ASIF technique*. New York: Springer-Verlag; 1993:77-84.
9. Alpert B, Engelstad M, Kushner GM. Invited review: small versus large plate fixation of mandibular fractures. *J Craniomaxillofac Trauma* 1999;5:33-9.
10. Mathog RH, Boies LR Jr. Nonunion of the mandible. *Laryngoscope* 1976;86:908-20.
11. Mathog RH. Nonunion of the mandible. *Otolaryngol Clin North Am* 1983;16:533-47.
12. Ellis E 3rd. Complications of rigid internal fixation for mandibular fractures. *J Craniomaxillofac Trauma* 1996;2:32-9.