

Comparative analysis of the amount of postoperative drainage after intraoral vertical ramus osteotomy and sagittal split ramus osteotomy

Hyunyoung Kim, Seung-Won Chung, Hwi-Dong Jung, Hyung-Sik Park, Young-Soo Jung

Department of Oral and Maxillofacial Surgery, Oral Science Research Institute, College of Dentistry, Yonsei University, Seoul, Korea

Abstract (J Korean Assoc Oral Maxillofac Surg 2014;40:169-172)

Objectives: The purpose of this retrospective study was to compare the amount of postoperative drainage via closed suction drainage system after intraoral vertical ramus osteotomy (IVRO) and sagittal split ramus osteotomy (SSRO).

Materials and Methods: We planned a retrospective cohort study of 40 patients selected from a larger group who underwent orthognathic surgery from 2007 to 2013. Mean age (range) was 23.95 (16 to 35) years. Patients who underwent bilateral IVRO or SSRO were categorized into group I or group II, respectively, and each group consisted of 20 patients. Closed suction drainage system was inserted in mandibular osteotomy sites to decrease swelling and dead space, and records of drainage amount were collected. The data were compared and analyzed with independent t-test.

Results: The closed suction drainage system was removed at 32 hours postoperatively, and the amount of drainage was recorded every 8 hours. In group I, the mean amount of drainage was 79.42 mL in total, with 31.20 mL, 19.90 mL, 13.90 mL, 9.47 mL, and 4.95 mL measured at 0, 8, 16, 24, and 32 hours postoperatively, respectively. In group II, the mean total amount of drainage was 90.11 mL, with 30.25 mL, 25.75 mL, 19.70 mL, 8.50 mL, and 5.91 mL measured at 0, 8, 16, 24, and 32 hours postoperatively, respectively. Total amount of drainage from group I was less than group II, but there was no statistically significant difference between the two groups ($P=0.338$). There was a significant difference in drainage between group I and group II only at 16 hours postoperatively ($P=0.029$).

Conclusion: IVRO and SSRO have different osteotomy design and different extent of medullary exposure; however, our results reveal that there is no remarkable difference in postoperative drainage of blood and exudate.

Key words: Sagittal split ramus osteotomy, Intraoral vertical ramus osteotomy, Postoperative complications, Closed suction drainage system, Drainage
[paper submitted 2014. 5. 15 / revised 2014. 6. 16 / accepted 2014. 6. 18]

I. Introduction

Operations cause tissue injury, and exudate may flow from sites of injury. Wound exudate is composed of fluid and cells including neutrophils and macrophages. In the inflammatory phase, wound exudate is part of the normal healing process¹; however, excessive postoperative exudate can increase pain, swelling, seroma, and risk of infection². Furthermore, excessive exudate after orthognathic surgery may be dangerous due to difficult airway management³. Cases of fatality after

such airway obstruction have been reported⁴.

Intraoral vertical ramus osteotomy (IVRO) and sagittal split ramus osteotomy (SSRO) are representative methods of mandibular ramus osteotomy. The prominent difference between SSRO and IVRO is the presence of inter-segmental fixation⁵. Inter-segmental fixation is required after SSRO, whereas bone segments are free from each other after IVRO. Also, the extent of subperiosteal dissection and the design of osteotomy are different. Given the above differences, the amount of postoperative drainage may also be different.

The purpose of this study was to measure the amount of postoperative drainage after IVRO and SSRO by inserting a closed suction drainage system into the bilateral mandibular osteotomy sites.

II. Materials and Methods

This study followed the Declaration of Helsinki on medical protocol and ethics, and the regional Ethical Review Board of

Young-Soo Jung

Department of Oral and Maxillofacial Surgery, Oral Science Research Institute, College of Dentistry, Yonsei University, 50 Yonsei-ro, Seodaemun-gu, Seoul 120-752, Korea

TEL: +82-2-2228-3139 FAX: +82-2-2227-8022

E-mail: ysjoms@yuhs.ac

© This is an open-access article distributed under the terms of the Creative Commons Attribution Non-Commercial License (<http://creativecommons.org/licenses/by-nc/3.0/>), which permits unrestricted non-commercial use, distribution, and reproduction in any medium, provided the original work is properly cited.

Copyright © 2014 The Korean Association of Oral and Maxillofacial Surgeons. All rights reserved.

Yonsei Dental Hospital Institutional Review Board approved the study (IRB No. 2-2013-0005).

This retrospective cohort study includes subjects who underwent IVRO or SSRO orthognathic surgery for correction of dentofacial deformities by two expert surgeons at the Department of Oral and Maxillofacial Surgery, Yonsei Dental Hospital between 2007 and 2013. The exclusion criteria were existing medical, physical, and mental conditions that would increase bleeding tendency; correction of mandibular deformity by another technique; abnormal preoperative prothrombin time, partial thromboplastin time, bleeding time, or platelet count; and other hematologic abnormalities that could affect the result.

Forty patients resulted from this selection process and were categorized into 2 groups. The 20 patients treated with IVRO were placed in group I, and the 20 patients treated with SSRO were placed in group II. Thirty-six patients underwent bimaxillary orthognathic surgery. One patient in group I and three patients in group II underwent only mandibular operations. Table 1 shows baseline characteristics of the two groups. Group I was composed of 11 males and 9 females. Group II was composed of 9 males and 11 females. Mean age and standard deviation (SD) of the 40 patients were 23.95 years and 4.78 years. Mean age (SD) was 22.1 (2.94) years in group I and 25.8 (5.57) years in group II. Two expert surgeons performed all operations, and there was no difference in osteotomy design of IVRO and splitting technique and osteosynthesis in SSRO.

A closed suction drainage system was inserted at the operation site of the mandibular ramus following mandibular osteotomy and repositioning. The drainage tubes were connected to one bulb with negative pressure. The patient was moved to a general ward after recovery from general anesthesia.

Table 1. Baseline characteristics of groups I and II

Characteristic	Group I	Group II
Method	IVRO	SSRO
Patients (n)	20	20
Age (yr)	22.1	25.8
Sex (n)		
Male	11	9
Female	9	11
Only 2-jaw (n)	19	16
1-Jaw (n)	1	3
2-Jaw with genioplasty (n)	0	1

(IVRO: intraoral vertical ramus osteotomy, SSRO: sagittal split ramus osteotomy)

Hyunyoung Kim et al: Comparative analysis of the amount of postoperative drainage after intraoral vertical ramus osteotomy and sagittal split ramus osteotomy. J Korean Assoc Oral Maxillofac Surg 2014

The amount of postoperative drainage was checked every 8 hours for 32 hours total. Then the closed suction drainage system was removed. The amount of postoperative drainage was reported into the electronic medical record system. Data was collected and analyzed with independent t-test using the PASW Statistics 18.0 software (IBM Co., Armonk, NY, USA).

III. Results

Results were described as the amount of postoperative drainage from a drain bulb per person every 8 hours postoperatively. (Table 2, Fig. 1) Immediately after the operation, the mean (SD) amount of drainage was 31.20 (12.31) mL and 30.25 (20.72) mL in group I and group II, respectively; however, the difference was not statistically significant ($P=0.861$). At 8 hours postoperatively, the mean (SD) amount of drainage was 19.90 (10.94) mL and 25.75 (18.08) mL in group I and group II, respectively; however, the difference was not statistically significant ($P=0.225$). At 16 hours postoperative-

Table 2. Amount of drainage from a closed suction drainage system every 8 hours after surgery (mL)

	Immediate	0-8 h	8-16 h	16-24 h	24-32 h	Total
Group I	31.20	19.90	13.90	9.47	4.95	79.42
Group II	30.25	25.75	19.70	8.50	5.91	90.11

Group I: with intraoral vertical ramus osteotomy, Group II: with sagittal split ramus osteotomy.

Values are presented as mean.

Hyunyoung Kim et al: Comparative analysis of the amount of postoperative drainage after intraoral vertical ramus osteotomy and sagittal split ramus osteotomy. J Korean Assoc Oral Maxillofac Surg 2014

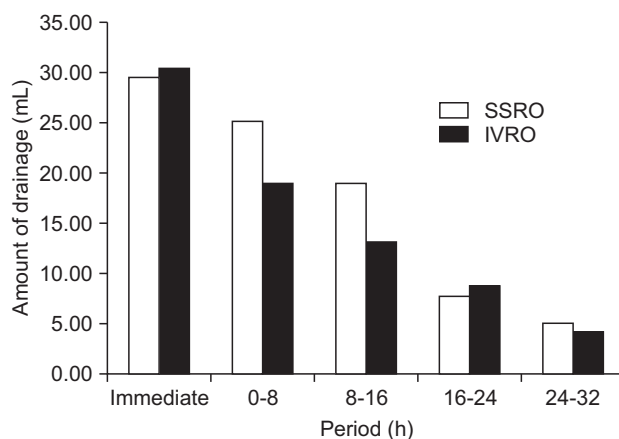


Fig. 1. Amount of drainage from a bulb after orthognathic surgery. (SSRO: sagittal split ramus osteotomy, IVRO: intraoral vertical ramus osteotomy)

Hyunyoung Kim et al: Comparative analysis of the amount of postoperative drainage after intraoral vertical ramus osteotomy and sagittal split ramus osteotomy. J Korean Assoc Oral Maxillofac Surg 2014

Table 3. Statistical analysis to compare group I to group II

Period (h)	Group	Volume (mL)	σ	P-value
Immediate	I	31.20	12.31	0.861
	II	30.25	20.72	
0-8	I	19.90	10.94	0.225
	II	25.75	18.08	
8-16	I	13.90	6.37	0.029
	II	19.70	9.38	
16-24	I	9.47	5.2	0.658
	II	8.50	8.29	
24-32	I	4.95	4.57	0.601
	II	5.91	6.67	
Total	I	79.42	23.86	0.338
	II	90.11	42.85	

Group I: with intraoral vertical ramus osteotomy, Group II: with sagittal split ramus osteotomy.

Statistical analysis by Student's t-test.

Hyunyoung Kim et al: Comparative analysis of the amount of postoperative drainage after intraoral vertical ramus osteotomy and sagittal split ramus osteotomy. *J Korean Assoc Oral Maxillofac Surg* 2014

ly, the mean (SD) amount of drainage was 13.90 (6.37) mL and 19.70 (9.38) mL in group I and group II, respectively, and the difference was statistically significant ($P=0.029$). At 24 hours postoperatively, the mean (SD) amount of drainage was 9.47 (5.2) mL and 8.50 (8.29) mL in group I and group II, respectively; however, the difference was not statistically significant ($P=0.658$). At 32 hours postoperatively, the mean (SD) amount of drainage was 4.95 (4.57) mL and 5.91 (6.67) mL in group I and group II, respectively; however, the difference was not statistically significant ($P=0.601$). The total amount (SD) of drainage from the closed suction drainage system was 79.42 (23.86) mL and 90.11 (42.85) mL in group I and group II, respectively. There was no statistically significant difference between the two groups ($P=0.338$). (Table 3)

Postoperatively, volume usually decreased every 8 hours in both groups. At 32 hours postoperatively, the amount of drainage was below 10 mL in both groups.

IV. Discussion

The healing of fractured bone occurs in four phases. The first phase is the inflammatory phase, which includes formation of hematoma, extravasation, release of cytokines, and aggregation of immune cells. These are causes of postoperative swelling and exudate⁶. The second phase of fractured bone healing is formation of a soft callus characterized by cartilage around a fractured bone to connect a bony gap. Then the soft callus becomes a hard callus in the third phase, and the final phase of bone healing is the remodeling phase. In the remodeling phase, old bone is replaced with new bone. Immediately

after an orthognathic surgery, these same four phases of bone healing begin with exudate and swelling in the inflammatory phase.

We inserted a closed suction drainage system into bilateral mandibular osteotomy sites to decrease postoperative swelling, seroma, and incidence of infection. Some studies have demonstrated that a closed suction drainage system is not effective. Clifton et al.⁷ reported a systematic review with a closed suction drainage system after operation for hip fracture and demonstrated that there was no significant difference in the occurrence of complications between a drained wound and an undrained wound. Though there is some debate about its necessity, closed suction drainage is considered a useful device for decreasing postoperative complications in various fields. He et al.⁸ performed a systematic review of randomized controlled trials studying insertion of a drain after axillary lymph node dissection for breast cancer. In comparison with undrained wounds, drained wounds showed significantly lower incidence of seroma formation without infection. Therefore, we inserted closed suction drainage systems into osteotomy sites, expecting a decrease in postoperative complications.

Ueki et al.⁹ showed that the amount of intraoperative bleeding was lower after IVRO than after SSRO. The study demonstrated that blood loss was 216.6 mL after SSRO and 125.5 mL after IVRO. Yet, there is no comparative study examining the amount of postoperative drainage from osteotomy areas after IVRO and SSRO. Therefore, we measured the amount of postoperative drainage after each type of operation by inserting a closed suction drainage system into mandibular osteotomy sites after orthognathic surgery. Some clinicians assume that the amount of intraoperative bleeding and postoperative exudate from osteotomy areas is larger after IVRO than after SSRO because bone segments after IVRO are not fixed by screws. Bone segments after SSRO are fixed and faced. We hypothesized that the amount of postoperative drainage might be larger after SSRO than IVRO because sagittal split osteotomy on ramus causes more extensive medullary exposure than vertical osteotomy on ramus.

These data allowed comparison of drainage output from the bulb of a closed suction drainage system between group I and group II. Our findings may help determine which method can reduce postoperative swelling, seroma formation, and risk of infection. Although patients in group I showed less postoperative drainage than group II, these data did not show any statistically significant difference between the groups ($P=0.338$). Thus, surgeons do not need to consider postopera-

tive drainage when determining which method is preferred for mandibular surgery.

These data further suggest that the closed suction drains may be removed 32 hours after orthognathic surgery, because the amount of postoperative drainage during the last 8 hours was below 10 mL in both groups. At that time, the risk of swelling, hematoma formation, and probability of infection would decrease.

There are some possible confounding factors in this study. First, the two surgeons usually performed SSRO only for mandibular advancement, whereas they did IVRO for mandibular setback. Mandibular segments had less exposed bone marrow after mandibular setback. Consequently, the differing surgical plan for each method may have affected our results. Second, cold pack application can decrease the amount of drainage¹⁰. Also, hypotensive anesthesia or injection of tranexamic acid can decrease hemorrhage¹¹⁻¹³. Use of steroid decreases inflammation and swelling^{14,15}. The above variables may influence the amount of postoperative drainage from a closed suction drainage system. Further study is needed to confirm whether the above are confounding factors. There may also be some difference in the ability of our two surgeons, though they performed the same osteotomy technique for IVRO and SSRO. We thought that there would be little variability between the two surgeons. Thus influence by the surgeon was not considered a confounding factor.

V. Conclusion

IVRO and SSRO have different osteotomy design and different exposure of medullary bone; therefore, one might think that the amount of postoperative drainage from a closed suction drainage system is different from each method. Our results revealed that there was no statistically significant difference in postoperative drainage of blood and exudate from bilateral mandibular osteotomy areas after IVRO and SSRO.

Conflict of Interest

No potential conflict of interest relevant to this article was reported.

References

1. Ovington LG. Dealing with drainage: the what, why, and how of wound exudate. *Home Healthc Nurse* 2002;20:368-74.
2. Jones J, Barraud J. An evaluation of KerraMax Care in the management of moderate to heavily exuding wounds. *Br J Community Nurs* 2014;(Suppl):S48, S50-3.
3. Politis C, Kunz S, Schepers S, Vrielinck L, Lambrechts I. Obstructive airway compromise in the early postoperative period after orthognathic surgery. *J Craniofac Surg* 2012;23:1717-22.
4. Hwang K, Kim HJ, Lee HS. Airway obstruction after orthognathic surgery. *J Craniofac Surg* 2013;24:1857-8.
5. Yoshioka I, Khanal A, Tominaga K, Horie A, Furuta N, Fukuda J. Vertical ramus versus sagittal split osteotomies: comparison of stability after mandibular setback. *J Oral Maxillofac Surg* 2008;66:1138-44.
6. Abou-Khalil R, Colnot C. Cellular and molecular bases of skeletal regeneration: what can we learn from genetic mouse models? *Bone* 2014;64:211-21.
7. Clifton R, Haleem S, McKee A, Parker MJ. Closed suction surgical wound drainage after hip fracture surgery: a systematic review and meta-analysis of randomised controlled trials. *Int Orthop* 2008;32:723-7.
8. He XD, Guo ZH, Tian JH, Yang KH, Xie XD. Whether drainage should be used after surgery for breast cancer? A systematic review of randomized controlled trials. *Med Oncol* 2011;28(Suppl 1):S22-30.
9. Ueki K, Marukawa K, Shimada M, Nakagawa K, Yamamoto E. The assessment of blood loss in orthognathic surgery for prognathia. *J Oral Maxillofac Surg* 2005;63:350-4.
10. Morsi E. Continuous-flow cold therapy after total knee arthroplasty. *J Arthroplasty* 2002;17:718-22.
11. Song G, Yang P, Hu J, Zhu S, Li Y, Wang Q. The effect of tranexamic acid on blood loss in orthognathic surgery: a meta-analysis of randomized controlled trials. *Oral Surg Oral Med Oral Pathol Oral Radiol* 2013;115:595-600.
12. Zellin G, Rasmusson L, Pålsson J, Kahnberg KE. Evaluation of hemorrhage depressors on blood loss during orthognathic surgery: a retrospective study. *J Oral Maxillofac Surg* 2004;62:662-6.
13. Choi WS, Irwin MG, Samman N. The effect of tranexamic acid on blood loss during orthognathic surgery: a randomized controlled trial. *J Oral Maxillofac Surg* 2009;67:125-33.
14. Chegini S, Dhariwal DK. Review of evidence for the use of steroids in orthognathic surgery. *Br J Oral Maxillofac Surg* 2012;50:97-101.
15. Weber CR, Griffin JM. Evaluation of dexamethasone for reducing postoperative edema and inflammatory response after orthognathic surgery. *J Oral Maxillofac Surg* 1994;52:35-9.