

Screening for variations in anterior digastric musculature prior to correction of post-traumatic anterior open bite by injection of botulinum toxin type A: a technical note

Matthew J. Zdilla

Department of Natural Sciences and Mathematics, West Liberty University, West Liberty, WV, USA

Abstract (J Korean Assoc Oral Maxillofac Surg 2015;41:165-167)

It has recently been reported that long-standing post-traumatic open bite can be successfully corrected with botulinum toxin type A (BTX-A) injection into the anterior belly of the digastric muscle (ABDM). The report documented an individual with bilaterally symmetrical and otherwise unremarkable anterior digastric musculature. However, the existence of variant anterior digastric musculature is common and may complicate the management of anterior open bite with BTX-A injection. Screening for variant ABDM can be accomplished via ultrasound, computed tomography, and magnetic resonance imaging. Screening for variant ABDM should be performed prior to BTX-A injection in order to account for musculature that may exert undesired forces, such as inferolateral deviation, on the anterior mandible in patients with anterior open bite.

Key words: Nerve block, Malocclusion, Mandibular injuries, Orthognathic surgery, Regional anatomy

[paper submitted 2015. 2. 16 / revised 2015. 3. 23 / accepted 2015. 3. 25]

I. Introduction

Recently, Seok et al.¹ described a successful correction of post-traumatic anterior open bite via injection of botulinum toxin type A (BTX-A) into the anterior belly of the digastric muscle (ABDM) in a 20-year-old man with malocclusion and wound dehiscence in the left retromolar area. In the case of mandibular angle fractures, the digastric muscles depress the anterior fragment²; therefore, by paralyzing the musculature, Seok et al.¹ were able to mitigate the forces displacing the anterior mandible. Seok et al.¹ reported, via line drawing (Fig. 1. A), that the BTX-A injections were placed in bilaterally symmetrical anterior digastric musculature that was unremarkable with regard to anatomical variation.

ABDM is typically considered to be bilaterally symmetri-

cal; however, ABDM muscular variants have been reported to occur in as much as 69.9% of the population³. Diverse anatomical variations of the ABDM have included duplications, triplications, and quadruplications, in addition to exotic fractal and weave patterns of musculature⁴⁻⁸. Also, ABDM has been reported to cross the midline and insert contralaterally⁵. Therefore, the existence of variant ABDM should be taken into consideration when attempting to reduce fractures of the mandible. An example of a variant ABDM that may complicate BTX-A injection is shown in Fig. 1. B.

II. Technical Note

Screening for anatomical variation of anterior digastric musculature with ultrasound (US), computed tomography (CT), and/or magnetic resonance imaging (MRI) should be performed in order to adequately plan injection of BTX-A into anterior digastric musculature. Upon imaging with US, skin can be marked directly over the digastric musculature in order to identify injection sites as variant musculature is encountered. With CT and MRI, bony references, such as the mandible and hyoid, can be used to calibrate measurements corresponding to the location of the musculature, which can subsequently be used to mark injection sites on the submental skin.

Matthew J. Zdilla

*Department of Natural Sciences and Mathematics, West Liberty University,
CSC 139, PO Box 295, West Liberty, WV 26074, USA*

TEL: +1-304-336-8631 FAX: +1-304-336-8266

E-mail: mzdilla@westliberty.edu

ORCID: <http://orcid.org/0000-0002-2578-1128>

© This is an open-access article distributed under the terms of the Creative Commons Attribution Non-Commercial License (<http://creativecommons.org/licenses/by-nc/4.0/>), which permits unrestricted non-commercial use, distribution, and reproduction in any medium, provided the original work is properly cited.

Copyright © 2015 The Korean Association of Oral and Maxillofacial Surgeons. All rights reserved.

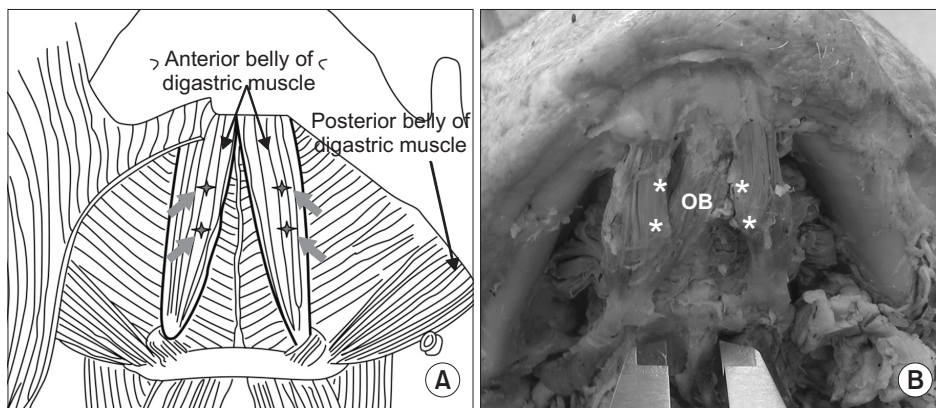


Fig. 1. Side-by-side comparison between normal and variant anterior digastric musculature with regard to botulinum toxin type A (BTX-A) injection sites. A. The line drawing from Seok et al.¹, illustrating the BTX-A injection sites in bilaterally symmetrical anterior digastric muscle bellies (starburst with arrow: injection site). Image from the article of Seok et al. (J Korean Assoc Oral Maxillofac Surg 2013;39:188-92)¹. B. A cadaveric example of an accessory oblique anterior digastric muscle belly crossing from the left digastric fossa of the mandible to the right intermediate tendon of the right digastric muscle that may complicate BTX-A injection for the correction of posttraumatic anterior open bite. Note that no injection site corresponding to those in Fig. 1. A is located on the accessory oblique digastric belly. (OB: oblique belly of the anterior digastric muscle, asterisk: injection site that correspond to those in Fig. 1. A). Image modified from the article of Zdilla et al. (J Surg Case Rep 2014. doi: 10.1093/jscr/rju131)⁷.

Matthew J. Zdilla: Screening for variations in anterior digastric musculature prior to correction of post-traumatic anterior open bite by injection of botulinum toxin type A: a technical note. J Korean Assoc Oral Maxillofac Surg 2015

III. Discussion

In light of their success in the treatment of the patient who responded favorably to BTX-A injection into the ABDM for the treatment of anterior open bite, Seok et al.¹ recommended a large-scale, case control study in which BTX-A injection is applied to selective open bite patients who do not respond to extensive rubber traction. While such a study might be prudent, it is important to recognize the diversity of ABDM musculature when planning BTX-A injection for the management of anterior open bite, in order to avoid undesired effects. Botulinum toxin injected in the neck can produce weakness of the neck flexors and dysphagia⁹; however, the majority of adverse effects due to botulinum toxin injections include bruising, edema, pain at the injection site, and flu-like symptoms⁹⁻¹¹. The more serious side effects of injection typically result from improper needle placement due to a lack of understanding of the underlying anatomy and physiology, subsequently allowing the neurotoxin to either diffuse or be inadvertently injected into adjacent musculature⁹⁻¹¹.

Screening for ABDM can be accomplished via US, CT, and MRI¹²⁻¹⁵. There are obvious differences among these imaging techniques with regard to cost, time, and invasiveness; however, to the author's knowledge, no reports have specifically compared these techniques with regard to proper identification or characterization of anterior digastric musculature.

Screening for variant ABDM should be performed prior to

BTX-A injection into the anterior digastric musculature in order to account for muscle variations that may result in undesired forces on the anterior mandible in patients with anterior open bite and to prevent undesired adverse effects of BTX-A injection.

Conflict of Interest

No potential conflict of interest relevant to this article was reported.

References

1. Seok H, Park YT, Kim SG, Park YW. Correction of post-traumatic anterior open bite by injection of botulinum toxin type A into the anterior belly of the digastric muscle: case report. J Korean Assoc Oral Maxillofac Surg 2013;39:188-92.
2. Haskell R. Applied surgical anatomy. In: Williams JL, Rowe NL, eds. Rowe and Williams' maxillofacial injuries. 2nd ed. Edinburgh: Churchill Livingstone; 1994:12-4.
3. Ozgur Z, Govsa F, Celik S, Ozgur T. An unreported anatomical finding: unusual insertions of the stylohyoid and digastric muscles. Surg Radiol Anat 2010;32:513-7.
4. Sargon MF, Onderoğlu S, Sürücü HS, Bayramoğlu A, Demiryürek DD, Öztürk H. Anatomic study of complex anomalies of the digastric muscle and review of the literature. Okajimas Folia Anat Jpn 1999;75:305-13.
5. Ozgur Z, Govsa F, Ozgur T. Bilateral quadrification of the anterior digastric muscles with variations of the median accessory digastric muscles. J Craniofac Surg 2007;18:773-5.
6. Zdilla MJ, Soloninka HJ, Lambert HW. A fractal anterior digastric: a case report with surgical implications. Int J Anat Var 2014;7:106-8.

7. Zdilla MJ, Soloninka HJ, Lambert HW. Unilateral duplication of the anterior digastric muscle belly: a case report with implications for surgeries of the submental region. *J Surg Case Rep* 2014. doi: 10.1093/jscr/rju131.
8. Harvey JA, Call Z, Peterson K, Wisco JJ. Weave pattern of accessory heads to the anterior digastric muscle. *Surg Radiol Anat* 2014. [Epub ahead of print]
9. Klein AW. Complications, adverse reactions, and insights with the use of botulinum toxin. *Dermatol Surg* 2003;29:549-56.
10. Alam M, Dover JS, Arndt KA. Pain associated with injection of botulinum A exotoxin reconstituted using isotonic sodium chloride with and without preservative: a double-blind, randomized controlled trial. *Arch Dermatol* 2002;138:510-4.
11. Walker TJ, Dayan SH. Comparison and overview of currently available neurotoxins. *J Clin Aesthet Dermatol* 2014;7:31-9.
12. Muraki AS, Mancuso AA, Harnsberger HR, Johnson LP, Meads GB. CT of the oropharynx, tongue base, and floor of the mouth: normal anatomy and range of variations, and applications in staging carcinoma. *Radiology* 1983;148:725-31.
13. Larsson SG, Lufkin RB. Anomalies of digastric muscles: CT and MR demonstration. *J Comput Assist Tomogr* 1987;11:422-5.
14. Mashkevich G, Wang J, Rawnsley J, Keller GS. The utility of ultrasound in the evaluation of submental fullness in aging necks. *Arch Facial Plast Surg* 2009;11:240-5.
15. Macrae PR, Jones RD, Myall DJ, Melzer TR, Huckabee ML. Cross-sectional area of the anterior belly of the digastric muscle: comparison of MRI and ultrasound measures. *Dysphagia* 2013;28: 375-80.