



Oral surgery under local anesthesia with dexmedetomidine sedation in a morbidly obese patient with aortic dissection

Mika Seto, Michitaka Matsuda, Kyoichi Narihira, Toshihiro Kikuta

Department of Oral and Maxillofacial Surgery, Faculty of Medicine, Fukuoka University, Fukuoka, Japan

Abstract (J Korean Assoc Oral Maxillofac Surg 2016;42:162-165)

We report a case of a morbidly obese man with an aortic aneurysm, in whom dental surgery was performed before elective cardiac surgery. His aortic aneurysm required emergency surgery. However, because of his morbid obesity, elective cardiac surgery was planned. Considering the high risk of infective endocarditis, dental surgery was required. Our patient was at a high risk of aortic rupture caused by hypertension and breathing difficulty in the supine position. Dexmedetomidine (DEX) is an anti-anxiety, sedative, and analgesic medicine that can stabilize circulatory dynamics and minimize blood pressure fluctuations. We administered intravenous DEX for sedation of the patient in Fowler's position. In conclusion, our understanding of the risk factors of DEX enabled us to perform safe invasive oral treatment.

Key words: Aortic aneurysm, Morbid obesity, Oral surgical procedures, Local anesthetics

[paper submitted 2015. 11. 18 / revised 2015. 12. 17 / accepted 2016. 1. 15]

I. Introduction

Aortic aneurysm is a serious condition characterized by the tearing of the inner layer of the aorta. It can lead to sudden death caused by cardiac failure and occasionally, aortic rupture^{1,2}. In addition, hypertension can increase the stress on the weakened aortic wall, increasing its susceptibility to tearing. Aortic aneurysms are divided into Stanford type A and Stanford type B dissections. While type B dissections generally are initially treated medically, with surgery reserved for complications, type A aortic aneurysms, which involve a tear in the aorta ascendens, generally require emergency or quasi-emergency surgical treatment².

Dexmedetomidine (DEX) is an anti-anxiety, sedative, and analgesic medication that can stabilize circulatory dynamics³ and minimize blood pressure fluctuations.

Mika Seto

Department of Oral and Maxillofacial Surgery, Faculty of Medicine, Fukuoka University, 7-45-1 Nanakuma, Jonan-ku, Fukuoka 814-0180, Japan

TEL: +81-92-801-1011 FAX: +81-92-801-1044

E-mail: myamyu43729@yahoo.co.jp

ORCID: <http://orcid.org/0000-0002-7548-7613>

©This is an open-access article distributed under the terms of the Creative Commons Attribution Non-Commercial License (<http://creativecommons.org/licenses/by-nc/4.0/>), which permits unrestricted non-commercial use, distribution, and reproduction in any medium, provided the original work is properly cited.

Copyright © 2016 The Korean Association of Oral and Maxillofacial Surgeons. All rights reserved.

We report a case of a 45-year-old morbidly obese man with an aortic aneurysm (Stanford types A and B), in whom invasive oral treatment, namely tooth extraction and cyst enucleation, for the removal of intraoral infectious sources, was successfully performed under local anesthesia with DEX sedation before elective cardiac surgery.

II. Case Report

A 45-year-old morbidly obese man was transported by ambulance to the Emergency Medical Care Center at Fukuoka University Hospital (Fukuoka, Japan) with suspected acute heart failure after developing a sudden difficulty in breathing with pink frothy sputum. According to his wife, the patient had no significant medical history other than hypertension. Detailed examination revealed an aortic aneurysm (Stanford types A and B), aortic regurgitation, aortic valve ring ectasia, ascending thoracic aorta aneurysm, hypertension, paroxysmal tachycardia, atrial fibrillation, primary lung cancer in the left lower lobe, and morbid obesity (weight, 124 kg; height, 170 cm; body mass index [BMI], 42.9 kg/m²). The aortic aneurysm required emergency surgery. However, because of the patient's morbid obesity, elective vascular graft replacement of the thoracic ascending aorta, aortic valve replacement, pulmonary vein isolation surgery, and segmental left lower

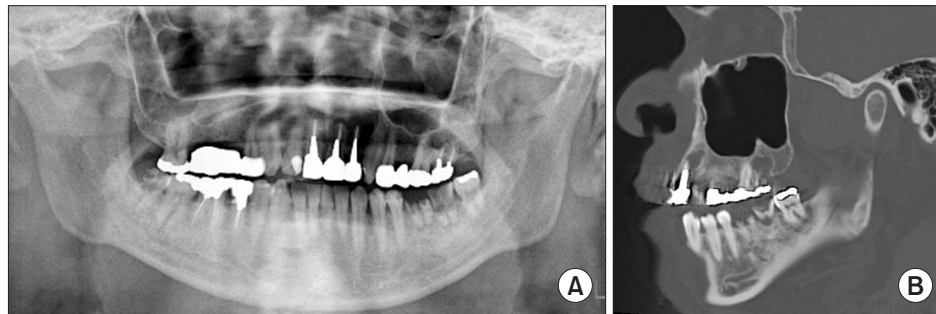


Fig. 1. Imaging findings. A. Original panoramic X-ray findings. Periapical lesions are observed in the apical area of the right mandibular third molar, left mandibular first and second molars, and left maxillary central incisor. B. Computed tomography findings (sagittal section image). Cyst-like images are observed in the apical area of the left maxillary lateral incisor and second molar.

Mika Seto et al: Oral surgery under local anesthesia with dexmedetomidine sedation in a morbidly obese patient with aortic dissection. J Korean Assoc Oral Maxillofac Surg 2016

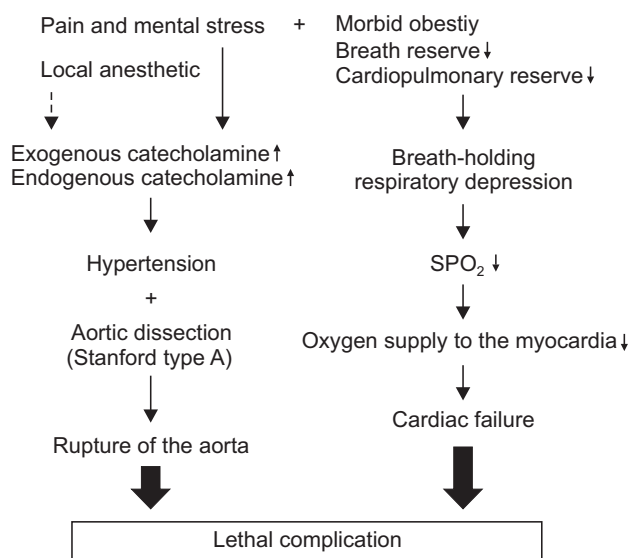


Fig. 2. Problems in the invasive treatment of this patient. *Mika Seto et al: Oral surgery under local anesthesia with dexmedetomidine sedation in a morbidly obese patient with aortic dissection. J Korean Assoc Oral Maxillofac Surg 2016*

lobe resection were planned after gradual weight reduction with dietary therapy. On hospital day 16, the patient underwent a preoperative detailed intraoral examination in our department. At the patient’s first visit to our department, his weight was 109 kg (BMI, 37.7 kg/m²). Intraoral examination revealed six teeth with periapical lesions and two pigeon egg-sized radicular cysts that could become potential sources of infection after surgery.(Fig. 1)

The patient was at increased risk of developing severe complications of aortic aneurysm such as cardiac failure and rupture of the aorta through a sudden increase in blood pressure^{1,2}.(Fig. 2) The use of intravenous sedation was deemed appropriate to avoid sudden changes in blood pressure and to stabilize the patient’s hemodynamics. The patient’s respiratory depression due to morbid obesity also required attention.

Accordingly, we planned to use DEX⁴, which is reported to cause mild respiratory depression, for sedation. The surgery and sedation procedure were explained to the patient, and informed consent was obtained. The surgery involved three oral surgeons, one board-certified dental anesthesiologist, and one nurse. The patient was required to fast for six hours before the procedure. We adopted Fowler’s position during the surgery, and vital signs (peripheral capillary oxygen saturation, heart rate, blood pressure, and electrocardiogram) were continuously monitored. Oxygen was administered at 3 L/min through a nasal cannula. An initial loading dose of DEX was administered at 4.4 µg/kg/hr for 10 minutes, followed by continuous infusion at 0.075 to 0.3 µg/kg/hr. The procedure took 1 hour 27 minutes to complete, with stable hemodynamics throughout and no marked changes, even during local anesthesia with 2% lidocaine and 1:80,000 epinephrine.(Fig. 3) Surgery was safely completed without any complications. For postoperative analgesia, oral celecoxib 400 mg/day was administered until 24 hours after surgery. Thereafter, acetaminophen 3,000 mg/day and loxoprofen sodium hydrate 60 mg were administered as rescue analgesics. Postoperative hemostasis was satisfactory, and no perioperative complications were observed.

III. Discussion

A dental surgeon should have knowledge of multiple systemic diseases and have the ability to plan and perform appropriate treatment procedures in patients requiring whole body management. Herein, we report successful invasive oral treatment in the form of tooth extractions and cystectomies for the removal of intraoral infectious sources before elective cardiac surgery in a 45-year-old morbidly obese male patient with an aortic aneurysm. Aortic aneurysms are a medical

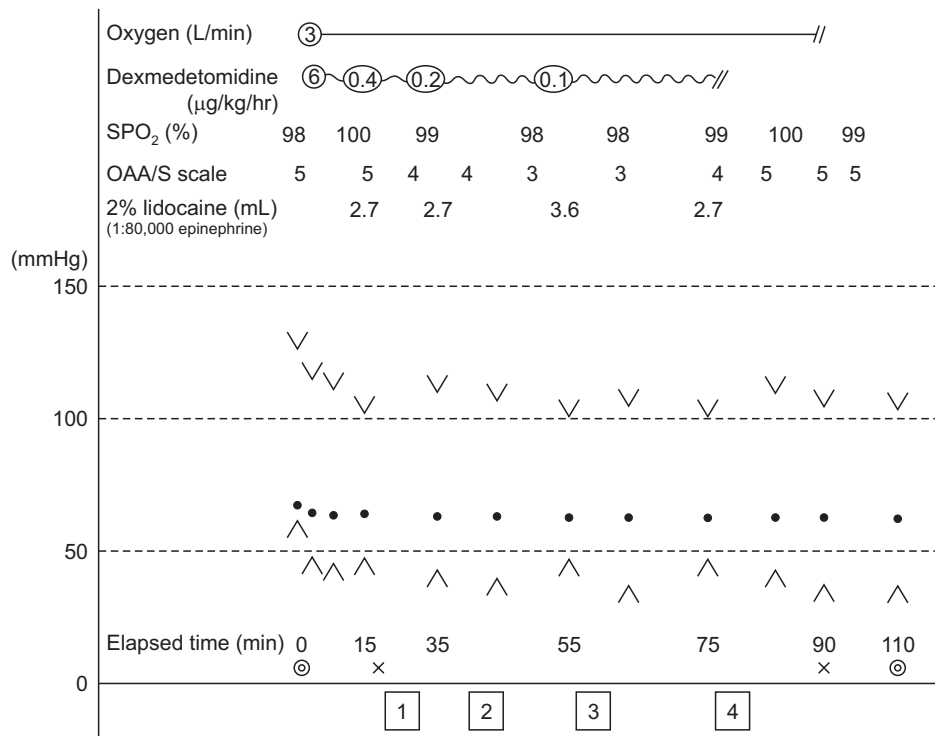


Fig. 3. Summary of the therapeutic procedure. ①: Extraction of the left maxillary lateral second molar and cyst enucleation. ②: Extraction of the left maxillary central incisor and lateral incisor and cyst enucleation. ③: Extraction of the left mandibular first and second molars. ④: Extraction of the right mandibular third molar. Observer's assessment of alertness/sedation (OAA/S) scale: Score level 5=responds readily to name spoken in normal tone, score level 4=lethargic response to name spoken in normal tone, score level 3=responds only after name is called loudly and/or repeatedly, score level 2=responds only after mild prodding or shaking, score level 1=does not respond to mild prodding or shaking. x to x: sedative duration, ◎ to ◎: operative duration.

Mika Seto et al: Oral surgery under local anesthesia with dexmedetomidine sedation in a morbidly obese patient with aortic dissection. J Korean Assoc Oral Maxillofac Surg 2016

emergency and can quickly lead to death. The prime consideration of the medical management for aortic aneurysms is strict blood pressure control¹.

Physical and emotional stress such as anxiety or pain increases blood pressure, and patients undergoing dental treatment are generally anxious. Long surgical duration and intraoperative postural maintenance during oral surgical procedures can cause physical and emotional stress. Moreover, the use of local anesthetics with vasoconstrictors during invasive procedures such as tooth extraction and pain due to an inadequate response to infiltration anesthesia can increase blood pressure. In our patient, the stabilization of circulatory dynamics was very important to prevent the progression and rupture of the aortic aneurysm through a sudden increase in blood pressure. Initially, we considered using 3% mepivacaine without a vasoconstrictor for local anesthesia. However, 2% lidocaine with 1:80,000 epinephrine was selected for the following reasons. First, mepivacaine is believed to have weaker anesthetic effects compared to lidocaine. Second, the effects of epinephrine⁵ added to the local anesthetic are short-lived, lasting only a few minutes. Finally, an increase in endogenous epinephrine secretion induced by pain can increase blood pressure to a greater extent than exogenous epinephrine.

DEX is a popular sedative used in the intensive care unit for patients undergoing mechanical ventilation and has been

recently approved for use in Japan in non-intubated patients requiring sedation.

Since the patient's diaphragmatic movement would be impaired with consequent breathing difficulty in the supine position because of his morbid obesity, the procedures were performed with the patient in Fowler's position. Furthermore, the patient had a mild respiratory reserve capacity and was highly sensitive to sedatives, raising the concern of sleep apnea. Therefore, it was considered appropriate to use sedatives that caused mild respiratory depression.

Aortic regurgitation is widely known to cause infective endocarditis. Montazem⁶ reported that infective endocarditis can be observed with high frequency in cases of oral infection. Therefore, the elimination of intraoral infectious sources before cardiac surgery, particularly valve replacement, is important⁷. However, severe complications are known to possible during oral surgical procedures in patients with cardiac comorbidities. Care must be taken to prevent the development of life-threatening complications in patients undergoing oral surgical procedures in order to improve the success rate of cardiac surgeries in patients with cardiac comorbidities. Intravenous sedation is extremely useful in stabilizing circulatory dynamics in such patients, and midazolam and propofol are commonly used sedatives. The former induces a dose-related settlement of the tongue root and respiratory depression, while the latter exhibits inhibitory effects on the

heart and cardiovascular status. In addition to causing respiratory depression, DEX is an agonist of α_2 -adrenergic receptors in certain parts of the brain⁵, causing mild respiratory depression and exhibiting myocardial protective effects and analgesic and sedative effects³. We believe that DEX was the most suitable for our patient, in whom oral surgical procedures were associated with very high risk and might not have been possible without sedation using DEX.

In conclusion, our understanding of risk factors associated with systemic diseases enabled us to plan and safely perform oral surgical procedures with appropriate perioperative whole body management in a patient scheduled to undergo subsequent cardiac surgery.

Conflict of Interest

No potential conflict of interest relevant to this article was reported.

ORCID

Mika Seto, <http://orcid.org/0000-0002-7548-7613>

Michitaka Matsuda, <http://orcid.org/0000-0003-1149-7924>

Kyoichi Narihira, <http://orcid.org/0000-0002-9485-2102>

Toshihiro Kikuta, <http://orcid.org/0000-0002-8676-5965>

References

1. Hiratzka LF, Bakris GL, Beckman JA, Bersin RM, Carr VF, Casey DE Jr, et al. 2010 ACCF/AHA/AATS/ACR/ASA/SCA/SCAI/SIR/STS/SVM guidelines for the diagnosis and management of patients with thoracic aortic disease: a report of the American College of Cardiology Foundation/American Heart Association Task Force on Practice Guidelines, American Association for Thoracic Surgery, American College of Radiology, American Stroke Association, Society of Cardiovascular Anesthesiologists, Society for Cardiovascular Angiography and Interventions, Society of Interventional Radiology, Society of Thoracic Surgeons, and Society for Vascular Medicine. *Circulation* 2010;121:e266-369.
2. Hagl C, Khaladj N, Peterss S, Bonz A, Pichlmaier M, Haverich A, et al. Treatment of acute aortic dissection type A (AADA): technical considerations. *Vasa* 2010;39:212-8.
3. Cormack JR, Orme RM, Costello TG. The role of alpha₂-agonists in neurosurgery. *J Clin Neurosci* 2005;12:375-8.
4. Paris A, Tonner PH. Dexmedetomidine in anaesthesia. *Curr Opin Anaesthesiol* 2005;18:412-8.
5. Lands AM. The pharmacological activity of epinephrine and related dihydroxyphenylalkylamines. *Pharmacol Rev* 1949;1:279-309.
6. Montazem A. Antibiotic prophylaxis in dentistry. *Mt Sinai J Med* 1998;65:388-92.
7. Michel PL, Acar J. Native cardiac disease predisposing to infective endocarditis. *Eur Heart J* 1995;16 Suppl B:2-6.