



# Retrospective clinical study of multiple keratocystic odontogenic tumors in non-syndromic patients

Dae-Seok Hwang<sup>1</sup>, Yun-Ho Kim<sup>1</sup>, Uk-Kyu Kim<sup>1</sup>, Mi-Heon Ryu<sup>2</sup>, Gyoo-Cheon Kim<sup>2</sup>

<sup>1</sup>Department of Oral and Maxillofacial Surgery, School of Dentistry, Pusan National University,

<sup>2</sup>Institute of Translational Dental Sciences, Pusan National University, Yangsan, Korea

**Abstract** (J Korean Assoc Oral Maxillofac Surg 2018;44:107-111)

**Objectives:** A keratocystic odontogenic tumor (KOT) is a type of odontogenic tumor that mainly occurs in the posterior mandible. Most KOTs appear as solitary lesions; however, they sometimes occur as multiple cysts. This study analyzed the clinical features of multiple KOTs.

**Materials and Methods:** The participants were diagnosed with KOT by biopsy with multiple surgical sites, and were patients at the Pusan National University Hospital and the Pusan National University Dental Hospital from January 1, 2005 to March 31, 2016. Charts, records, images and other findings were reviewed.

**Results:** A total of 31 operations were conducted in 17 patients. The mean patient age was 28.4±20.1 years. Multiple KOTs were found to occur at a young age ( $P<0.01$ ). The predominant sites were in the posterior mandible (28.6%). Most cases of multiple lesions appeared in both the upper and lower jaw, and 40.3% of lesions were associated with unerupted and impacted teeth. The overall recurrence rate measured by operation site was 10.4% (8/77 sites). No patients were associated with nevroid basal cell carcinoma syndrome.

**Conclusion:** The pure recurrence rate was lower than estimated, but there was a higher possibility of secondary lesions regardless of the previous operation site; therefore, long-term follow-up is necessary.

**Key words:** Keratocystic odontogenic tumor, Odontogenic keratocyst, Odontogenic cyst, Keratocyst

[paper submitted 2017. 12. 11 / revised 1st 2018. 1. 16, 2nd 2018. 2. 7 / accepted 2018. 2. 12]

## I. Introduction

The World Health Organization (WHO) recently classified the keratocystic odontogenic tumor (KOT), previously referred to as an odontogenic keratocyst (OKC), as a ‘tumor,’ and not as a cyst, because of its aggressive nature, high mitotic rate, and association with genetic and chromosomal abnormalities<sup>1</sup>.

KOTs primarily occur in the areas of teeth that erupt in the mouth, or in the posterior site of the mandibular third molars.

Most KOTs appear as separated, solitary lesions, but they can also appear as multiple cysts. According to previous studies on single lesions, KOT is predominant in males, and occurs in people as young or younger than 20 years, with a recurrence rate of 3% to 60%<sup>2-4</sup>. However, few studies investigated KOTs with multiple lesions. In cases of KOTs with multiple lesions, tumor involvement in the jaws is greater, and if the tumors are left untreated, a patient with multiple lesions may have higher risks of morbidity compared to someone with a single lesion. Therefore, it is necessary to determine: 1) the number of lesions per patient; 2) whether there is a difference between single lesion KOTs and multiple lesions; and 3) the postoperative recurrence rate. As such, the goal of this study was to evaluate the clinical features of multiple KOT patients with respect to age, sex, prevalent sites, invasiveness, recurrence, treatment, prognosis, and relevance with systemic syndromes.

### Yun-Ho Kim

Department of Oral and Maxillofacial Surgery, Pusan National University Dental Hospital, 20 Geumo-ro, Mulgeum-eup, Yangsan 50612, Korea

TEL: +82-55-360-5100 FAX: +82-55-360-5104

E-mail: stention@naver.com

ORCID: <https://orcid.org/0000-0002-3533-6693>

© This is an open-access article distributed under the terms of the Creative Commons Attribution Non-Commercial License (<http://creativecommons.org/licenses/by-nc/4.0/>), which permits unrestricted non-commercial use, distribution, and reproduction in any medium, provided the original work is properly cited.

Copyright © 2018 The Korean Association of Oral and Maxillofacial Surgeons. All rights reserved.

## II. Materials and Methods

Patients in this study were those with a confirmed diagnosis of KOT through biopsy, and those who underwent surgery with an estimated diagnosis of multiple KOTs on two or more surgical sites. Patient data was obtained from the records of the Department of Oral and Maxillofacial Surgery in the Pusan National University Hospital, and from the Pusan National University Dental Hospital, for approximately 11 years and 3 months (from January 1, 2005 to March 31, 2016). All histologic diagnosis titles were acknowledged as KOT, and not OKC, by the Department of Pathology, following the recent classification decision of WHO.

The patients and specific surgical sites were retrospectively analyzed based on patient medical records, radiographs, and biopsy results. The analyses were based on various perspectives, including sex and age, lesion site, operative methods, number of operations per patient, recurrence rates, recurrence sites, and tendency and association with unerupted or impacted teeth. When counting the number of multiple lesions, a follicular space with a diameter of 3 mm or more was determined as one cystic lesion. Data are shown as mean±standard deviation, and differences between the groups were determined with a two-tailed Student's t-test to calculate the *P*-values, and *P*<0.05 was considered statistically significant. All analyses were performed by using IBM SPSS Statistics ver. 21.0 (IBM Co., Armonk, NY, USA).

This study was approved by the Institutional Review Board of the Pusan National University Dental Hospital (PNUDH-2017-019).

**Table 1.** Multiple keratocystic odontogenic tumor (KOT) patients by sex and age

Age (yr)	Patient (n)	Male (n)	Female (n)	Incidence rates (%)
≤ 19	9	3	6	52.9
20-29	3	2	1	17.6
30-39	0	0	0	0
40-49	1	1	0	5.9
50-59	3	2	1	17.6
60-69	0	0	0	0
≥ 70	1	0	1	5.9
Total	17	8	9	

Nine individuals were under the age of 19 years, and three individuals were in their 20s and 50s. One patient who was in his 40s, and one was in his 70s. The mean age of the entire sample was 28.4±20.1 years. Multiple KOTs were more prevalent in patients younger than the mean age (28.4 years), as opposed to the older group, and the differences among the age groups were statistically significant (*P*<0.01). There was no difference between male and female patients (*P*=0.81).

Dae-Seok Hwang et al: Retrospective clinical study of multiple keratocystic odontogenic tumors in non-syndromic patients. J Korean Assoc Oral Maxillofac Surg 2018

## III. Results

Seventeen patients were selected, and 31 operations were performed on 77 KOT sites. There were no significant differences in the prevalence of KOTs between males and females (*P*=0.81). No patients had clinical signs of nevoid basal cell carcinoma syndrome (NBCCS), such as palmar/plantar pits, and no patients had rib anomalies, such as bifid ribs in preoperative chest x-ray results.

## IV. Discussion

KOT usually occurs as a single lesion, although it can also occur as multiple lesions. In a study conducted by González-Alva et al.<sup>5</sup>, 24 patients had multiple KOTs from a total of 183 KOT cases. Therefore, we examined the characteristics of KOTs that appeared in multiple lesions in this study.

KOT is generally known to occur in young individuals. According to Myoung et al.<sup>6</sup>, the most frequent occurrence was noted in individuals aged 30 years or less. According to Chirapathomsakul et al.<sup>7</sup>, as in most other studies, KOT was most prevalent at 11 to 40 years of age. Chirapathomsakul et

**Table 2.** Analysis of lesion occurrence sites

Site	No. of lesions (%) (n=77)	No. of patients (%) (n=17)
Maxilla		
Anterior maxilla	5 (6.5)	-
Posterior maxilla (molar region)	12 (15.6)	-
Posterior maxilla (tuberosity)	14 (18.2)	-
Maxilla only	-	1 (5.9)
Mandible		
Anterior mandible	7 (9.1)	-
Posterior mandible (molar region)	17 (22.1)	-
Posterior mandible (angle & ramus)	22 (28.6)	-
Mandible only	-	4 (23.5)
Both maxilla & mandible	-	12 (70.6)
Mean no. of sites	2.48 (sites/operations, 77/31)	4.53 (sites/patients, 77/17)

Values are presented as number (%) or mean only.

Each lesion could be observed separately on the radiograph and was counted as one site.

The tendency of lesions to appear at a posterior site of the molar region was higher than the tendency at an anterior site, and the lesions were commonly located in the maxilla and in the mandible. Overall, 77 lesions were identified among the 17 patients, with 4.53 lesions per patient.

Dae-Seok Hwang et al: Retrospective clinical study of multiple keratocystic odontogenic tumors in non-syndromic patients. J Korean Assoc Oral Maxillofac Surg 2018

**Table 3.** Treatment methods

	Enucleation	Marsupialization
No. of patients	16	1

All treatments were conducted with enucleation, except in one case that involved marsupialization.

Dae-Seok Hwang et al: Retrospective clinical study of multiple keratocystic odontogenic tumors in non-syndromic patients. *J Korean Assoc Oral Maxillofac Surg* 2018

al.<sup>7</sup> reported that men and women were almost equal in incidence, although some studies found a higher occurrence in males. This study revealed similar results. There was no definite correlation between gender and multiple KOTs, although was significantly prevalence in teenagers. The patients' mean ages were 28.4±20.1.(Table 1)

KOT is more prevalent in the mandible than in the maxilla, with a large number of sites occurring in the posterior body and ascending ramus. Previous studies found that KOT had a marked tendency to involve the posterior body and the ascending ramus of the mandible, with a 49% rate of incidence<sup>8,9</sup>, which was similar to the results of the this study. The most prevalent site was the mandibular posterior area. In the present site, the molar region and angle, as well as the ramus of the mandible, accounted for 50.6% (39 of 77 sites) of the total sites.(Table 2)

Between the maxilla and the mandible, the mandible was a more common site of multiple KOTs. However, the most popular types were lesions in both the maxilla and the mandible (Table 2), which were similar to the results of a previous study conducted by Chirapathomsakul et al.<sup>7</sup>, which reported significantly more multilocular lesions in the mandible as opposed to the maxilla.

Almost all of the operations were enucleations, except for one case of marsupialization (Table 3), although this particular case changed to enucleation during treatment. According to a systematic review by Blanas et al.<sup>10</sup>, the recurrence rate of KOT was 17% to 56% when only simple enucleation was performed. However, according to the systematic review of 997 KOT lesions by Al-Moraissi et al.<sup>11</sup> that was based on 14 articles, the recurrence rates were 18.2% for enucleation and 27.1% for decompression; accordingly, enucleation was considered to be more useful in preventing the recurrence of KOT, and should be chosen if possible.

KOT has a thin and weak wall, and is usually accompanied by a daughter cyst. Therefore, it is not easy to completely remove a KOT with a simple enucleation<sup>12</sup>. However, enucleation is currently the most common surgical method<sup>13-15</sup>. To lessen the recurrence rate, we should consider additional surgical methods after enucleation, such as cautery with chemi-

cals (e.g., Carnoy's solution), or cryotherapy and peripheral ostectomy by using a round bur<sup>15,16</sup>.

Resection with a safety margin could be another alternative. However, Blanas et al.<sup>10</sup> reported a problem with high morbidity when this method was used, despite the recurrence rate of 0%. Also, it was not commonly accepted by patients and surgeons because of its benign nature.

To measure recurrence rates, we should differentiate purely recurred lesions from secondary lesions. Secondary lesions come from other sites not associated with a previous operation site. Purely recurred lesions are lesions that actually recurred from a previous operation site. According to one study, the frequency of recurrence of KOT in various studies ranges from 5% to 62%<sup>9</sup>. Chirapathomsakul et al.<sup>7</sup> reported a KOT recurrence rate of 22.6%, while Myoung et al.<sup>6</sup> reported 58.3%. Moreover, Myoung et al.<sup>6</sup> reported a total of 11.7% of patients experienced two or more recurrences. Then, when an oral cavity was divided into six parts by region, the recurrence rate was high in the mandibular posterior part. Finally, González-Alva et al.<sup>5</sup> found a recurrence rate of 13.1%.

In this study, the recurrence rate was 10.4% (8 of 77 sites), and the rate of re-operation on one patient was 47.1%.(Table 4, Fig. 1) The recurrence rate may vary by calculation because it will be based on either one patient or each lesion. Therefore, a simple comparison with other studies might be difficult, although such a study could be useful. Jo et al.<sup>17</sup> reported that patients with multiple lesions showed a higher recurrence rate than patients with single lesions.

The lesions associated with the unerupted or impacted teeth were present in 31 sites with a rate of 40.3%. Of the 17 patients, 9 patients (52.9%) were identified as having KOT lesions associated with embedded teeth.(Table 5, Supplementary Table 1) In one study, 25% to 40% of cases involved unerupted teeth<sup>9</sup>. Chirapathomsakul et al.<sup>7</sup> reported that the proportion of lesions related to teeth was 33%, which was higher compared to other studies<sup>8,18,19</sup>.

Multiple KOTs are frequently associated with NBCCS. Epidermal cysts of the skin, palmar/plantar pits, calcified falx cerebri, enlarged head circumference, rib anomalies (e.g., bifid rib), and OKCs are major clinical features of the NBCCS<sup>9,20</sup>. Basal budding, which is common in KOTs associated with NBCCS, was found in the histological finding of one patient, but there were no definite patients with syndromic signs in this study. Other studies also showed a low association with the syndrome. Indeed, according to González-Alva et al.<sup>5</sup>, only 6.0% of patients were clinically related to NBCCS.

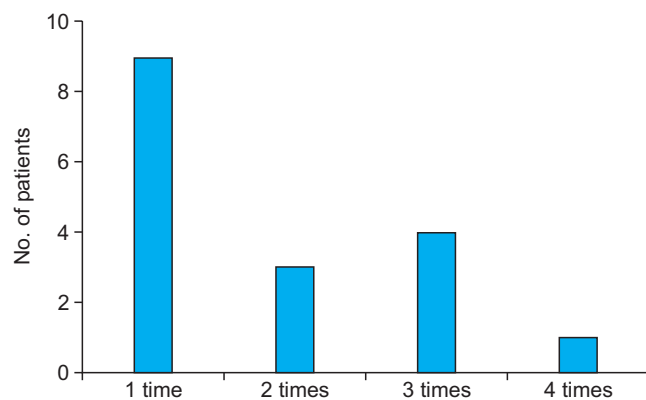
**Table 4.** Recurrence tendency and rate

	Value
Re-operation surgery	14 sites (8 patients)
Secondary lesion (other site)	8 (57.1)
Recurrence of previous operation site	6 (42.9)
Re-operation rate	47.1 (8/17 patients)
Secondary lesion incidence rate	25.8 (8/31 operations)
Previous operation site recurrence rate	19.4 (6/31 operations)
Recurrence rate by operation site	10.4 (8/77 sites)

Values are presented as number only, number (%), or % (number/total number).

Recurrence tendencies and rates were estimated from various perspectives. Of the 14 re-operations, 8 cases were re-operations due to secondary lesions in another area, and 6 re-operations were due to the recurrence of the previous operation sites. Of 17 patients, 8 patients underwent re-operations. Of the 31 operations, 8 operations (25.8%) were performed due to secondary lesions in other sites, and 6 operations (19.4%) occurred because of recurrence in the previous operation sites. A total of 77 sites were removed through 31 surgeries, of which 8 sites showed recurrence (10.4%).

Dae-Seok Hwang et al: Retrospective clinical study of multiple keratocystic odontogenic tumors in non-syndromic patients. *J Korean Assoc Oral Maxillofac Surg* 2018



**Fig. 1.** Frequency of operations for each patient. Patients had an average of 1.82 operations, including surgeries due to recurrence. One patient had four operations, which was the maximum number of operations per person.

Dae-Seok Hwang et al: Retrospective clinical study of multiple keratocystic odontogenic tumors in non-syndromic patients. *J Korean Assoc Oral Maxillofac Surg* 2018

## V. Conclusion

Multiple KOTs are typically prevalent in young individuals, especially among teenagers. Predilection sites include the mandibular molar and posterior regions. Pure recurrence rates are lower than the estimated rates, but there is a higher possibility of secondary lesions regardless of the previous operation site. Therefore, a long-term follow-up is necessary. No definite association with NBCCS was found in this study.

**Table 5.** Association with unerupted and impacted teeth

Site	No. of patients (%)
#38, #48 (mandibular 3rd molar)	12 (38.7)
#18, #28 (maxillary 3rd molar)	8 (25.8)
#17, #27 (maxillary 2nd molar)	6 (19.4)
#37, #47 (mandibular 2nd molar)	2 (6.5)
#35, #45 (mandibular 2nd premolar)	2 (6.5)
#23 (maxillary canine)	1 (3.2)
Total	31/77 sites (40.3) <sup>1</sup>
No relevance	46/77 sites (59.7) <sup>2</sup>

<sup>1</sup>9 patients (9/17, 52.9%), <sup>2</sup>8 patients (8/17, 47.1%).

Many lesions were associated with unerupted and impacted teeth, with the mandibular third molar showing the most association.

Dae-Seok Hwang et al: Retrospective clinical study of multiple keratocystic odontogenic tumors in non-syndromic patients. *J Korean Assoc Oral Maxillofac Surg* 2018

## ORCID

Dae-Seok Hwang, <https://orcid.org/0000-0001-6899-1769>

Yun-Ho Kim, <https://orcid.org/0000-0002-3533-6693>

Uk-Kyu Kim, <https://orcid.org/0000-0003-1251-7843>

Mi-Heon Ryu, <https://orcid.org/0000-0003-1283-9762>

Gyoo-Cheon Kim, <https://orcid.org/0000-0003-3568-3529>

## Authors' Contributions

D.S.H. participated in the study design. Y.H.K. participated in data collection and wrote the manuscript. U.K.K., M.H.R., and G.C.K. participated in the study design and coordination and helped to draft the manuscript. All authors read and approved the final manuscript.

## Acknowledgements

This work was supported by a two year research grant of Pusan National University.

## Ethics Approval and Consent to Participate

This study was approved by the Institutional Review Board of the Pusan National University Dental Hospital (PNUDH-2017-019). The informed consent was waived.

## Supplementary Materials

Supplementary data is available at <http://www.jkaoms.org>.

## Conflict of Interest

No potential conflict of interest relevant to this article was reported.

## References

- Philipsen HP, Reichart PA. Classification of odontogenic tumours. A historical review. *J Oral Pathol Med* 2006;35:525-9.
- Habibi A, Saghravanian N, Habibi M, Mellati E, Habibi M. Keratocystic odontogenic tumor: a 10-year retrospective study of 83 cases in an Iranian population. *J Oral Sci* 2007;49:229-35.
- Shear M, Seward GR. *Cysts of the oral regions*. 3rd ed. Oxford, Boston: Wright; 1992.
- Zecha JA, Mendes RA, Lindeboom VB, van der Waal I. Recurrence rate of keratocystic odontogenic tumor after conservative surgical treatment without adjunctive therapies: a 35-year single institution experience. *Oral Oncol* 2010;46:740-2.
- González-Alva P, Tanaka A, Oku Y, Yoshizawa D, Itoh S, Sakashita H, et al. Keratocystic odontogenic tumor: a retrospective study of 183 cases. *J Oral Sci* 2008;50:205-12.
- Myoung H, Hong SP, Hong SD, Lee JI, Lim CY, Choung PH, et al. Odontogenic keratocyst: review of 256 cases for recurrence and clinicopathologic parameters. *Oral Surg Oral Med Oral Pathol Oral Radiol Endod* 2001;91:328-33.
- Chirapathomsakul D, Sastravaha P, Jansisyanont P. A review of odontogenic keratocysts and the behavior of recurrences. *Oral Surg Oral Med Oral Pathol Oral Radiol Endod* 2006;101:5-9.
- Brannon RB. The odontogenic keratocyst. A clinicopathologic study of 312 cases. Part I. Clinical features. *Oral Surg Oral Med Oral Pathol* 1976;42:54-72.
- Neville BW, Damm DD, Chi AC, Allen CM. *Oral and maxillofacial pathology*. 4th ed. Philadelphia: W.B. Saunders; 2015.
- Blanas N, Freund B, Schwartz M, Furst IM. Systematic review of the treatment and prognosis of the odontogenic keratocyst. *Oral Surg Oral Med Oral Pathol Oral Radiol Endod* 2000;90:553-8.
- Al-Moraissi EA, Pogrel MA, Ellis E 3rd. Enucleation with or without adjuvant therapy versus marsupialization with or without secondary enucleation in the treatment of keratocystic odontogenic tumors: a systematic review and meta-analysis. *J Craniomaxillofac Surg* 2016;44:1395-403.
- Jackson IT, Potparic Z, Fasching M, Schievink WI, Tidstrom K, Hussain K. Penetration of the skull base by dissecting keratocyst. *J Craniomaxillofac Surg* 1993;21:319-25.
- Eyre J, Zakrzewska JM. The conservative management of large odontogenic keratocysts. *Br J Oral Maxillofac Surg* 1985;23:195-203.
- Chow HT. Odontogenic keratocyst: a clinical experience in Singapore. *Oral Surg Oral Med Oral Pathol Oral Radiol Endod* 1998;86:573-7.
- Park SY, Shin YJ, Kim CH, Kim BJ. Reconstruction of extensive jaw defects induced by keratocystic odontogenic tumor via patient-customized devices. *Maxillofac Plast Reconstr Surg* 2015;37:37.
- Waldron CA. Odontogenic cysts and tumors. In: Neville BW, Damm DD, Allen CM, Bouquot JE, eds. *Oral and maxillofacial pathology*. 2nd ed. Philadelphia: W.B. Saunders; 2002:594-7.
- Jo HW, Choi SY, Kim HS, Kwon TG, Jang HJ, Lee SH, et al. Clinical and radiographic evaluation of recurrent odontogenic keratocysts. *J Korean Assoc Maxillofac Plast Reconstr Surg* 2010;32:431-6.
- Haring JI, Van Dis ML. Odontogenic keratocysts: a clinical, radiographic, and histopathologic study. *Oral Surg Oral Med Oral Pathol* 1988;66:145-53.
- Partridge M, Towers JF. The primordial cyst (odontogenic keratocyst): its tumour-like characteristics and behaviour. *Br J Oral Maxillofac Surg* 1987;25:271-9.
- Park JH, Yoon KH, Park KS, Cheong JK, Shin JM, Choi MK. Case report of multiple odontogenic keratocysts with basal cell nevus syndrome. *J Korean Assoc Maxillofac Plast Reconstr Surg* 2008;30:172-7.



Patient No.	Sex	Age	Op. times	site Mx. Ant.	Mx. Molar	Mx. Post.	Mn. Ant.	Mn. Molar	Mn. Post.	Mx./Mn.	Recur./2nd pr.	Association with unerupted teeth
1	F	21	3		1					Mn. 2 1		X
2	M	21	1			2		1		1 Mx. & Mn.		O #17,27,38
3	M	13	4	1		2 1		1 1 1		2 Mx. & Mn.		O #18,28,38,48
4	M	55	1		1			1		1 Mx. & Mn.		X
5	F	14	2		2					2 Mx. & Mn. 1		O #17,38, #64,65 #28
6	F	18	2			1 2	1			Mx. & Mn.		O #18
7	F	15	1	2				1		Mx. & Mn.		O #23,48
8	F	79	1				1	1		Mn.		X
9	F	55	3					1 2		Mn.		X
10	F	15	3				1			1 Mx. & Mn. 1 1		X
11	M	14	3		1 1 1	1 1				2 Mx. & Mn. 1		O #28,38,48
12	M	14	2				1 1	1 1		Mn.		#75
13	F	17	1			1		1		1 Mx. & Mn.		O #28,38
14	M	42	1	1	2					Mx.		X
15	F	11	1		2		1	2		2 Mx. & Mn.		O #17,27,37,38,35,45,47,48
16	M	29	1	1		2		1		2 Mx. & Mn.		O #18,27,28,38,48
17	M	50	1				1			1 Mn.		X
Total			31	5	12	14	7	17	22			

(No.: number, Op.: operation, Mx.: maxilla, Ant.: anterior, Post.: posterior, Mn.: mandible, Recur.: recurrence, pr.: primary, F: female, M: male)