



Comparison of the efficacy of amoxicillin-clavulanic acid with metronidazole to azithromycin with metronidazole after surgical removal of impacted lower third molar to prevent infection

Shermil Sayd¹, Suresh Vyloppilli², Krishna Kumar³, Pramod Subash⁴, Nithin Kumar⁵, Sarfras Raseel⁵

¹Department of Oral and Maxillofacial Surgery, Kannur Dental College, Anjarakandy Integrated Campus, Kannur;

²Department of Oral and Maxillofacial Surgery and Dentistry, Malankara Orthodox Syrian Church Medical College & Hospital, Kolenchery, Kochi, ³Department of Cleft and Craniomaxillofacial Surgery, Aster MIMS Hospital, Calicut,

⁴Department of Craniomaxillofacial Surgery, Amrita School of Dentistry, Kochi,

⁵Department of Oral and Maxillofacial Surgery, KMCT Dental College, Calicut, India

Abstract (J Korean Assoc Oral Maxillofac Surg 2018;44:103-106)

Objectives: The goal of the study was to investigate the clinical effects of amoxicillin-clavulanic acid (500+125 mg) with metronidazole 400 mg administered three times daily (Group I) versus azithromycin 500 mg administered once daily and with metronidazole 400 mg three times daily (Group II) for the prevention of postoperative infection following mandibular third molar surgical removal.

Materials and Methods: The study design was a single-center prospective study. Patients who reported to the Department of Oral and Maxillofacial Surgery between February 2015 and January 2017 for removal of mandibular third molar were screened, and 108 patients were chosen. One surgeon carried out all procedures. Patients were prescribed antibiotics until the two groups contained a similar number of cases.

Results: Our data showed that Group II had fewer incidences of surgical site infection, but with no statistical significance.

Conclusion: Although both treatments are used routinely after removal of the mandibular third molar, neither is significantly better than the other.

Key words: Impacted third molar removal, Antibiotic prophylaxis, Amoxicillin, Azithromycin, Metronidazole

[paper submitted 2017. 9. 30 / revised 1st 2017. 12. 21, 2nd 2018. 1. 5 / accepted 2018. 1. 22]

I. Introduction

As with any surgical procedure, removal of an impacted third molar is associated with complications, which occur in up to 45% of patients, according to prior studies. Since this is a clean-contaminated surgery, the likelihood of postoperative infection is high, even if exceptional aseptic procedures are followed¹.

As a frequent practice in India, antibiotics are prescribed

by oral surgeons and usually include either a combination of amoxicillin-clavulanic acid or azithromycin, along with metronidazole². This study investigated the efficacy of the two antibiotic combinations for a particular population reporting to our center for prevention of infection following removal of the mandibular third molar.

II. Materials and Methods

This study was conducted in the Department of Oral and Maxillofacial Surgery, Malankara Orthodox Syrian Church Medical College & Hospital, Kolenchery (Kochi, India). The study design was formulated following Strengthening the Reporting of Observational Studies in Epidemiology (STROBE) guidelines after obtaining approval from the ethics committee of Malankara Orthodox Syrian Church Medical College & Hospital, Kolenchery (approval no. MOSCMC/IEC/2015/02). Patients reporting to the Department of Oral and Maxillofacial Surgery between February 2015 and Janu-

Suresh Vyloppilli

Department of Oral and Maxillofacial Surgery and Dentistry, Malankara Orthodox Syrian Church Medical College & Hospital, Kolenchery, Medical College Road, P O Kolenchery, Kochi 682311, India
TEL: +91-9037019991

E-mail: sureshvyloppilli@gmail.com

ORCID: <https://orcid.org/0000-0002-9423-3774>

© This is an open-access article distributed under the terms of the Creative Commons Attribution Non-Commercial License (<http://creativecommons.org/licenses/by-nc/4.0/>), which permits unrestricted non-commercial use, distribution, and reproduction in any medium, provided the original work is properly cited.

Copyright © 2018 The Korean Association of Oral and Maxillofacial Surgeons. All rights reserved.

ary 2017 for removal of a mandibular impacted third molar were selected. The sample size was determined as the number of patients consenting for the procedure and participation during the period of study.

The inclusion criteria were as follows: (1) male or female patient between the ages of 18-30 years; (2) mesioangular impacted tooth; (3) Pell and Gregory classification: Position A, Class I; (4) absence of follicular space; and (5) absence of infection involving the mandibular impacted third molar.

The exclusion criteria were as follows: (1) patient with comorbidities; (2) pregnant or lactating mother; (3) patient with acute infection; (4) history of recent antibiotic therapy; and (5) history of allergy or intolerance to the drugs used in this study.

One surgeon performed all procedures under local anaesthesia. Assuring meticulous asepsis, a full thickness rhomboid flap was raised to aid in bone removal and odontectomy, as required, using rotary instruments. The full duration of the proceedings, from the time of the first incision to the final suture, was recorded. Post-surgical alveolus irrigation was performed using chlorhexidine-digluconate (0.12%) solution for 1 minute in all cases. Wound closure was achieved using 4-0 silk sutures.

Drugs were prescribed as either a course of amoxicillin-clavulanic acid (500+125 mg) with metronidazole 400 mg three times daily (Group I) or azithromycin 500 mg once daily with metronidazole 400 mg three times daily (Group II). Uniform analgesics were prescribed for all combinations of

aceclofenac and acetaminophen. All patients were directed to an emergency review or to a seven-day review. Patients were prohibited from taking other drugs and from seeking medical attention unless it was from our oral surgery department. The diagnosis was made by prior established clinical criteria. On the seven day review, the parameters were recorded accordingly. Patients who underwent emergency care were re-evaluated seven days later.

A total of 150 patients who fulfilled the criteria were selected for this study; after exclusion, the final sample size was 108 patients.

The statistical analyses were performed using IBM SPSS Statistics (ver. 20.0; IBM Co., Armonk, NY, USA). $P < 0.05$ was considered as statistically significant.

III. Results

The sample of 108 patients was composed of 50 males with a mean age of 25.42 years and 58 females with mean age of 24.15 years. The mean age for the total study group was 24.00 ± 6.39 years. (Table 1) The average time recorded for the study was 7.4 minutes, with 4 minutes as the minimum time and 12 minutes as the maximum time. These wide ranges of ages and timing did not show any significant difference according to patient outcome. There was no correlation between patient age and outcome. The presence of surgical site infection decreased in Group II patients, with a P -value of 0.152. (Table 2, Fig. 1)

According to the data obtained, Group II had a lower incidence of surgical site infection but only with a P -value 0.152,

Table 1. Patient age and gender

Gender	Patient	Age (yr)
Male	50 (46.3)	25.42±8.63
Female	58 (53.7)	24.15±3.44

Values are presented as number (%) or mean±standard deviation. *Shermil Sayd et al: Comparison of the efficacy of amoxicillin-clavulanic acid with metronidazole to azithromycin with metronidazole after surgical removal of impacted lower third molar to prevent infection. J Korean Assoc Oral Maxillofac Surg 2018*

Table 2. Incidence of surgical site infection under an antibiotic regimen

Antibiotic regimen	Yes, n (%)	No, n (%)	Total (n)
Amoxicillin metronidazole combination	14 (25.9)	40 (74.1)	54
Azithromycin metronidazole combination	8 (14.8)	46 (85.2)	54
Total	22 (20.4)	86 (79.6)	108

$\chi^2 = 2.05, P = 0.152$.

Shermil Sayd et al: Comparison of the efficacy of amoxicillin-clavulanic acid with metronidazole to azithromycin with metronidazole after surgical removal of impacted lower third molar to prevent infection. J Korean Assoc Oral Maxillofac Surg 2018

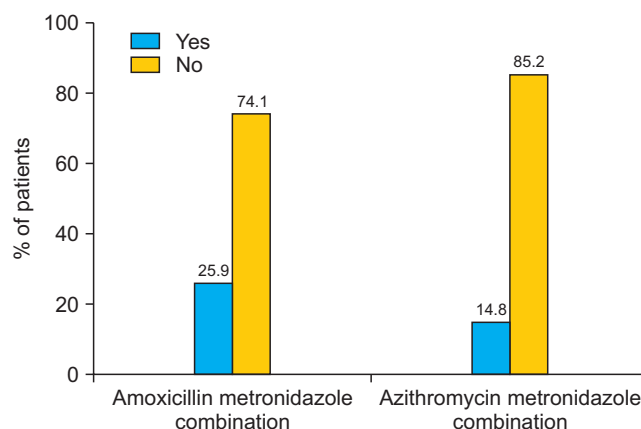


Fig. 1. Description of patients with surgical site infection under an antibiotic regimen.

Shermil Sayd et al: Comparison of the efficacy of amoxicillin-clavulanic acid with metronidazole to azithromycin with metronidazole after surgical removal of impacted lower third molar to prevent infection. J Korean Assoc Oral Maxillofac Surg 2018

which was not statistically significant.

IV. Discussion

The incidence of infection following impacted mandibular third molar surgical removal varies between 0% and 45%³⁻¹². Despite years of clinical data with systemic antibiotics and well-designed clinical studies, a significant debate still exists over the administration of postoperative antibiotics in impacted third molar surgery¹³.

Removal of an impacted third molar results in a higher incidence of bacteremia compared with other oral surgical procedures¹⁴. Blakey et al.¹⁵ reported that 25% of patients with impacted mandibular third molar had asymptomatic periodontitis. The subsequent postoperative infections can cause undesirable outcomes, such as deep space infections, although the incidence is low, at 0.8%¹⁶. Although there is evidence that postoperative antibiotics can lower the incidence of postoperative complications^{12,17}, there is equally convincing evidence to the contrary^{10,17-19}.

Previous clinical trials used postoperative antibiotics²⁰ for the following reasons: (1) presence of infection; (2) medical incapacitation; (3) patient or patient family demands; (4) standard of care in the oral surgery community is to use antibiotics; and (5) high risk of postoperative infection.

Numbers 3 and 4 above are the most common reasons for the prescription of antibiotics. However, clinicians treating such cases should resist such prescription to prevent the development of resistant strains within the community. Multiple studies comparing the efficacy of antibiotics, as mentioned above, found no statistically significant differences. Although there was no control group in the present study, and multiple antibiotics were administered, no statistically significant differences in outcome were observed.

Peterson²¹ stated five principles to guide the proper administration of antibiotics for the best possible practice and patient care. These principles are as follows: (1) proper use in surgical procedures with significant risk of infection; (2) appropriate selection of antibiotics; (3) use of high antibiotic level during surgery; (4) accurate timing of antibiotic administration; and (5) shortest antibiotic exposure as is possible.

One major drawback of our study was the non-differentiation of hard and soft tissue impaction. Piecuch et al.²⁰, in their study involving bony impacted third molars, found that the use of preoperative parenteral antibiotics resulted in significantly reduced postoperative infection rate. However, no advantage was found in soft tissue impaction alone²². Multiple

studies have reported the same, with differences in outcome when differentiation of hard tissue and soft tissue impaction was considered.

The University Dental Hospital National Health Service Trust in Cardiff (UK) audited the use of antibiotics for impacted third molar surgeries and found “the potential for saving large sums of money while apparently incurring no clinical disadvantage”²³, in accord with the literature and now the common belief of many surgeons. Although a discussion about the need for postoperative antibiotics is beyond the scope of this article, we concluded that the administration of antibiotics should be considered only when necessary.

V. Conclusion

Though both groups underwent routine surgical removal of the mandibular mesioangular impacted third molar, neither combination of prescribed antibiotics had significant advantages over the other. Further studies with different methodologies are suggested to confirm our conclusion.

ORCID

Shermil Sayd, <https://orcid.org/0000-0002-1765-8955>

Suresh Vyloppilli, <https://orcid.org/0000-0002-9423-3774>

Krishna Kumar, <https://orcid.org/0000-0001-5599-4717>

Pramod Subash, <https://orcid.org/0000-0002-6526-6243>

Nithin Kumar, <https://orcid.org/0000-0002-5447-5875>

Sarfras Raseel, <https://orcid.org/0000-0002-2870-8583>

Authors' Contributions

S.S., S.V., N.K., and S.R. were involved in the conceptualization, data collection, study conduction and manuscript reviews. K.K. and P.S. helped by guiding, creating the protocol, manuscript and statistical correction and correlations.

Ethics Approval and Consent to Participate

The study was approved by the ethics committee of Malankara Orthodox Syrian Church Medical College & Hospital, Kolenchery (approval no. MOSCMC/IEC/2015/02).

Conflict of Interest

No potential conflict of interest relevant to this article was reported.

References

1. Ortega G, Rhee DS, Papandria DJ, Yang J, Ibrahim AM, Shore AD, et al. An evaluation of surgical site infections by wound classification system using the ACS-NSQIP. *J Surg Res* 2012;174:33-8.
2. Ramu C, Padmanabhan TV. Indications of antibiotic prophylaxis in dental practice: review. *Asian Pac J Trop Biomed* 2012;2:749-54.
3. Lacasa JM, Jiménez JA, Ferrás V, Bossom M, Sóla-Morales O, García-Rey C, et al. Prophylaxis versus pre-emptive treatment for infective and inflammatory complications of surgical third molar removal: a randomized, double-blind, placebo-controlled, clinical trial with sustained release amoxicillin/clavulanic acid (1000/62.5 mg). *Int J Oral Maxillofac Surg* 2007;36:321-7.
4. Graziani F, Corsi L, Fornai M, Antonioli L, Tonelli M, Cei S, et al. Clinical evaluation of piroxicam-FDDF and azithromycin in the prevention of complications associated with impacted lower third molar extraction. *Pharmacol Res* 2005;52:485-90.
5. Arteagoitia I, Diez A, Barbier L, Santamaría G, Santamaría J. Efficacy of amoxicillin/clavulanic acid in preventing infectious and inflammatory complications following impacted mandibular third molar extraction. *Oral Surg Oral Med Oral Pathol Oral Radiol Endod* 2005;100:e11-8.
6. Ren YF, Malmstrom HS. Effectiveness of antibiotic prophylaxis in third molar surgery: a meta-analysis of randomized controlled clinical trials. *J Oral Maxillofac Surg* 2007;65:1909-21.
7. Richardson DT, Dodson TB. Risk of periodontal defects after third molar surgery: an exercise in evidence-based clinical decision-making. *Oral Surg Oral Med Oral Pathol Oral Radiol Endod* 2005;100:133-7.
8. Wilson W, Taubert KA, Gewitz M, Lockhart PB, Baddour LM, Levison M, et al. Prevention of infective endocarditis: guidelines from the American Heart Association: a guideline from the American Heart Association Rheumatic Fever, Endocarditis, and Kawasaki Disease Committee, Council on Cardiovascular Disease in the Young, and the Council on Clinical Cardiology, Council on Cardiovascular Surgery and Anesthesia, and the Quality of Care and Outcomes Research Interdisciplinary Working Group. *Circulation* 2007;116:1736-54.
9. Halpern LR, Dodson TB. Does prophylactic administration of systemic antibiotics prevent postoperative inflammatory complications after third molar surgery? *J Oral Maxillofac Surg* 2007;65:177-85.
10. Poeschl PW, Eckel D, Poeschl E. Postoperative prophylactic antibiotic treatment in third molar surgery--a necessity? *J Oral Maxillofac Surg* 2004;62:3-8; discussion 9.
11. Chuang SK, Perrott DH, Susarla SM, Dodson TB. Risk factors for inflammatory complications following third molar surgery in adults. *J Oral Maxillofac Surg* 2008;66:2213-8.
12. Yoshii T, Hamamoto Y, Muraoka S, Kohjitani A, Teranobu O, Furudo S, et al. Incidence of deep fascial space infection after surgical removal of the mandibular third molars. *J Infect Chemother* 2001;7:55-7.
13. Susarla SM, Sharaf B, Dodson TB. Do antibiotics reduce the frequency of surgical site infections after impacted mandibular third molar surgery? *Oral Maxillofac Surg Clin North Am* 2011;23:541-6, vi.
14. Addy LD, Martin MV. Azithromycin and dentistry: a useful agent? *Br Dent J* 2004;197:141-3; discussion 138.
15. Blakey GH, Marciani RD, Haug RH, Phillips C, Offenbacher S, Pabla T, et al. Periodontal pathology associated with asymptomatic third molars. *J Oral Maxillofac Surg* 2002;60:1227-33.
16. Ishihama K, Kimura T, Yasui Y, Komaki M, Ota Y. Azithromycin as prophylaxis for the prevention of postoperative infection in impacted mandibular third-molar surgery. *J Infect Chemother* 2006;12:31-5.
17. Delilbasi C, Saracoglu U, Keskin A. Effects of 0.2% chlorhexidine gluconate and amoxicillin plus clavulanic acid on the prevention of alveolar osteitis following mandibular third molar extractions. *Oral Surg Oral Med Oral Pathol Oral Radiol Endod* 2002;94:301-4.
18. Yoshii T, Hamamoto Y, Muraoka S, Furudo S, Komori T. Differences in postoperative morbidity rates, including infection and dry socket, and differences in the healing process after mandibular third molar surgery in patients receiving 1-day or 3-day prophylaxis with lenampicillin. *J Infect Chemother* 2002;8:87-93.
19. Bulut E, Bulut S, Etikan I, Koseoglu O. The value of routine antibiotic prophylaxis in mandibular third molar surgery: acute-phase protein levels as indicators of infection. *J Oral Sci* 2001;43:117-22.
20. Piecuch JF, Arzadon J, Lieblich SE. Prophylactic antibiotics for third molar surgery: a supportive opinion. *J Oral Maxillofac Surg* 1995;53:53-60.
21. Peterson LJ. Antibiotic prophylaxis against wound infections in oral and maxillofacial surgery. *J Oral Maxillofac Surg* 1990;48:617-20.
22. Monaco G, Staffolani C, Gatto MR, Checchi L. Antibiotic therapy in impacted third molar surgery. *Eur J Oral Sci* 1999;107:437-41.
23. Thomas DW, Hill CM. An audit of antibiotic prescribing in third molar surgery. *Br J Oral Maxillofac Surg* 1997;35:126-8.