



Clinical analysis of neck node metastasis in oral cavity cancer

Aditi Sharma¹, Jin-Wook Kim¹, Jun-Young Paeng²

¹Department of Oral and Maxillofacial Surgery, Kyungpook National University School of Dentistry, Daegu,

²Department of Oral and Maxillofacial Surgery, Samsung Medical Center, Seoul, Korea

Abstract (J Korean Assoc Oral Maxillofac Surg 2018;44:282-288)

Objectives: The purpose of this study was to evaluate the neck node metastasis pattern and related clinical factors in oral cavity cancer patients.

Materials and Methods: In total, 76 patients (47 males, 29 females) with oral squamous cell carcinoma (OSCC) who had no previous malignancies and were not undergoing neoadjuvant concomitant chemoradiotherapy or radiotherapy were selected for analysis.

Results: Occult metastases were found in 8 of 52 patients with clinically negative nodes (cN0, 15.4%). Neck node metastases were found in 17 patients (22.4%). There was a statistically significant relationship between neck node metastasis and T stage ($P=0.014$) and between neck node metastasis and distant metastasis (Fisher's exact test, $P=0.019$).

Conclusion: Neck node metastasis was significantly related to tumor size and distant metastasis during follow-up.

Key words: Mouth neoplasms, Lymph nodes, Metastasis, Squamous cell carcinoma

[paper submitted 2018. 1. 9 / revised 2018. 3. 12 / accepted 2018. 3. 22]

I. Introduction

The oral cavity is the most common site of malignant tumors of the head and neck¹. The most common malignant tumor type in the oral cavity is squamous cell carcinoma. Oral squamous cell carcinoma (OSCC) is frequently associated with poor prognosis²⁻⁴. Even when the tumors are small (T1 and T2), OSCC carries a high risk of cervical lymph node metastasis. Therefore, management of oral cancer remains controversial, especially for treatment of N0 neck patients. More than 30% of OSCC patients with clinically N0 neck exhibit occult metastasis^{5,6}. Cervical lymph node metastasis is the most significant independent prognostic factor, as it reduces the rate of survival by 50%⁷. Thus, appropriate treatment of cervical lymph nodes is essential for loco-regional control of the disease.

Various studies have revealed that elective neck dissection (END) is more beneficial than the "wait and see" approach in terms of survival rate⁸⁻¹⁰. END reduces the relapse rate and increases disease-free survival (DFS) and overall survival (OS)^{8,10-14}. There are several radiological modalities for detection of neck metastases. The sensitivity and specificity values range from 40% to 68% and 75% to 82%, respectively, for computed tomography (CT); from 50% to 58% and 75% to 82% for ultrasonography; from 55% to 80% and 82% to 92% for magnetic resonance imaging (MRI); and from 57% to 79% and 82% to 96% for positron emission tomography (PET)-CT. Thus, a single radiological modality cannot be used to confirm cervical lymph node metastasis¹².

Surgical options for the neck include END at the time of primary tumor excision or observation with therapeutic neck dissection when neck node metastasis occurs during follow-up⁸⁻¹⁹. Some studies have demonstrated that the neck node (N) category; number, size, and location of positive lymph nodes; and presence of extracapsular spread increase the risk of distant metastasis¹⁶⁻²⁰ and reduce DFS rate²¹⁻²³. END at the time of primary tumor resection was found to reduce loco-regional spread by 93.8% compared with the observation approach^{24,25}. On the other hand, some studies have found no significant difference in DFS and OS between the END group and the observation group^{26,27}. In one study, nodal recurrence was re-

Jun-Young Paeng

Department of Oral and Maxillofacial Surgery, Samsung Medical Center,
81 Irwon-ro, Gangnam-gu, Seoul 06351, Korea
TEL: +82-2-3410-2413 FAX: +82-2-3410-0038
E-mail: jypaeng@gmail.com
ORCID: <https://orcid.org/0000-0002-0104-9338>

© This is an open-access article distributed under the terms of the Creative Commons Attribution Non-Commercial License (<http://creativecommons.org/licenses/by-nc/4.0/>), which permits unrestricted non-commercial use, distribution, and reproduction in any medium, provided the original work is properly cited.

Copyright © 2018 The Korean Association of Oral and Maxillofacial Surgeons. All rights reserved.

ported for 37% of patients in the observation group¹².

Selective neck dissection alone is adequate treatment for oral cancer patients with N0 neck, even though nodal micro-metastases might be missed histopathologically. In patients with N+ neck, selective neck dissection and radiotherapy have been advised for better nodal control. Most patients in the “wait and see” group will require modified radical neck dissection (mRND) later when neck node metastasis occurs during follow-up, and mRND is associated with higher surgical morbidity¹². Therefore, END has been found to be a better treatment modality than the “wait and see” approach, which is usually associated with surgical morbidity. In the management of tongue carcinoma, especially stages I and II, late cervical lymph node metastasis is a major problem due to the high incidence of occult metastasis⁸. However, there is a lack of prospective studies demonstrating the benefits of END over therapeutic neck dissection²⁸.

The purpose of this study was to evaluate the neck node metastasis pattern and related clinical factors in oral cavity cancer patients. The clinical factors that correlated with neck node metastasis in oral cavity cancer and the association of occult metastasis with different subsites were evaluated in this study.

II. Materials and Methods

This retrospective study included patients who were treated at the Department of Oral and Maxillofacial Surgery, Kyungpook National University School of Dentistry, Daegu, South Korea, from January 2013 to August 2017. The institutional review board of Kyungpook National University Hospital approved this study, and each patient signed an informed consent agreement (KNUH_06-1003).

The inclusion criteria were: (1) Patients between 18 and 75 years of age who had histopathologically proven invasive OSCC that met the staging criteria of the American Joint Committee on Cancer (AJCC)²⁹ 7th edition and who had undergone neck dissection at the time of primary tumor resection. (2) Patients who had no history of head and neck cancer treatment.

Primary tumor size and location and lymph node involvement were evaluated through a physical examination, CT scan, MRI and PET-CT scan. Primary tumors were resected with a safety margin greater than 1 cm. Either supraomohyoid neck dissection (SOHND; level I, II, III) or mRND (level I, II, III, IV, V) was performed, depending on neck involvement and tumor size.

Postoperatively, a specimen was sent for biopsy for evaluation of the resection margins or any invasion of the extracapsular lymph nodes. The biopsy specimens were clearly labeled with neck levels and sublevels of dissection and were then immersed in 10% buffered formalin and sent for examination. The clinical N0 or N+ status based on TNM staging (AJCC 7th edition²⁹) and pathological pN0 or pN+ status were determined from the postoperative biopsy results. The predictor variables were oral cavity subsite, clinicopathological characteristics, T stage, primary tumor recurrence, and loco-regional nodal metastasis.

Adjuvant radiotherapy was performed in patients who had positive nodes, whose depth of invasion was greater than 10 mm, or whose safety margins were less than 4 mm. Radiotherapy was initiated within 4 to 8 weeks after surgery if necessary, according to the patient's condition. A total dose of 60 to 70 Gy was delivered in 2 Gy per fraction.

The primary outcome variable was presence of occult metastasis. The secondary outcome variables were the relation between neck node metastasis and T stage and the relation between neck node metastasis and distant metastasis. Patients were followed once every 4 weeks for the first 6 months and every 6 weeks for the next 6 months.

Fisher's exact test and the Cochran Armitage test were used to analyze the categorical dichotomized variables and relationships. All tests were performed with the R software package (R Foundation for Statistical Computing, Vienna, Austria) on a personal computer, and $P < 0.05$ was accepted as the level of statistical significance.

III. Results

In total, 76 patients (47 males, 29 females; mean age, 63.5 years) with OSCC who had no previous malignancies and were not undergoing neoadjuvant concomitant chemoradiotherapy or radiotherapy were selected for this analysis. (Table 1) The mean follow-up period was 12.2 months, and the median was 12 months. The findings of neck node metastasis were cN0 (n=52, 68.4%), cN+ (n=24, 31.6%), pN0 (n=59, 77.6%), and pN+ (n=17, 22.4%). (Table 2) The mandibular and maxillary posterior areas were the predominant subsites. (Fig. 1) All patients with clinically N0 or N+ neck were treated with neck dissection (SOHND, n=67; mRND, n=9). (Fig. 2) The T stages of the pN0 necks were T1, n=29; T2, n=16; T3, n=6; T4a, n=7; and T4b, n=1. In the pN+ necks, the tumor sizes were distributed as follows: T1, n=3; T2, n=7; T3, n=0; T4a, n=6; and T4b, n=1. (Table 3, Fig. 3) Based on the

Table 1. Basic demographic data and treatments of the patients

Characteristic	Total (n=76)	Clinical		Pathological	
		cN0 (n=52)	cN+ (n=24)	pN0 (n=59)	pN+ (n=17)
Age (yr)	63.5 (22-87)	63.2	64.3	63.6	64.1
Sex					
Male	47	32	15	35	12
Female	29	20	9	24	5
Subsite					
Maxillary posterior area	15	8	7	10	3
Mandibular posterior area	18	14	4	16	3
Floor of mouth	12	9	3	8	1
Tongue	15	8	7	10	3
Mandibular anterior area	5	5	0	5	3
Buccal mucosa	11	8	3	10	4
Type of neck dissection					
SOHND	67	50	17	56	11
mRND	9	2	7	3	6
Histology					
Well-differentiated	49	34	15	37	12
Moderately differentiated	27	18	9	22	5

(SOHND: supraomohyoid neck dissection, mRND: modified radical neck dissection)

Values are presented as mean (range), mean only, or number only.

Aditi Sharma et al: Clinical analysis of neck node metastasis in oral cavity cancer. J Korean Assoc Oral Maxillofac Surg 2018

Table 2. Correlations between clinical and pathological neck nodes

Clinical	Pathological		Total
	pN0	pN+	
cN0	44	8	52
cN+	15	9	24
Total	59	17	

Values are presented as number of patients.

Aditi Sharma et al: Clinical analysis of neck node metastasis in oral cavity cancer. J Korean Assoc Oral Maxillofac Surg 2018

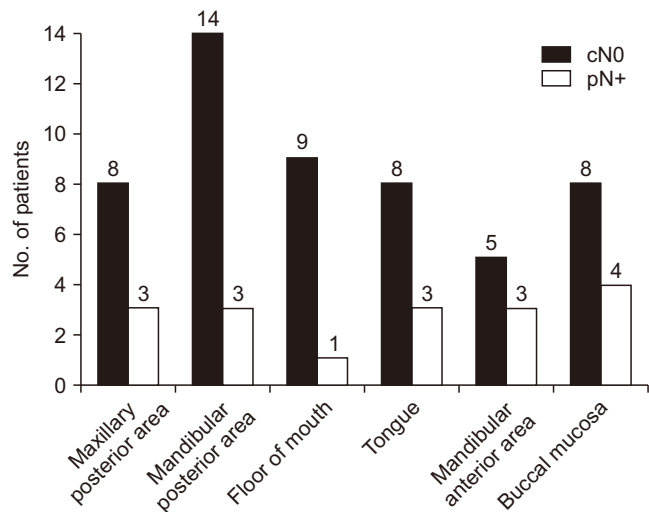


Fig. 1. Occult metastasis in relation to oral subsites.

Aditi Sharma et al: Clinical analysis of neck node metastasis in oral cavity cancer. J Korean Assoc Oral Maxillofac Surg 2018

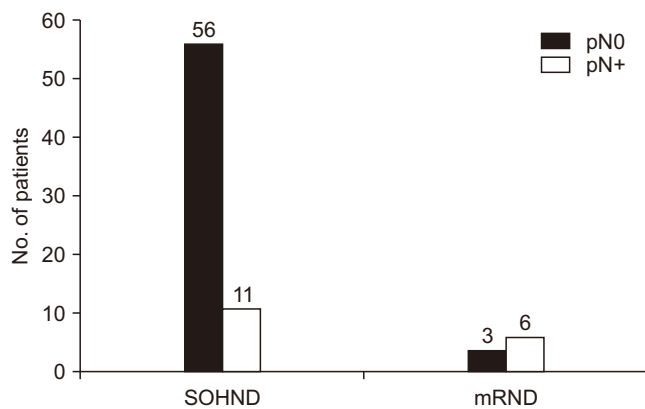


Fig. 2. Type of neck dissection. (SOHND: supraomohyoid neck dissection, mRND: modified radical neck dissection)

Aditi Sharma et al: Clinical analysis of neck node metastasis in oral cavity cancer. J Korean Assoc Oral Maxillofac Surg 2018

Table 3. Relation between neck node metastasis and T stage

	T1	T2	T3	T4	Total
pN0	29	16	6	8	59
pN+	3	7	0	7	17
Total	32	23	6	15	76

Values are presented as number of patients.

Cochrane Armitage trend test, P=0.014.

Aditi Sharma et al: Clinical analysis of neck node metastasis in oral cavity cancer. J Korean Assoc Oral Maxillofac Surg 2018

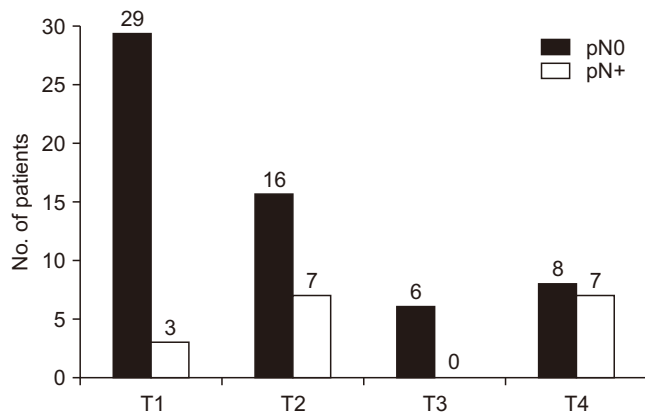


Fig. 3. Tumor size (the American Joint Committee on Cancer [AJCC] classification³²).

Aditi Sharma et al: Clinical analysis of neck node metastasis in oral cavity cancer. J Korean Assoc Oral Maxillofac Surg 2018

AJCC 7th edition²⁹ TNM classification, pN0 (pathologically negative lymph nodes) was noted in 29 patients in Stage I, 4 patients in Stage II, 12 patients in Stage III, and 14 patients in Stage IV (12 patients in IVa and 2 patient in IVb), while pN+ (with pathologically positive lymph nodes) was found in 5 patients in Stage I, 5 patients in Stage III, and 7 patients in Stage IV (6 patients in IVa and 1 patient in IVb). (Fig. 4)

Occult metastases were found in 8 of the 52 cN0 patients

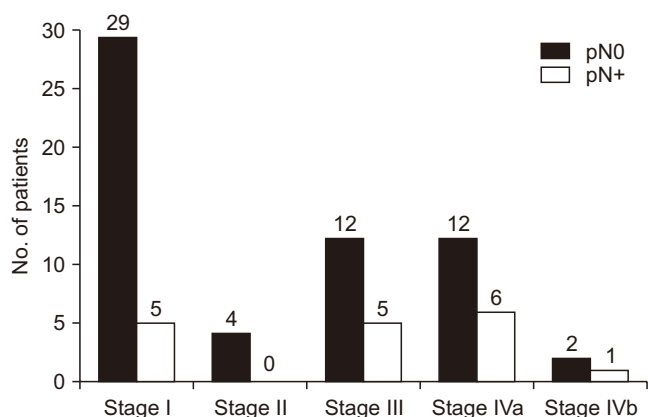


Fig. 4. Clinical staging of oral squamous cell carcinoma size. Aditi Sharma et al: Clinical analysis of neck node metastasis in oral cavity cancer. J Korean Assoc Oral Maxillofac Surg 2018

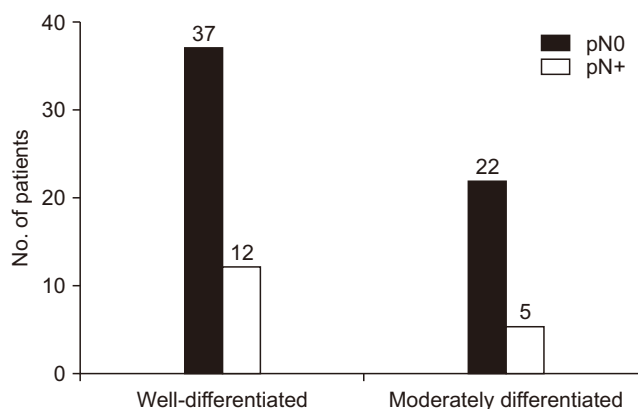


Fig. 5. Histological classification of oral squamous cell carcinoma. Aditi Sharma et al: Clinical analysis of neck node metastasis in oral cavity cancer. J Korean Assoc Oral Maxillofac Surg 2018

Table 4. Occult metastasis in 8 patients

Patient no.	Sex	Age (yr)	Subsite	cT	Type of neck dissection
1	Male	66	Mandibular anterior area	1	SOHND
2	Male	54	Floor of mouth	1	SOHND
3	Male	59	Tongue	2	SOHND
4	Female	36	Mandibular posterior area	4a	SOHND
5	Female	47	Tongue	1	SOHND
6	Female	77	Mandibular posterior area	1	SOHND
7	Male	57	Buccal mucosa	4b	mRND
8	Male	63	Mandibular posterior area	4a	SOHND

(SOHND: supraomohyoid neck dissection, mRND: modified radical neck dissection)

Aditi Sharma et al: Clinical analysis of neck node metastasis in oral cavity cancer. J Korean Assoc Oral Maxillofac Surg 2018

(15.4%). Neck node metastases were found in 17 patients (22.4%).(Table 4) We found no distant metastases in pN0 necks, while 4 of the 17 pN+ patients had distant metastases. Regional LN metastases were found in one N0 neck and one N+ neck. Histopathological differentiation did not reveal any characteristics related to pathological lymph node metastasis (χ^2 test, $P>0.05$). (Fig. 5) However, there was a statistically significant relationship between neck node metastasis and T stage (Cochrane Armitage trend test, $P=0.014$). (Table 3) Neck node metastasis and distant metastasis were also significantly related (Fisher’s exact test, $P=0.019$). (Table 5)

IV. Discussion

According to a meta-analysis of four well-designed prospective randomized controlled trials in oral cavity cancer patients, END significantly reduced the disease-specific death rates of OSCC patients with N0 neck³⁰. The incidence of occult metastasis ranged from 6% to 30% in the END

Table 5. Relation between neck node metastasis and distant metastasis

Distant metastasis	Pathological	
	pN0	pN+
-	59	13
+	0	4

Values are presented as number of patients.

Fisher’s exact test, $P=0.019$.

Aditi Sharma et al: Clinical analysis of neck node metastasis in oral cavity cancer. J Korean Assoc Oral Maxillofac Surg 2018

group and from 37% to 58% in the observation group²⁵. The reduced incidence of occult metastasis in the END group was most likely due to removal of fibro-fatty tissue in this group. In the present study, histopathological diagnosis revealed occult metastasis in 8 patients (15.4%). Our results were similar to those of Shimamoto et al.³¹, who found a 17.0% rate of cervical node metastasis; however, higher rates of occult metastasis have been found in other studies^{12,26,27,32}. The tongue and mandibular posterior area were found to be common subsites associated with occult metastasis. This finding is in accordance with the findings of Byers et al.⁵, who reported that the tongue was the predominant site for occult metastasis.

In various studies, END has been found to improve the regional control rate^{12,26,27}. Observation of the neck tends to be associated with a greater number of regional recurrences³³ and poor prognosis³⁴. Small tumors (early stage) are potentially aggressive, and the incidence of nodal metastasis is high³⁰. Weiss et al.³⁵ suggested guidelines for N0 OSCC, recommending END if the probability of occult cervical lymph node metastasis is greater than 20%. However, Okura et al.³⁶ concluded that END should be recommended if the probability of occult metastasis is higher than 44.4%. The probability of occult metastasis has been reduced due to improvement

of radiological and treatment modalities. In our study, 15 of 24 clinically cN+ patients were found to be pathologically pN0 after the operation. Sentinel node biopsies were not performed in this study, and the discussion regarding this is beyond the scope of this article. The advantages of SOHND compared with mRND as a therapeutic procedure remain controversial due to a lack of prospective studies.

The most common subsites of oral cavity cancer are the tongue and floor of the mouth^{37,38}. Tongue cancer metastasizes more often than floor-of-the-mouth cancer^{38,39}. In addition, these two subunits have a tendency to spread to the contralateral side¹². In our study, the maxillary and mandibular posterior areas were found to be more common subsites than the tongue and floor of the mouth. The mandibular anterior area and buccal mucosa were predominant subsites for occult metastasis.

Nodal metastases may be missed in histological sections. Yuen et al.¹² detected nodal recurrence in 37% of patients in the observation neck group. The authors concluded that selective neck dissection alone is an adequate treatment for oral cancer patients with N0 neck, even though nodal micro-metastasis might be missed histopathologically. In patients with N+ neck, selective neck dissection and radiotherapy have been advised for better nodal control. Most studies have failed to demonstrate that survival outcomes differ significantly between the END group and the observation group^{40,41}. Even fewer studies have demonstrated the significance of END in OSCC patients with clinically N0 neck⁴².

The major advantage of END in clinically N0 neck patients is that its surgical morbidity is lower than that of mRND for patients with nodal recurrence in the observation group. Most patients in the observation group will need mRND and will thus have greater chances of surgical morbidity. On the other hand, the disadvantage of END is that 70% of N0 neck patients will undergo unnecessary neck dissections, incurring additional costs and surgical morbidity. The advantage of observation is that only 30% to 40% of patients report nodal metastasis requiring neck treatment. The major disadvantage of observation is that patients may need radical or modified neck dissection, which have reduced survival rates.

When metastasis occurs, close follow-up is a major determinant of survival outcome and nodal recurrence irrespective of the choice of treatment for N0 neck¹². Kligerman et al.³² demonstrated that the survival rate was lower (low salvage rate) and the nodal recurrence rate was 27% in observed necks, while END was beneficial in terms of survival outcome in clinically N0 necks. Vandembrouck et al.²⁶ reported

a high salvage rate (around 84%), so the survival outcomes of END were not found to differ significantly from those of observation.

Kuntz and Weymuller⁴² noted that shoulder disabilities at 6 months were more common with mRND than with SOHND. Rastogi et al.⁴³ found statistically significant differences between super-selective neck dissection (level I, IIa, III) and selective neck dissection (level I, IIa, IIb, III) groups, including less shoulder morbidity and a better quality of life in the super-selective neck dissection group. Giordano et al.⁴⁴ reported that sublevel IIb dissection impaired nerve conduction and reduced the quality of life in OSCC patients. Therefore, clinical, radiological, and histopathological evaluations should play a major role in the decision to involve level IIb in neck dissection. Positive nodal metastasis in sublevel IIa strongly signifies an association of nodal metastasis of sublevel IIb⁴⁵. Still, there is no clear indication for neck dissection in cN0 necks. However, neck dissection in cN0 necks has been shown to be better than observation^{25-27,32}.

The limitation of our study is its retrospective nature. Nevertheless, we found a statistically significant relationship between neck node metastasis and T stage ($P=0.014$) and between neck node metastasis and distant metastasis ($P=0.019$).

V. Conclusion

Our results revealed occult metastasis in 15.4% of the final surgical neck node specimens, a relatively low percentage compared with those of other studies^{12,26,27,32}. Neck node metastasis was significantly related to tumor size and distant metastasis during follow-up. Therefore, additional well-designed prospective randomized controlled trials are required to determine the appropriate treatment modalities for N0 necks.

ORCID

Aditi Sharma, <https://orcid.org/0000-0002-5948-4818>

Jin-Wook Kim, <https://orcid.org/0000-0003-4074-877X>

Jun-Young Paeng, <https://orcid.org/0000-0002-0104-9338>

Authors' Contributions

A.S. participated in data collection and wrote the manuscript. J.W.K. participated in patients operation. J.Y.P. participated in the study design and revised the manuscript.

Ethics Approval and Consent to Participate

The institutional review board of Kyungpook National University Hospital approved this study, and each patient signed an informed consent agreement (KNUH_06-1003).

Conflict of Interest

No potential conflict of interest relevant to this article was reported.

References

- Jemal A, Bray F, Center MM, Ferlay J, Ward E, Forman D. Global cancer statistics. *CA Cancer J Clin* 2011;61:69-90.
- Ren ZH, Wu HJ, Wang K, Zhang S, Tan HY, Gong ZJ. Anterolateral thigh myocutaneous flaps as the preferred flaps for reconstruction of oral and maxillofacial defects. *J Craniomaxillofac Surg* 2014;42:1583-9.
- Ren ZH, Wu HJ, Tan HY, Wang K, Zhang S. Transfer of anterolateral thigh flaps in elderly oral cancer patients: complications in oral and maxillofacial reconstruction. *J Oral Maxillofac Surg* 2015;73:534-40.
- Ren ZH, Xu JL, Fan TF, Ji T, Wu HJ, Zhang CP. The harmonic scalpel versus conventional hemostasis for neck dissection: a meta-analysis of the randomized controlled trials. *PLoS One* 2015;10:e0132476.
- Byers RM, El-Naggar AK, Lee YY, Rao B, Fornage B, Terry NH, et al. Can we detect or predict the presence of occult nodal metastases in patients with squamous carcinoma of the oral tongue? *Head Neck* 1998;20:138-44.
- Po Wing Yuen A, Lam KY, Lam LK, Ho CM, Wong A, Chow TL, et al. Prognostic factors of clinically stage I and II oral tongue carcinoma—a comparative study of stage, thickness, shape, growth pattern, invasive front malignancy grading, Martinez-Gimeno score, and pathologic features. *Head Neck* 2002;24:513-20.
- Woolgar JA, Triantafyllou A, Lewis JS Jr, Hunt J, Williams MD, Takes RP, et al. Prognostic biological features in neck dissection specimens. *Eur Arch Otorhinolaryngol* 2013;270:1581-92.
- Haddadin KJ, Soutar DS, Oliver RJ, Webster MH, Robertson AG, MacDonald DG. Improved survival for patients with clinically T1/T2, N0 tongue tumors undergoing a prophylactic neck dissection. *Head Neck* 1999;21:517-25.
- Lydiatt DD, Robbins KT, Byers RM, Wolf PF. Treatment of stage I and II oral tongue cancer. *Head Neck* 1993;15:308-12.
- Yuen AP, Wei WI, Wong YM, Tang KC. Elective neck dissection versus observation in the treatment of early oral tongue carcinoma. *Head Neck* 1997;19:583-8.
- Keski-Säntti H, Atula T, Törnwall J, Koivunen P, Mäkitie A. Elective neck treatment versus observation in patients with T1/T2 N0 squamous cell carcinoma of oral tongue. *Oral Oncol* 2006;42:96-101.
- Yuen AP, Ho CM, Chow TL, Tang LC, Cheung WY, Ng RW, et al. Prospective randomized study of selective neck dissection versus observation for N0 neck of early tongue carcinoma. *Head Neck* 2009;31:765-72.
- Capote A, Escorial V, Muñoz-Guerra MF, Rodríguez-Campo FJ, Gamallo C, Naval L. Elective neck dissection in early-stage oral squamous cell carcinoma—does it influence recurrence and survival? *Head Neck* 2007;29:3-11.
- Huang SF, Chang JT, Liao CT, Kang CJ, Lin CY, Fan KH, et al. The role of elective neck dissection in early stage buccal cancer. *Laryngoscope* 2015;125:128-33.
- Kirita T, Omura K. Oral cancer: diagnosis and therapy. Tokyo: Springer; 2015:221-30.
- Mamelle G, Pampurik J, Luboinski B, Lancar R, Lusinci A, Bosq J. Lymph node prognostic factors in head and neck squamous cell carcinomas. *Am J Surg* 1994;168:494-8.
- León X, Quer M, Orús C, del Prado Venegas M, López M. Distant metastases in head and neck cancer patients who achieved loco-regional control. *Head Neck* 2000;22:680-6.
- Lim JY, Lim YC, Kim SH, Kim JW, Jeong HM, Choi EC. Predictive factors of isolated distant metastasis after primary definitive surgery without systemic treatment for head and neck squamous cell carcinoma. *Oral Oncol* 2010;46:504-8.
- Garavello W, Ciardo A, Spreafico R, Gaini RM. Risk factors for distant metastases in head and neck squamous cell carcinoma. *Arch Otolaryngol Head Neck Surg* 2006;132:762-6.
- Liao CT, Wang HM, Chang JT, Ng SH, Hsueh C, Lee LY, et al. Analysis of risk factors for distant metastases in squamous cell carcinoma of the oral cavity. *Cancer* 2007;110:1501-8.
- Reinisch S, Kruse A, Bredell M, Lübbers HT, Gander T, Lanzer M. Is lymph-node ratio a superior predictor than lymph node status for recurrence-free and overall survival in patients with head and neck squamous cell carcinoma? *Ann Surg Oncol* 2014;21:1912-8.
- Prabhu RS, Hanasoge S, Magliocca KR, Hall WA, Chen SA, Higgins KA, et al. Lymph node ratio influence on risk of head and neck cancer locoregional recurrence after initial surgical resection: implications for adjuvant therapy. *Head Neck* 2015;37:777-82.
- Gil Z, Carlson DL, Boyle JO, Kraus DH, Shah JP, Shaha AR, et al. Lymph node density is a significant predictor of outcome in patients with oral cancer. *Cancer* 2009;115:5700-10.
- Guo CB, Feng Z, Zhang JG, Peng X, Cai ZG, Mao C, et al. Supraomohyoid neck dissection and modified radical neck dissection for clinically node-negative oral squamous cell carcinoma: a prospective study of prognosis, complications and quality of life. *J Craniomaxillofac Surg* 2014;42:1885-90.
- Fasanla AJ, Greene BH, Timmesfeld N, Wiegand S, Werner JA, Sesterhenn AM. A meta-analysis of the randomized controlled trials on elective neck dissection versus therapeutic neck dissection in oral cavity cancers with clinically node-negative neck. *Oral Oncol* 2011;47:320-4.
- Vandenbrouck C, Sancho-Garnier H, Chassagne D, Saravane D, Cachin Y, Micheau C. Elective versus therapeutic radical neck dissection in epidermoid carcinoma of the oral cavity: results of a randomized clinical trial. *Cancer* 1980;46:386-90.
- Fakih AR, Rao RS, Borges AM, Patel AR. Elective versus therapeutic neck dissection in early carcinoma of the oral tongue. *Am J Surg* 1989;158:309-13.
- Bryne M. Prognostic value of various molecular and cellular features in oral squamous cell carcinomas: a review. *J Oral Pathol Med* 1991;20:413-20.
- Edge SB, Compton CC. The American Joint Committee on Cancer: the 7th edition of the AJCC cancer staging manual and the future of TNM. *Ann Surg Oncol* 2010;17:1471-4.
- Silverberg E. Cancer statistics. 1986. *CA Cancer J Clin* 1986;36:9-25.
- Shimamoto H, Oikawa Y, Osako T, Hirai H, Mochizuki Y, Tanaka K, et al. Neck failure after elective neck dissection in patients with oral squamous cell carcinoma. *Oral Surg Oral Med Oral Pathol Oral Radiol* 2017;124:32-6.
- Kligerman J, Lima RA, Soares JR, Prado L, Dias FL, Freitas EQ, et al. Supraomohyoid neck dissection in the treatment of T1/T2 squamous cell carcinoma of oral cavity. *Am J Surg* 1994;168:391-4.
- Kowalski LP. Results of salvage treatment of the neck in patients with oral cancer. *Arch Otolaryngol Head Neck Surg* 2002;128:58-62.

34. Byers RM, Weber RS, Andrews T, McGill D, Kare R, Wolf P. Frequency and therapeutic implications of "skip metastases" in the neck from squamous carcinoma of the oral tongue. *Head Neck* 1997;19:14-9.
35. Weiss MH, Harrison LB, Isaacs RS. Use of decision analysis in planning a management strategy for the stage N0 neck. *Arch Otolaryngol Head Neck Surg* 1994;120:699-702.
36. Okura M, Aikawa T, Sawai NY, Iida S, Kogo M. Decision analysis and treatment threshold in a management for the N0 neck of the oral cavity carcinoma. *Oral Oncol* 2009;45:908-11.
37. Dias FL, Lima RA, Kligerman J, Farias TP, Soares JR, Manfro G, Sa GM. Relevance of skip metastases for squamous cell carcinoma of the oral tongue and the floor of the mouth. *Otolaryngol Head Neck Surg* 2006;134:460-5.
38. Jerjes W, Upile T, Petrie A, Riskalla A, Hamdoon Z, Vourvachis M, et al. Clinicopathological parameters, recurrence, locoregional and distant metastasis in 115 T1-T2 oral squamous cell carcinoma patients. *Head Neck Oncol* 2010;2:9.
39. Duvvuri U, Simental AA Jr, D'Angelo G, Johnson JT, Ferris RL, Gooding W, et al. Elective neck dissection and survival in patients with squamous cell carcinoma of the oral cavity and oropharynx. *Laryngoscope* 2004;114:2228-34.
40. Dias FL, Kligerman J, Matos de Sá G, Arcuri RA, Freitas EQ, Farias T, et al. Elective neck dissection versus observation in stage I squamous cell carcinomas of the tongue and floor of the mouth. *Otolaryngol Head Neck Surg* 2001;125:23-9.
41. Marchioni DL, Fisberg RM, do Rosário M, Latorre DO, Wunsch V. Diet and cancer of the oral cavity and pharynx: a case-control study in São Paulo, Brazil. *IARC Sci Publ* 2002;156:559-61.
42. Kuntz AL, Weymuller EA Jr. Impact of neck dissection on quality of life. *Laryngoscope* 1999;109:1334-8.
43. Rastogi S, Sharma A, Choudhury R, Tripathi S, Al Wayli H, Amrithraj A, et al. Is superselective neck dissection safer than supraomohyoid neck dissection for oral carcinoma patients with N0 neck in terms of shoulder morbidity and recurrence rate? *J Oral Maxillofac Surg* 2018;76:647-55.
44. Giordano L, Sarandria D, Fabiano B, Del Carro U, Bussi M. Shoulder function after selective and superselective neck dissections: clinical and functional outcomes. *Acta Otorhinolaryngol Ital* 2012;32:376-9.
45. Mashberg A, Meyers H. Anatomical site and size of 222 early asymptomatic oral squamous cell carcinomas: a continuing prospective study of oral cancer. II. *Cancer* 1976;37:2149-57.