



Lip repositioning with or without myotomy: a systematic review

Mohammadreza Talebi Ardakani¹, Anahita Moscowchi¹, Nasrin Keshavarz Valian¹, Elham Zakerzadeh²

¹Department of Periodontics, School of Dentistry, Shahid Beheshti University of Medical Sciences, Tehran,

²Private Practice, Tehran, Iran

Abstract (J Korean Assoc Oral Maxillofac Surg 2021;47:3-14)

Excessive gingival display is an esthetic issue that is commonly managed by different procedures. Lip repositioning is a modality to address concerns of affected patients. The aim of this review was to investigate the scientific evidence on outcomes and long-term stability of lip repositioning surgery with or without myotomy. The electronic search was conducted in three databases: MEDLINE, Embase, and the Cochrane Library up to October 2019. No publication status, language, or time restrictions were applied. The electronic search was complemented by a manual search of the reference lists. Three hundred thirty-eight studies were screened by title, and 16 articles remained for data extraction. The included studies assessed the lip repositioning procedure in 144 patients aged between 15-59 years (134 females and 10 males). Based on the available data, lip repositioning with myotomy/muscle containment can be a successful treatment for minor discrepancies in gingival display in selected cases. However, further well-organized controlled clinical trials are recommended to derive a conclusion about the long-term stability compared with other alternatives.

Key words: Esthetics, Gingiva, Lip, Dental

[paper submitted 2020. 6. 7 / revised 2020. 8. 22 / accepted 2020. 11. 2]

I. Introduction

The increasing demand for an attractive smile in the last 40 years has resulted in development of various techniques to respond to patient concerns. Some individuals exhibit excessive gingival display (EGD), which is reported in 7% of in males and 14% of in females, and can impose esthetic issues¹. EGD can be classified into four distinct types: continuous band of EGD (type 1), which is the most common type; excessive display of the posterior gingiva (type 2); unilateral (type 3); and EGD in the anterior area (type 4)². In addition to a high smile line, which is prevalent among 10.57% to 38.9% of individuals^{1,3}, factors including delayed tooth eruption or excessive tooth coverage with gingival tissue, inadequate up-

per lip movement, upper lip length, and skeletal issues can contribute to this condition⁴.

In general, the underlying etiology of a gummy smile dictates the primary treatment approach. Such techniques include crown lengthening procedures⁵, orthodontic leveling of the gingival margins⁶, maxillary tooth intrusion⁷, lip repositioning⁸, orthognathic surgery⁹, and nonsurgical procedures such as administration of botulinum toxin A¹⁰.

Rubinstein and Kostianovsky¹¹ in 1973 described lip repositioning surgery without muscular intervention. This technique is conducted to limit retraction of the upper lip elevator muscles through removal of a strip of mucosa from the maxillary buccal vestibule. More aggressive procedures to increase predictability have been reported with short-term follow-up periods including detachment of labial muscles¹², applying a silicone spacer¹³, lip elongation with rhinoplasty¹⁴, and myotomy of the levator labii superioris along with frenectomy⁸. However, these techniques are not indicated in all cases suffering from gummy smile. Contraindications consist of severe vertical maxillary excess (>8 mm) and the presence of a minimal zone of attached gingiva, which can create difficulties in flap design, stabilization, and suturing¹⁵.

Regardless of its gain in popularity, lip repositioning procedures are mainly based on case reports and case series and do

Anahita Moscowchi

Department of Periodontics, School of Dentistry, Shahid Beheshti University of Medical Sciences, Daneshjoo Blvd, Evin, Shahid Chamran Highway, Tehran 1983963113, Iran

TEL: +98-21-299-02314

E-mail: a.moscowchi@gmail.com

ORCID: <https://orcid.org/0000-0003-1327-5014>

© This is an open-access article distributed under the terms of the Creative Commons Attribution Non-Commercial License (<http://creativecommons.org/licenses/by-nc/4.0/>), which permits unrestricted non-commercial use, distribution, and reproduction in any medium, provided the original work is properly cited.

Copyright © 2021 The Korean Association of Oral and Maxillofacial Surgeons. All rights reserved.

not seem to address any points beyond short-term improved outcomes. Furthermore, there has been greater emphasis on the importance of myotomy for long-term stability. Therefore, the aim of this study was to evaluate the available scientific evidence regarding the outcomes and long-term stability of lip repositioning surgery with or without myotomy.

II. Methods

A detailed protocol was developed and followed according to the PRISMA (Preferred Reporting Items for Systematic Reviews and Meta-Analyses) statement¹⁶.

1. Focused questions

PICO question (Participant, Intervention, Comparison, and Outcome):

- (1) Participants (P): Patients with EGD
- (2) Intervention (I): Lip repositioning surgery along with myotomy or muscle containment
- (3) Comparison (C): Lip repositioning surgery alone
- (4) Outcomes (O): Amount of improvement in gingival display and stability of the results

The literature was reviewed to answer the following questions:

- (1) Does lip repositioning improve esthetics?
- (2) Are the results achieved by these techniques stable?

(3) Is there any difference among the various techniques?

2. Search strategy

Two researchers (A.M. and N.K.V.) searched MEDLINE (through PubMed), Embase, and the Cochrane Library (including the Cochrane Central Register of Controlled Trials [CENTRAL]) up to October 2019. The search term ‘lip repositioning’ was utilized to retrieve all relevant studies. We did not limit our search strategy regarding study design, as doing so could have excluded pertinent publications¹⁷. No publication status, language, or time restrictions were applied. The electronic search was complemented by a manual search of the reference lists of all relevant articles.

3. Inclusion criteria

Clinical trials including case series and case reports were considered for inclusion. The Cochrane risk of bias tool for randomized trials¹⁸ and MINORS (methodological index for nonrandomized studies) were used¹⁹ to assess the quality of the studies included in this review.

4. Exclusion criteria

Studies with the following criteria were excluded from the final assessment:

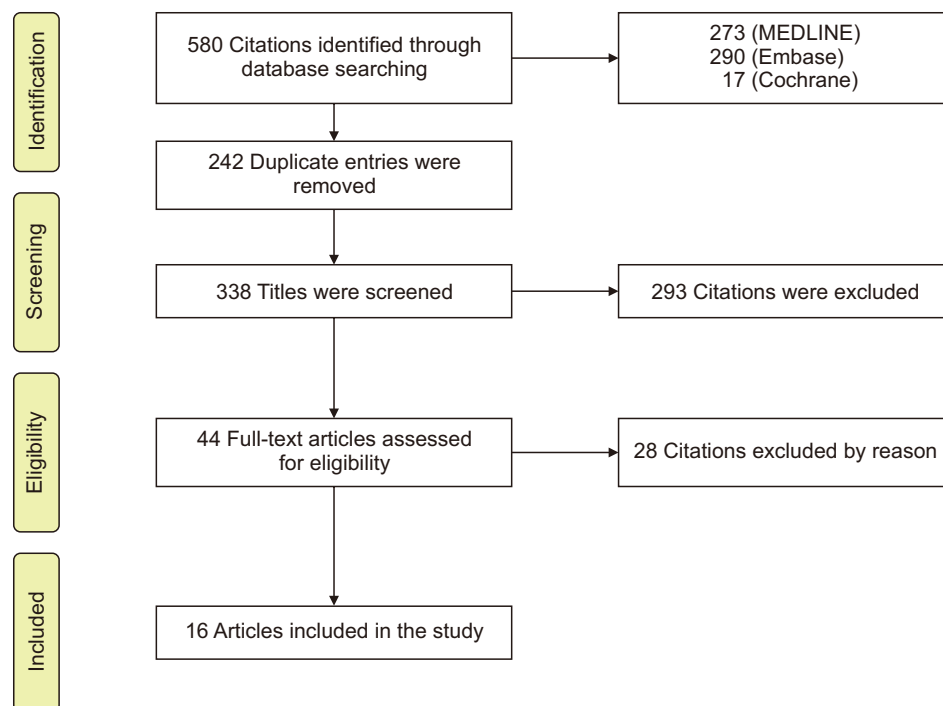


Fig. 1. Flowchart of the study selection process.
 Mohammadreza Talebi Ardakani et al: Lip repositioning with or without myotomy: a systematic review.
 J Korean Assoc Oral Maxillofac Surg 2021

- (1) Follow-up duration less than 6 months
 (2) Lack of data on preoperative and/or postoperative measurements

5. Study selection and data synthesis

Two authors (M.T.A. and A.M.) independently screened the titles and abstracts based on the inclusion criteria. Full-text articles were obtained in case supplementary data were needed. The extracted data included patient information, preoperative and postoperative gingival display in millimeters at maximum smile, surgical technique, EGD etiology, follow-up period, and complications. Any disagreements during the process were resolved by discussion.

6. Statistical analysis

Standard methods were used to obtain the estimated overall effect size and the corresponding forest plot. All calculations were carried out using Comprehensive Meta-Analysis 2.2.064.

III. Results

The initial search yielded 580 articles: 273 articles through PubMed, 290 through Embase, and 17 articles through the Cochrane Library. (Fig. 1) Manual search resulted in no additional articles. Three hundred thirty-eight studies were screened by title (after elimination of duplicate entries) and 44 articles were considered for full-text assessment. Excluding 28 articles (Table 1)^{15,20-46}, 16 studies remained for data extraction. (Fig. 1) Table 2^{8,47-61} shows the data extracted from these remaining studies.

The risk of bias assessment for non-comparative studies is presented in Table 3^{8,47,48,50,52-61}. The risk of bias for one non-randomized comparative study⁵¹ was estimated at 23 (of 24) based on the MINORS scoring criteria. The only randomized clinical trial⁴⁹ was evaluated as “low risk” of bias based on the Cochrane risk of bias tool for randomized trials.

The included studies assessed lip repositioning procedures in 144 patients aged between 15-59 years (134 females and 10 males, not reported in one study with 14 patients⁵⁰). The most prevalent reported etiology was hypermobile upper lip^{47,48,50-53,55-57,59,60}, followed by altered passive erup-

Table 1. Articles excluded following full-text assessment

Study	Follow-up less than 6 months	Lack of data on preoperative and/or postoperative measurements	Lack of data on etiology	Conflicting data	Study design	No surgical intervention
Ramesh et al. ²⁰ (2019)		*				
Foudah ²¹ (2019)		*				
K et al. ²² (2018)		*	*			
Faus-Matoses et al. ²³ (2018)	*	*				
Sharma et al. ²⁴ (2017)	*		*			
Sánchez et al. ²⁵ (2017)	*					
Littuma et al. ²⁶ (2017)		*				
Khan et al. ²⁷ (2017)		*				
Gibson and Tatakis ²⁸ (2017)		*				
Farista et al. ²⁹ (2017)		*				
Mahn ³⁰ (2016)		*				
Aly and Hammouda ³¹ (2016)	*					
Rao et al. ³² (2015)	*					
Muthukumar et al. ³³ (2015)		*	*			
Bhola et al. ³⁴ (2015)		*				
Storrer et al. ³⁵ (2014)		*	*			
Grover et al. ³⁶ (2014)		*				
Gaddale et al. ³⁷ (2014)		*				
Sheth et al. ³⁸ (2013)	*					
Humayun et al. ³⁹ (2010)		*				
Gupta et al. ⁴⁰ (2010)		*	*			
Simon et al. ¹⁵ (2007)		*				
Rosenblatt and Simon ⁴¹ (2006)		*	*			
Ambrosio et al. ⁴² (2018)				*		
Assenza et al. ⁴³ (2011)				*		
Ergezen et al. ⁴⁴ (2017)					*	
Mangano and Mangano ⁴⁵ (2013)						*
Polo ⁴⁶ (2011)						*

Mohammadreza Talebi Ardakani et al: Lip repositioning with or without myotomy: a systematic review. J Korean Assoc Oral Maxillofac Surg 2021

Table 2. Characteristics of the included studies

Study	Study design	No. of patients	Sex	Age (yr)	Etiology	Surgical technique	Additional intervention	Follow-up duration (mo)	Preoperative display (mm)	Postoperative display (mm)	Complications
Ganesh et al. ⁴⁷ (2019)	Case report	1	F	25	1. APE 2. HUL	Type of instrument: diode laser (940 nm), 400 µm laser tip/continuous mode at 0.8 W Lower incision: MGJ Upper incision: 10 mm Type of incision: partial thickness MD extension: maxillary premolar Suturing: resorbable (muscle containment)/4-0 silk interrupted Removed after 14 days	1. Muscle containment 2. Crown lengthening: laser gingivectomy	12	7	3	1. Mild pain and tension 1st week 2. Minor scar
Torabi et al. ⁴⁸ (2018)	Case report	3	2 F 1 M	41-54	1. VME 2. HUL 3. APE	Type of instrument: blade Lower incision: MGJ Upper incision: labial vestibule (periosteal fenestration) MD extension: maxillary 1st molar Suturing: 4-0 silk, 4-0 Vicryl/ suspensory triangular+extraoral stabilization tape	N/A	13-16	6.3±4.06	2 months: 0.96±0.73 6 months: 0.76±0.87 13-16 months: 0.72±0.96	N/A
Tawfik et al. ⁴⁹ (2018)	RCT	Group 1: 20 Group 2: 20	18 F 2 M	N/A	Various etiologies	Type of instrument: #15 blade Lower incision: MGJ Upper incision: 2x the display Type of incision: partial thickness MD extension: maxillary 1st molar Suturing: 5-0 polyglycolic sutures/ continuous & interrupted Removed after 14 days	Myotomy: Group 1	12	Group 1: 6.29±2.6 Group 2: 4.31±1.12	Group 1: 3 months: 3±1.53 6 months: 3.42±1.23 12 months: 3.57±1.62 Group 2: 3 months: 1.65±0.90 6 months: 2.21±1.0 12 months: 2.73±1.28	1. Pain 2. Swelling 3. Numbness
Alammar and Heshmeh ⁵⁰ (2018)	Case series	14	N/A	18-38	1. SUL 2. HUL	Type of instrument: blade Lower incision: 1 mm coronal to MGJ Upper incision: 10-12 mm Type of incision: full thickness MD extension: maxillary 1st molar Suturing: 4-0 Vicryl (muscle), 3-0 silk (mucosa)/interrupted sutures Removed after 14 days	1. Myotomy 2. Crown lengthening	6	6.36±1.12	1 month: 0.91±1.22 3 months: 2.27±1.27 6 months: 2.45±1.13	1. Scar 2. Tension in the upper lip 3. Minimal discomfort 4. Ecthymosis 5. Edema 6. Flap dehiscence 7. Numbness

Table 2. Continued

Study	Study design	No. of patients	Sex	Age (yr)	Etiology	Surgical technique	Additional intervention	Follow-up duration (mo)	Preoperative display (mm)	Postoperative display (mm)	Complications
Alammar et al. ⁵¹ (2018)	PCT	22	19 F 3 M	18-38	1. SUL 2. HUL (lip mobility >8 mm)	Type of instrument: blade Lower incision: 1 mm coronal to MGJ Upper incision: 10-12 mm Type of incision: partial thickness (Group 1) full thickness (Group 2) MD extension: maxillary 1st molar Suturing: 3-0 silk/interrupted (Group 1) 4-0 Vicryl (muscle), 3-0 silk (mucosa)/interrupted (Group 2) Removed after 14 days	1. Myotomy (Group 2) 2. Crown lengthening	6	5.82±0.87 (Group 1) 6.36±1.12 (Group 2)	Group 1: 1 month: 2.18±0.75 3 months: 2.55±0.93 6 months: 3.27±0.79 Group 2: 1 month: 0.91±1.22 3 months: 2.27±1.27 6 months: 2.45±1.13 2 mm midline 4 mm lateral incisors	1. Scar 2. Tension in the upper lip 3. Minimal discomfort 4. Ecchymosis 5. Edema 6. Flap dehiscence 7. Numbness
Storrier et al. ⁵² (2017)	Case report	1	F	23	HUL	Type of instrument: #15C blade Lower incision: MGJ Upper incision: N/A Type of incision: partial thickness MD extension: maxillary canines Suturing: 5-0 nylon/4-0 silk/interrupted external sutures removed after 10 days	1. Muscle containment 2. Frenectomy 3. Crown lengthening	24	8	2 mm midline 4 mm lateral incisors	Tension
Mantovani et al. ⁵³ (2016)	Case report	1	F	23	1. HUL 2. APE	Type of instrument: N/A Lower incision: 1 mm coronal to MGJ Upper incision: 10-12 mm Type of incision: partial thickness MD extension: maxillary 1st molars Suturing: 5-0 polygalactin/continuous interlocking sutures	Crown lengthening: 2 mm after lip repositioning	9	5	6 months: 0-1	N/A
Abdullah et al. ⁵⁴ (2014)	Case series	12	10 F 2 M	20-29	N/A	Type of instrument: blade Lower incision: 4-5 mm from gingival margin Upper incision: 8-10 mm Type of incision: full thickness MD extension: maxillary 2nd premolar Suturing: 3-0 Vicryl/interrupted Removed after 14 days	1. Myotomy 2. Frenectomy	12	5±0.95	1 month: 2.66±0.77 3 months: 3.08±1.16 6 months: 3.08±1.16 12 months: 3.08±1.16	1. Feeling of tension 2. Mild pain 3. Ecchymosis 4. Edema 5. Complete relapse in 1 patient after 3 months

Table 2. Continued

Study	Study design	No. of patients	Sex	Age (yr)	Etiology	Surgical technique	Additional intervention	Follow-up duration (mo)	Preoperative display (mm)	Postoperative display (mm)	Complications
Ozturan et al. ⁵⁵ (2014)	Case series	10	F	22-34	HUL	Type of instrument: diode laser (940 nm, 4 W, continuous wave) Lower incision: MGJ Upper incision: 10-12 mm Type of incision: partial thickness <i>Procedure was done in two stages left/right.</i> MD extension: maxillary 1st molars Suturing: 5-0 monofilament/continuous interlocking	N/A	12	4.3±1.8	6 months: 1.1±1.0 12 months: 1.2±1.5	N/A
Jananni et al. ⁵⁶ (2014)	Case report	1	F	18	1. VME 2. HUL	Type of instrument: blade #15 Lower incision: MGJ Upper incision: 2× the display Type of incision: partial thickness MD extension: maxillary 2nd premolars Suturing: 4-0 silk/continuous interlocking sutures/periodontal pack Removed after 14 days	N/A	18	6	4	N/A
Gabrić Pandurić et al. ⁵⁷ (2014)	Case report	1	F	27	1. VME 2. HUL 3. APE	Type of instrument: diode laser (975 µm, 4 W, CW) Lower incision: MGJ Upper incision: 1.5× display Type of incision: partial thickness MD extension: maxillary 1st molars Suturing: 3-0 silk/interrupted sutures Removed after 10 days	1. Frenectomy 2. Crown lengthening: laser gingivectomy	6	5.5-10	0-2	1. Tension 2. Slight pain 3. Numbness 1st week 4. Scar
Dayakar et al. ⁵⁸ (2014)	Case report	1	F	22	N/A	Type of instrument: blade Lower incision: MGJ Upper incision: 10-12 mm MD extension: maxillary 1st molars Suturing: continuous interlocking Removed after 14 days	N/A	12	5-6	3 months: 3 6 months: 3 12 months: complete relapse	1. Mild pain and tension 1st week 2. Scar
Silva et al. ⁵⁹ (2013)	PCT	13	11 F 2 M	19-49	HUL	Type of instrument: N/A Lower incision: 1 mm coronal to MGJ Upper incision: 10-12 mm Type of incision: partial thickness MD extension: maxillary 1st molar Suturing: 4-0 polygalactin/continuous interlocking sutures	N/A	6	4-10 (5.8±2.1)	3 months: 0-3 (1.4±1.0) 6 months: 0-5 (1.3±1.6)	1. Tension 2. Scar

Table 2. Continued

Study	Study design	No. of patients	Sex	Age (yr)	Etiology	Surgical technique	Additional intervention	Follow-up duration (mo)	Preoperative display (mm)	Postoperative display (mm)	Complications
Ribeiro-Júnior et al. ⁶⁰ (2013)	Case report	2	F	20-22	1. HUL 2. APE (1 patient)	Type of instrument: N/A Lower incision: 1 mm coronal to MGJ Upper incision: 10-12 mm Type of incision: partial thickness MD extension: maxillary 1st molars Suturing: 4-0 poligalactin/continuous interlocking sutures	Crown lengthening: 1 patient	6	7 6	1	1. Tension 1st week 2. Scar
Jacobs and Jacobs ⁶¹ (2013)	Case series	7	F	21-59	N/A	Removed after 14 days Type of instrument: diode laser/#15 blade Lower incision: MGJ Upper incision: 2x display Type of incision: partial thickness MD extension: maxillary 1st molars Suturing: 3-0 chromic or silk/interrupted or continuous interlocking sutures	N/A	1-36	5.36±1.5	1.1±2.5	1. Scar 2. Pain, swelling and tension 1st week
Ishida et al. ⁸ (2010)	Case series	14	F	15-35	N/A	Type of instrument: #15 blade Lower incision: N/A Upper incision: N/A Type of incision: N/A MD extension: N/A Suturing: 5-0 resorbable/interrupted	1. Myotomy 2. Frenectomy	6-18	5.22±1.48	6 months: 1.91±1.50	N/A

(F: female, M: male, APE: altered passive eruption, HUL: hypermobile upper lip, VME: vertical maxillary excess, SUL: short upper lip, MGJ: mucogingival junction, MD: mesiodistal, N/A: not available, RCT: randomized controlled trial, PCT: prospective clinical trial)

Mohammudreza Talebi Ardakani et al: Lip repositioning with or without myotomy: a systematic review. *J Korean Assoc Oral Maxillofac Surg* 2021

tion^{25,28,30,39,47,48,53,57,60}, vertical maxillary excess^{48,56,57}, and short upper lip^{50,51}.

All but two studies^{50,54} used a partial-thickness flap. However, one comparative study reported better results with a full-thickness approach⁵¹. Some authors used additional interventions including crown lengthening^{47,50-53,57,60} and frenectomy^{8,23,33,37,52,54,57} to achieve more favorable results with higher stability. Alammam et al.⁵¹ mentioned two cases with complete relapse in their conventional surgical group. In addition, Dayakar et al.⁵⁸ reported complete relapse after 12 months, but they did not report additional details.

Six studies provided sufficient data (sample size, mean, and either standard deviation or standard error) to contribute to estimation of the overall effect size for improvement after lip repositioning surgery.(Fig. 2) In five studies, myotomy was performed along with lip repositioning surgery^{8,49-51,54}, while two investigations used sutures to confine the elevator

muscles^{47,52}. The analyzed data indicate an improvement of 1.76 mm (95% confidence interval, 1.34-2.18 mm) with myotomy/muscle containment.(Fig. 3) Tawfik et al.⁴⁹ reported that lip repositioning with myotomy resulted in greater improvement and higher patient satisfaction compared to that without myotomy, which was consistent with the results of another comparative study⁵¹.(Fig. 4)

IV. Discussion

Among the procedures used to improve EGD, lip repositioning is a promising alternative. This procedure has been suggested for patients with minor discrepancies requesting a less invasive procedure compared with orthognathic surgery. It also satisfies patients who do not desire to undergo orthodontic therapy or botulinum toxin A administration. This study was conducted to evaluate the current literature regard-

Table 3. Quality assessment for non-comparative studies

Study	Aim	Inclusion	Data collection	Endpoint	Evaluation (bias)	Follow-up period	Loss to follow-up	Sample size	Total score
Ganesh et al. ⁴⁷ (2019)	2	1	1	2	1	2	2	0	11
Torabi et al. ⁴⁸ (2018)	1	2	1	2	2	2	2	1	13
Alammam and Heshmeh ⁵⁰ (2018)	2	2	2	2	1	1	2	1	13
Storrer et al. ⁵² (2017)	1	1	1	1	1	1	2	0	8
Mantovani et al. ⁵³ (2016)	2	1	1	1	0	1	2	0	8
Abdullah et al. ⁵⁴ (2014)	2	2	2	2	2	2	2	1	15
Ozturan et al. ⁵⁵ (2014)	2	2	2	2	2	2	2	1	15
Jananni et al. ⁵⁶ (2014)	0	1	1	1	1	2	2	0	8
Gabrić Pandurić et al. ⁵⁷ (2014)	2	1	2	2	2	2	2	0	13
Dayakar et al. ⁵⁸ (2014)	1	1	1	1	1	2	2	0	9
Silva et al. ⁵⁹ (2013)	2	2	2	2	2	1	2	1	14
Ribeiro-Júnior et al. ⁶⁰ (2013)	2	1	1	1	1	1	2	1	10
Jacobs and Jacobs ⁶¹ (2013)	2	2	2	2	2	2	2	1	15
Ishida et al. ⁸ (2010)	2	2	2	2	2	2	2	1	15

The items are scored 0 (not reported), 1 (reported but inadequate), or 2 (reported and adequate). The ideal score is 16 for non-comparative studies and 24 for comparative studies.

Mohammadreza Talebi Ardakani et al: Lip repositioning with or without myotomy: a systematic review. J Korean Assoc Oral Maxillofac Surg 2021

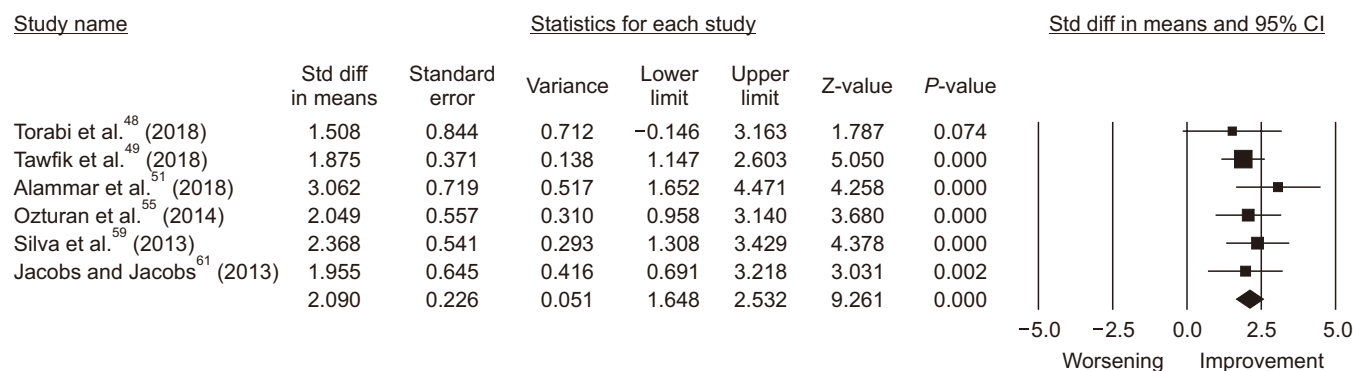


Fig. 2. Forest plot of effect size for lip repositioning without myotomy/muscle containment after 6 months. (Std diff: standard difference, CI: confidence interval)

Mohammadreza Talebi Ardakani et al: Lip repositioning with or without myotomy: a systematic review. J Korean Assoc Oral Maxillofac Surg 2021

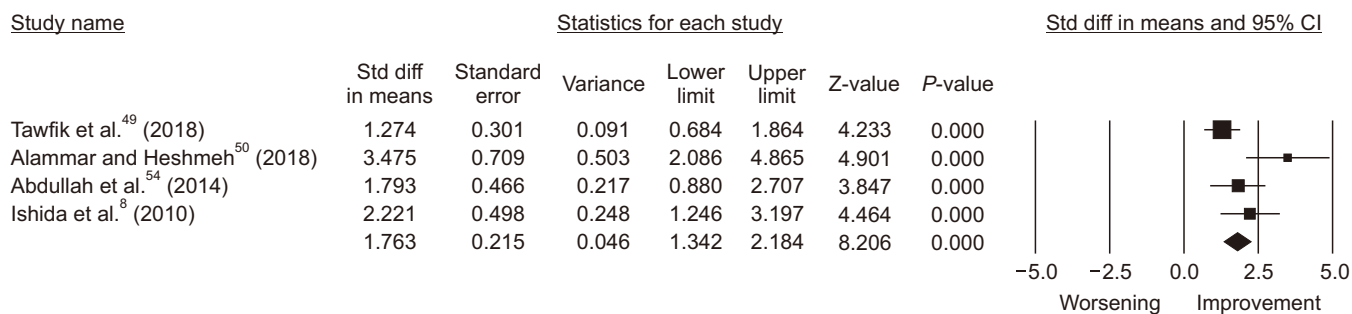


Fig. 3. Forest plot of effect size for lip repositioning with myotomy/muscle containment after 6 months. (Std diff: standard difference, CI: confidence interval)

Mohammadreza Talebi Ardakani et al: Lip repositioning with or without myotomy: a systematic review. *J Korean Assoc Oral Maxillofac Surg* 2021

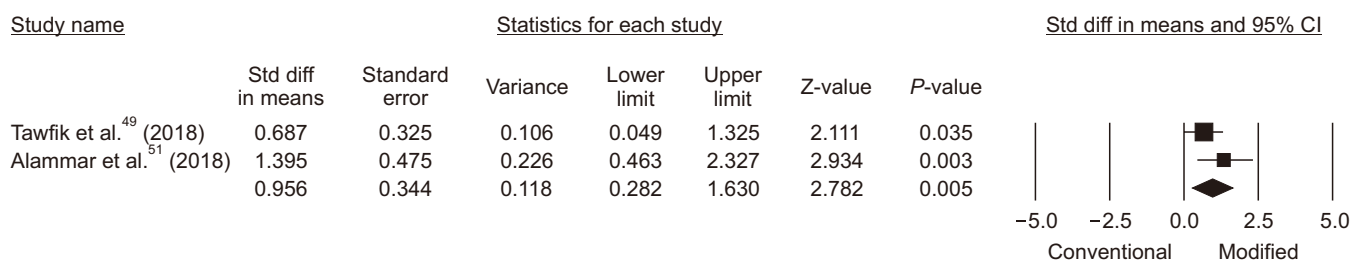


Fig. 4. Forest plot of effect size for comparative studies after 6 months. Conventional: Lip repositioning; Modified: Lip repositioning with myotomy/muscle containment. (Std diff: standard difference, CI: confidence interval)

Mohammadreza Talebi Ardakani et al: Lip repositioning with or without myotomy: a systematic review. *J Korean Assoc Oral Maxillofac Surg* 2021

ing the efficacy of myotomy/muscle containment on outcome and long-term stability of lip repositioning surgery.

Most retrieved articles were case series or case reports. The ideal score for non-comparative studies according to MINORS scoring criteria is 16, though none of the chosen studies obtained this. Therefore, the findings should be interpreted with caution.

Among 7 studies involving myotomy/muscle containment, 6 studies^{8,47,50-52,54} used additional modalities such as crown lengthening and frenectomy. Therefore, it is unclear how much of the improvement is related to lip repositioning surgery alone. One comparative study⁴⁹ that evaluated the effect of myotomy without other interventions reported better results with the modified technique. However, they did not specify the etiologic contributors for gummy smile in their patients and concluded no clear correlation between etiology and achieved improvement. Studies reported various etiologies for their study population, limiting the ability to draw a conclusion, as vertical maxillary excess^{48,56,57} can compromise long-term stability¹⁵.

Some studies reported subjective improvement without an exact measurement of pre/postoperative gingival display^{15,20,23,28,37,40}. Success must be reported based on measurement of all parameters before and after the procedure to

allow exact assessment of the improvement. Consequently, we included studies that reported pre- and postoperative measurements to assess treatment success more accurately. This also applies to patient-related outcome measures (PROMs). Therefore, standardization of the measurement protocol, techniques, outcomes, and PROMs is essential to draw meaningful conclusions.

Tawfik et al.⁶² published a systematic review in 2018, in which they concluded a persuasive need for randomized and comparative trials to assess the influence of different factors on outcomes, complications, and patient satisfaction. They carried out a randomized clinical trial⁴⁹ to evaluate the effect of myotomy on lip repositioning results, reporting EGD reduction by 2.73 ± 1.281 mm with classic lip repositioning and greater reduction of 3.57 ± 1.62 mm with myotomy. In another study, Alammar et al.⁵¹ compared the conventional technique with the modified approach and demonstrated greater sustainability and less relapse in the modified surgical technique including myotomy. However, they conducted crown lengthening in addition to lip repositioning surgery, which must be considered when interpreting the results.

Based on the available data, lip repositioning can be a successful approach for EGD treatment in carefully selected cases, though it has been shown to have a higher chance of

unfavorable results in cases of severe maxillary excess (EGD >8 mm)¹⁵. It seems that myotomy/muscle containment can result in better outcomes and stability of the achieved improvement. However, due to the limited number of studies and the discrepancy in the current evidence, further well-organized comparative clinical trials are needed to derive a conclusion regarding the effectiveness of myotomy/muscle containment compared with the conventional approach.

ORCID

Mohammadreza Talebi Ardakani, <https://orcid.org/0000-0001-9997-3117>

Anahita Moscowchi, <https://orcid.org/0000-0003-1327-5014>

Nasrin Keshavarz Valian, <https://orcid.org/0000-0002-4218-5862>

Elham Zakerzadeh, <https://orcid.org/0000-0003-0860-4207>

Authors' Contributions

M.T.A. participated in the study design and data synthesis. A.M. participated in data collection, performed the statistical analysis, and prepared the manuscript draft. N.K.V. and E.Z. participated in data collection. All authors read and approved the final manuscript.

Conflict of Interest

No potential conflict of interest relevant to this article was reported.

References

1. Tjan AH, Miller GD, The JG. Some esthetic factors in a smile. *J Prosthet Dent* 1984;51:24-8. [https://doi.org/10.1016/s0022-3913\(84\)80097-9](https://doi.org/10.1016/s0022-3913(84)80097-9)
2. Wu H, Lin J, Zhou L, Bai D. Classification and craniofacial features of gummy smile in adolescents. *J Craniofac Surg* 2010;21:1474-9. <https://doi.org/10.1097/SCS.0b013e3181edc627>
3. Miron H, Calderon S, Allon D. Upper lip changes and gingival exposure on smiling: vertical dimension analysis. *Am J Orthod Dentofacial Orthop* 2012;141:87-93. <https://doi.org/10.1016/j.ajodo.2011.07.017>
4. Levine RA, McGuire M. The diagnosis and treatment of the gummy smile. *Compend Contin Educ Dent* 1997;18:757-62, 764; quiz 766.
5. Lee EA. Aesthetic crown lengthening: classification, biologic rationale, and treatment planning considerations. *Pract Proced Aesthet Dent*. 2004;16:769-78; quiz 780.
6. Kokich VG. Esthetics: the orthodontic-periodontic restorative connection. *Semin Orthod* 1996;2:21-30. [https://doi.org/10.1016/s1073-8746\(96\)80036-3](https://doi.org/10.1016/s1073-8746(96)80036-3)
7. Hong RK, Lim SM, Heo JM, Baek SH. Orthodontic treatment of gummy smile by maxillary total intrusion with a midpalatal absolute anchorage system. *Korean J Orthod* 2013;43:147-58. <https://doi.org/10.4041/kjod.2013.43.3.147>
8. Ishida LH, Ishida LC, Ishida J, Grynglas J, Alonso N, Ferreira MC. Myotomy of the levator labii superioris muscle and lip repositioning: a combined approach for the correction of gummy smile. *Plast Reconstr Surg* 2010;126:1014-9. <https://doi.org/10.1097/PRS.0b013e3181e3b6d4>
9. Fowler P. Orthodontics and orthognathic surgery in the combined treatment of an excessively "gummy smile". *N Z Dent J* 1999;95:53-4.
10. Suber JS, Dinh TP, Prince MD, Smith PD. OnabotulinumtoxinA for the treatment of a "gummy smile". *Aesthet Surg J* 2014;34:432-7. <https://doi.org/10.1177/1090820X14527603>
11. Rubinstein AM, Kostianovsky AS. Cosmetic surgery for the malformation of the laugh: original technique. *Prensa Med Argent* 1973;60:952.
12. Litton C, Fournier P. Simple surgical correction of the gummy smile. *Plast Reconstr Surg* 1979;63:372-3. <https://doi.org/10.1097/00006534-197903000-00014>
13. Ellenbogen R, Swara N. The improvement of the gummy smile using the implant spacer technique. *Ann Plast Surg* 1984;12:16-24. <https://doi.org/10.1097/0000637-198401000-00004>
14. Ezquerro F, Berrazueta MJ, Ruiz-Capillas A, Arregui JS. New approach to the gummy smile. *Plast Reconstr Surg* 1999;104:1143-50; discussion 1151-2.
15. Simon Z, Rosenblatt A, Dorfman W. Eliminating a gummy smile with surgical lip repositioning. *J Cosmet Dent* 2007;23:102-9.
16. Moher D, Liberati A, Tetzlaff J, Altman DG; PRISMA Group. Preferred reporting items for systematic reviews and meta-analyses: the PRISMA Statement. *Open Med* 2009;3:e123-30.
17. Harden A, Peersman G, Oliver S, Mauthner M, Oakley A. A systematic review of the effectiveness of health promotion interventions in the workplace. *Occup Med (Lond)* 1999;49:540-8. <https://doi.org/10.1093/occmed/49.8.540>
18. Higgins JPT, Thomas J, Chandler J, Cumpston M, Li T, Page MJ, et al., eds. *Cochrane handbook for systematic reviews of interventions*. 2nd ed. Chichester: John Wiley & Sons; 2019.
19. Slim K, Nini E, Forestier D, Kwiatkowski F, Panis Y, Chipponi J. Methodological index for non-randomized studies (MINORS): development and validation of a new instrument. *ANZ J Surg* 2003;73:712-6. <https://doi.org/10.1046/j.1445-2197.2003.02748.x>
20. Ramesh A, Vellayappan R, Ravi S, Gurumoorthy K. Esthetic lip repositioning: a cosmetic approach for correction of gummy smile - a case series. *J Indian Soc Periodontol* 2019;23:290-4. https://doi.org/10.4103/jisp.jisp_548_18
21. Foudah MA. Lip repositioning: an alternative to invasive surgery a 4 year follow up case report. *Saudi Dent J* 2019;31(Suppl):S78-84. <https://doi.org/10.1016/j.sdentj.2019.02.030>
22. K D, Yadalam U, Ranjan R, Narayan SJ. Lip repositioning, an alternative treatment of gummy smile - a case report. *J Oral Biol Craniofac Res* 2018;8:231-3. <https://doi.org/10.1016/j.jobcr.2017.09.007>
23. Faus-Matoses V, Faus-Matoses I, Jorques-Zafrilla A, Faus-Llácer VJ. Lip repositioning technique. A simple surgical procedure to improve the smile harmony. *J Clin Exp Dent* 2018;10:e408-12. <https://doi.org/10.4317/jced.54721>
24. Sharma A, Sharma S, Garg H, Singhal V, Mishra P. Lip repositioning: a boon in smile enhancement. *J Cutan Aesthet Surg* 2017;10:219-22. https://doi.org/10.4103/JCAS.JCAS_50_17
25. Sánchez IM, Gaud-Quintana S, Stern JK. Modified lip repositioning with esthetic crown lengthening: a combined approach to treating excessive gingival display. *Int J Periodontics Restorative Dent* 2017;37:e130-4. <https://doi.org/10.11607/prd.3124>

26. Littuma GJS, de Souza HCM, Peñarrieta GM, Magini RS, Saba-Chujfi E. Lip repositioning technique with smile elevator muscle containment - a novel cosmetic approach for gummy smile: case report. *Compend Contin Educ Dent* 2017;38:e9-12.
27. Khan MN, Akbar Z, Shah I. Rapid and promising technique to treat gummy smile - lip repositioning. *J Coll Physicians Surg Pak* 2017;27:447-9.
28. Gibson MP, Tatakis DN. Treatment of gummy smile of multifactorial etiology: a case report. *Clin Adv Periodontics* 2017;7:167-73. <https://doi.org/10.1902/cap.2017.160074>
29. Farista S, Yeltiwar R, Kalakonda B, Thakare KS. Laser-assisted lip repositioning surgery: novel approach to treat gummy smile. *J Indian Soc Periodontol* 2017;21:164-8. https://doi.org/10.4103/jisp.jisp_411_16
30. Mahn DH. Elimination of a "gummy smile" with crown lengthening and lip repositioning. *Compend Contin Educ Dent* 2016;37:52-5.
31. Aly LA, Hammouda NI. Botox as an adjunct to lip repositioning for the management of excessive gingival display in the presence of hypermobility of upper lip and vertical maxillary excess. *Dent Res J (Isfahan)* 2016;13:478-83. <https://doi.org/10.4103/1735-3327.197039>
32. Rao AG, Koganti VP, Prabhakar AK, Soni S. Modified lip repositioning: a surgical approach to treat the gummy smile. *J Indian Soc Periodontol* 2015;19:356-9. <https://doi.org/10.4103/0972-124X.152400>
33. Muthukumar S, Natarajan S, Madhankumar S, Sampathkumar J. Lip repositioning surgery for correction of excessive gingival display. *J Pharm Bioallied Sci* 2015;7(Suppl 2):S794-6. <https://doi.org/10.4103/0975-7406.163567>
34. Bhola M, Fairbairn PJ, Kolhatkar S, Chu SJ, Morris T, de Campos M. LipStaT: The lip stabilization technique- indications and guidelines for case selection and classification of excessive gingival display. *Int J Periodontics Restorative Dent* 2015;35:549-59. <https://doi.org/10.11607/prd.2059>
35. Storrer CL, Valverde FK, Santos FR, Deliberador TM. Treatment of gummy smile: gingival recontouring with the containment of the elevator muscle of the upper lip and wing of nose. A surgery innovation technique. *J Indian Soc Periodontol* 2014;18:656-60. <https://doi.org/10.4103/0972-124X.142468>
36. Grover HS, Gupta A, Luthra S. Lip repositioning surgery: a pioneering technique for perio-esthetics. *Contemp Clin Dent* 2014;5:142-5. <https://doi.org/10.4103/0976-237X.128697>
37. Gaddale R, Desai SR, Mudda JA, Karthikeyan I. Lip repositioning. *J Indian Soc Periodontol* 2014;18:254-8. <https://doi.org/10.4103/0972-124X.131349>
38. Sheth T, Shah S, Shah M, Shah E. Lip reposition surgery: a new call in periodontics. *Contemp Clin Dent* 2013;4:378-81. <https://doi.org/10.4103/0976-237X.118353>
39. Humayun N, Kolhatkar S, Souiyas J, Bhola M. Mucosal coronally positioned flap for the management of excessive gingival display in the presence of hypermobility of the upper lip and vertical maxillary excess: a case report. *J Periodontol* 2010;81:1858-63. <https://doi.org/10.1902/jop.2010.100292>
40. Gupta KK, Srivastava A, Singhal R, Srivastava S. An innovative cosmetic technique called lip repositioning. *J Indian Soc Periodontol* 2010;14:266-9. <https://doi.org/10.4103/0972-124X.76936>
41. Rosenblatt A, Simon Z. Lip repositioning for reduction of excessive gingival display: a clinical report. *Int J Periodontics Restorative Dent* 2006;26:433-7.
42. Ambrosio F, Gadalla H, Kapoor N, Neely AL, Kinaia BM. Surgical lip repositioning procedure to correct excessive gingival display: a case report of identical twins. *Clin Adv Periodontics* 2018;8:48-53. <https://doi.org/10.1902/cap.2017.170037>
43. Assenza B, Carinci F, Di Cristinzi A, Sinjari B, Murmura G, Scarno A. A cosmetic technique called lip repositioning in a patient of excessive gingival display. *Eur J Inflamm* 2011;9:115-9.
44. Ergezen E, Akkocaoğlu M, Avağ C. Treatment of excessive gingival display with lip repositioning technique. *Int J Oral Maxillofac Surg* 2017;46(Suppl 1):367. <https://doi.org/10.1016/j.ijom.2017.02.1236>
45. Mangano A, Mangano A. An innovative cosmetic technique called lip repositioning: a less invasive treatment possibility for dentists and surgeons. *J Indian Soc Periodontol* 2013;17:287. <https://doi.org/10.4103/0972-124X.115635>
46. Polo M. Myotomy of the levator labii superioris muscle and lip repositioning: a combined approach for the correction of gummy smile. *Plast Reconstr Surg* 2011;127:2121-2. <https://doi.org/10.1097/PRS.0b013e31820e930a>
47. Ganesh B, Burnice NKC, Mahendra J, Vijayalakshmi R, K AK. Laser-assisted lip repositioning with smile elevator muscle containment and crown lengthening for gummy smile: a case report. *Clin Adv Periodontics* 2019;9:135-41. <https://doi.org/10.1002/cap.10060>
48. Torabi A, Najafi B, Drew HJ, Cappetta EG. Lip repositioning with vestibular shallowing technique for treatment of excessive gingival display with various etiologies. *Int J Periodontics Restorative Dent* 2018;38(Suppl):e1-8. <https://doi.org/10.11607/prd.3120>
49. Tawfik OK, Naiem SN, Tawfik LK, Yussif N, Meghil MM, Cutler CW, et al. Lip repositioning with or without myotomy: a randomized clinical trial. *J Periodontol* 2018;89:815-23. <https://doi.org/10.1002/JPER.17-0598>
50. Alammar AM, Heshmeh OA. Lip repositioning with a myotomy of the elevator muscles for the management of a gummy smile. *Dent Med Probl* 2018;55:241-6. <https://doi.org/10.17219/dmp/92317>
51. Alammar A, Heshmeh O, Mounajjed R, Goodson M, Hamadah O. A comparison between modified and conventional surgical techniques for surgical lip repositioning in the management of the gummy smile. *J Esthet Restor Dent* 2018;30:523-31. <https://doi.org/10.1111/jerd.12433>
52. Storrer CLM, de Oliveira ND, Deliberador TM, Ori LT, Guerrero SM, Santos FR, et al. Treatment of gingival smile: a case report. *J Int Acad Periodontol* 2017;19:51-6.
53. Mantovani MB, Souza EC, Marson FC, Corrêa GO, Progiante PS, Silva CO. Use of modified lip repositioning technique associated with esthetic crown lengthening for treatment of excessive gingival display: a case report of multiple etiologies. *J Indian Soc Periodontol* 2016;20:82-7. <https://doi.org/10.4103/0972-124X.164746>
54. Abdullah WA, Khalil HS, Alhindi MM, Marzook H. Modifying gummy smile: a minimally invasive approach. *J Contemp Dent Pract* 2014;15:821-6. <https://doi.org/10.5005/jp-journals-10024-1625>
55. Ozturan S, Ay E, Sagir S. Case series of laser-assisted treatment of excessive gingival display: an alternative treatment. *Photomed Laser Surg* 2014;32:517-23. <https://doi.org/10.1089/pho.2014.3737>
56. Jananni M, Sivaramakrishnan M, Libby TJ. Surgical correction of excessive gingival display in class I vertical maxillary excess: Mucosal strip technique. *J Nat Sci Biol Med* 2014;5:494-8. <https://doi.org/10.4103/0976-9668.136290>
57. Gabrić Pandurić D, Blašković M, Brozović J, Sušić M. Surgical treatment of excessive gingival display using lip repositioning technique and laser gingivectomy as an alternative to orthognathic surgery. *J Oral Maxillofac Surg* 2014;72:404.e1-11. <https://doi.org/10.1016/j.joms.2013.10.016>
58. Dayakar MM, Gupta S, Shivananda H. Lip repositioning: an alternative cosmetic treatment for gummy smile. *J Indian Soc Periodontol* 2014;18:520-3. <https://doi.org/10.4103/0972-124X.138751>
59. Silva CO, Ribeiro-Júnior NV, Campos TV, Rodrigues JG, Tatakis DN. Excessive gingival display: treatment by a modified lip repositioning technique. *J Clin Periodontol* 2013;40:260-5. <https://doi.org/10.1111/jcpe.12046>
60. Ribeiro-Júnior NV, Campos TV, Rodrigues JG, Martins TM, Silva CO. Treatment of excessive gingival display using a modified lip repositioning technique. *Int J Periodontics Restorative Dent*

- 2013;33:309-14. <https://doi.org/10.11607/prd.1325>
61. Jacobs PJ, Jacobs BP. Lip repositioning with reversible trial for the management of excessive gingival display: a case series. *Int J Periodontics Restorative Dent* 2013;33:169-75. <https://doi.org/10.11607/prd.1483>
 62. Tawfik OK, El-Nahass HE, Shipman P, Looney SW, Cutler CW, Brunner M. Lip repositioning for the treatment of excess gingival display: a systematic review. *J Esthet Restor Dent* 2018;30:101-12. <https://doi.org/10.1111/jerd.12352>

How to cite this article: Ardakani MT, Moscowchi A, Valian NK, Zakerzadeh E. Lip repositioning with or without myotomy: a systematic review. *J Korean Assoc Oral Maxillofac Surg* 2021;47:3-14. <https://doi.org/10.5125/jkaoms.2021.47.1.3>