



Mischievous mandibular third molars camouflaging temporomandibular joint disorders

Aakansha Bhardwaj¹, Savina Gupta¹, Jai Narula²

¹Department of Oral and Maxillofacial Surgery, Jaipur Dental College, Jaipur, India,

²Private Clinic, Palm Desert, CA, USA

Abstract (J Korean Assoc Oral Maxillofac Surg 2022;48:155-158)

Objectives: The aim of this study was to observe the relationship between impacted mandibular third molars and development of temporomandibular joint (TMJ) disorders. Knowledge of the factors that have an adverse effect on the TMJ is necessary for proper diagnosis, treatment, and prognosis of TMJ disorders.

Materials and Methods: The study was performed on 80 patients aged between 20 and 60 years with impacted mandibular third molars, over a period of two months. The patients were examined clinically and radiologically to determine the type of impaction and detect the associated TMJ symptoms or disorders.

Results: In the 80 patients, 63.8% (51/80) of TMJ disorders were found in the horizontal group, 46.3% (37/80) in the mesioangular group, 42.5% (34/80) in the distoangular group, and 30.0% (24/80) in the vertical group of impacted mandibular third molars.

Conclusion: The study concluded that type of impacted mandibular third molar is factor in the development of temporomandibular disorders.

Key words: Clicking, Tenderness, Impaction, Molar, Temporomandibular joint

[paper submitted 2022. 3. 6 / revised 1st 2022. 3. 27, 2nd 2022. 4. 17 / accepted 2022. 4. 23]

I. Introduction

The temporomandibular joint (TMJ) has a complex anatomy¹. The TMJ is unique from the other joints of the body because the left and right sides of the synovial joints are connected with the mandible, so that the two joints function in coordination. The head of the mandibular condyle and the squamous part of the temporal bone are isolated by an articular disk that divides the joint into upper and lower compartments. The mandibular articulation is labelled as bilateral diarthrodial or a freely movable joint, a characteristic of only the TMJ. The upper joint compartment is located between the temporal bone and the articular disk and performs gliding or

translatory movement, whereas the lower joint compartment is located between the head of the mandibular condyle and the articular disk and performs rotary or hinge movement, for which it is called the ginglymo-arthroidal joint². The TMJ plays an important role in the orientation of mandibular movements as well as in balancing stresses due to the daily activities of speech, mastication, and swallowing³.

Temporomandibular disorder (TMD) is the term recommended by the American Dental Association for what is presumed to be a range of painful conditions affecting orofacial and dental structures⁴. TMDs comprise conditions of the joint per say, associated muscles of mastication, ligaments, and surrounding bony structures. These disorders can be congenital, developmental, traumatic, inflammatory, neoplastic, or infectious². In general, TMDs can be divided into intra- and extra-capsular.

TMD prevalence is around 3.7% to 12% of the adult population and 0.7% to 18.6% of the pediatric population^{5,6}. TMD is a public health problem that is particularly important in dentistry because of the number of people affected and its impact on quality of life⁷.

TMD causes pain and functional disorders in the TMJ, which

Aakansha Bhardwaj

Department of Oral & Maxillofacial Surgery, Jaipur Dental College, Dhand, Tehsil-Amer, Jaipur-Delhi National Highway 11C, Jaipur 302028, India

TEL: +91-7792847087

E-mail: aakansha.bhardwaj10@gmail.com

ORCID: <https://orcid.org/0000-0001-7856-3805>

© This is an open-access article distributed under the terms of the Creative Commons Attribution Non-Commercial License (<http://creativecommons.org/licenses/by-nc/4.0/>), which permits unrestricted non-commercial use, distribution, and reproduction in any medium, provided the original work is properly cited.

Copyright © 2022 The Korean Association of Oral and Maxillofacial Surgeons.

controls jaw movement. Symptoms include pain in associated muscles and joint, trismus, joint clicking, and crepitus⁸. Para-functional habits such as grinding and clenching are believed to be extra-capsular problems⁹.

Third molars are problematic in dentistry in a variety of disorders in the orofacial region, including recurrent infection, difficulty in eating, dental crowding, facial swelling, headache, and pain¹⁰. The symptoms of mild to severe TMD can mimic, both in site and nature, the pain that arises from pathology in the third molar region¹¹. These can include trismus, pain during chewing, otalgia, and tenderness of the masticatory apparatus¹². Trauma to the jaw also plays an important role in the incidence and acceleration of TMDs, and those suffering from TMD usually mention a history of trauma to the head or neck¹³.

Removal of the impacted third molars have also been suggested as a factor with the potential to damage TMJ¹⁴. The position and difficulty of impacted mandibular third molars can affect the development of TMDs probably because of their proximity to the TMJ. Therefore, some authors have suggested that TMDs are prevalent in patients referred for extraction of impacted mandibular third molars, and that exacerbation of TMDs after surgical extraction of impacted third molars can be due to the prolonged period of mouth opening¹⁵.

Due to the limited English literature on the relationship between the types of impacted mandibular third molar and the incidence of associated TMDs, the present study focused on the correlation between the types of third molar impactions and TMDs.

II. Materials and Methods

This prospective study was conducted on 80 patients referred to the Department of Oral and Maxillofacial Surgery of Jaipur Dental College from October to December 2020 with the chief complaints of pain, food lodgment, discomfort, and grossly decayed second molar associated with impacted mandibular third molars. All patients in this study were candidates for unilateral or bilateral impacted mandibular third molars and were aged from 20-60 years. All of these patients were chosen through a convenient sampling method and were further referred to the radiology department to obtain orthopantomograms. The exclusion criteria of the study were medically compromised patients, patients with any jaw pathology or any craniofacial anomaly, patients with previous dental surgery, and patients with previous TMJ pathology or

replacement. The study protocol was approved by the Ethics Committee of the Jaipur Dental College (protocol No. 155).

After the radiological examination, the position and angulation of the impacted mandibular third molars were evaluated. The third molars included in the study were classified according to the Winters classification and were divided into four groups of 20 patients each: horizontal, vertical, mesioangular, and distoangular.

Clinical assessment of the patients was conducted with a questionnaire on history and clinical signs and symptoms for detecting TMD. The patients were asked about muscle tenderness, joint soreness, headache, history of trauma, and difficulty in mouth opening. The clinical assessment of TMJ included joint sounds like clicking and crepitus. Click assessment was performed by palpating the tips of the bilateral condyles through gentle pressure of fingers during opening, closing, lateral, and protrusive movements. Irregular mandibular movements or any crepitus or unusual sound on palpation was recorded. Any history of jaw locking while opening or closing and of joint tenderness were also noted.

III. Results

A total of 80 patients with a mean age of 29.8 years with an impacted mandibular third molar were evaluated. All patients were divided into four groups of 20 patients each according to Winters classification of impacted mandibular third molars: vertical, horizontal, mesioangular, and distoangular. Of 80 patients, 51 were female and 29 male. Following radiological investigation for impacted mandibular third molar, clinical assessment of the TMJ was conducted to identify any associated TMDs.

All patients were asked about associated headache, locking of jaw on opening or closing, history of trauma, difficulty in mouth opening, joint sounds like clicking and crepitus, and muscle and joint tenderness or soreness. Many patients in all four groups of impacted mandibular third molars reported multiple TMDs. However, none of the cases reported any history of trauma, associated headaches, or joint crepitus.

Muscle tenderness was the most common symptom associated with impacted mandibular third molars, with 17 cases in the horizontal group, 13 cases in the mesioangular group, six cases in the vertical group, and 11 cases in the distoangular group. Of 80 patients, 32 reported trismus, with 11 cases in the horizontal group, eight in the mesioangular, six in the vertical, and seven in the distoangular group. Joint tenderness was found in a total of 22 cases, with six in the horizontal

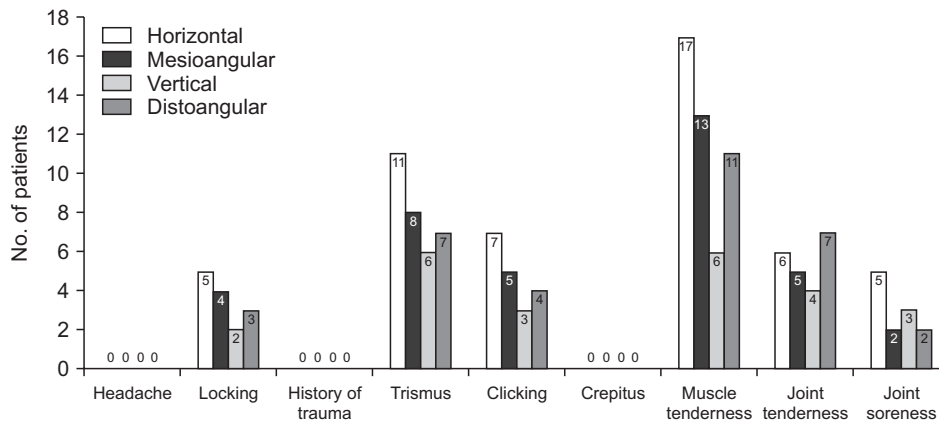


Fig. 1. Temporomandibular disorders associated with impacted mandibular third molar.

Aakansha Bhardwaj et al: Mischievous mandibular third molars camouflaging temporomandibular joint disorders. *J Korean Assoc Oral Maxillofac Surg* 2022

group, five in the mesioangular group, four in the vertical group, and seven in the distoangular group. Nineteen of 80 cases reported clicking, with seven cases in the horizontal group, five in the mesioangular group, three in the vertical group, and four in the distoangular group. Locking and joint soreness were the least reported TMDs associated with any type of impacted mandibular third molars.(Fig. 1)

IV. Discussion

TMJ disorders can greatly impact quality of life and are attributed to several causes. There are many factors that aggravate the symptoms of these disorders, and it is important to identify these by case. In the present study, impacted mandibular third molars were a major factor of development of TMD. Diagnosing these disorders is challenging for many clinicians due to the extensive symptoms and several causative factors. Therefore, diagnosis of the causes and risk factors of these disorders will greatly help in rendering proper treatment to the patients.

Honda et al.¹⁶ stated that proper assessment of joint sounds can play an important role in the diagnosis and treatment of TMJ dysfunction. Kurita et al.¹⁷ stated that the presence or absence of clicking should not be considered unique to disk displacement with and without reduction, and examinations such as magnetic resonance imaging (MRI) are needed to achieve a precise diagnosis of intra-articular disorders and to formulate a treatment plan. According to this study, an impacted third molar is an exacerbating factor in the occurrence of TMDs¹⁷.

In a study by DeAngelis et al.¹¹, 13.3% of patients showed signs and symptoms of TMJ pain and dysfunction, while a further 23.3% also had symptomatic third molar. Thus, it was concluded that the signs of TMD are common in patients

referred for third molar extraction. A study by Akhter et al.¹⁸ investigated the relationship between TMD and surgery of third molars and indicated that third molar removal is associated with joint clicking and limited opening of the mouth.

Kim et al.¹⁹ in their retrospective study analyzed the pathological changes associated with impacted mandibular third molars and adjacent teeth according to age group in a Korean population.

Abouelhuda et al.²⁰ in their practical experience and a review of the literature suggested that headache increases the frequency and intensity of pain parameters, complicating TMD in both diagnostic and treatment phases. Therefore, early and multidisciplinary treatment of TMDs is necessary to avoid overlap of painful events that could become chronic.

V. Conclusion

This study aids in establishing a significant association between impacted mandibular third molar and TMD. This collocation of impacted mandibular third molar and associated TMDs helped in detecting a majority of such disorders at an incipient stage, preventing further development. Considering the symptoms of TMDs, prophylactic treatment measures can be undertaken to treat the associated impacted mandibular third molar and prevent further damage to the TMJ.

This study suggests that TMDs are relatively common in patients who have an impacted mandibular third molar. This study also highlights the propensity of the type of impaction likely to cause severe TMDs. Educating clinicians and patients to take necessary steps might avoid further damage to the TMJ compartment. However, future prospective studies in large populations should be performed as a multi-centered study.

ORCID

Aakansha Bhardwaj, <https://orcid.org/0000-0001-7856-3805>

Savina Gupta, <https://orcid.org/0000-0002-0539-5473>

Jai Narula, <https://orcid.org/0000-0002-6873-6407>

Authors' Contributions

A.B. participated in study design, data collection, statistical analysis and interpretation, writing of manuscript. S.G. participated in formulating study design, editing the manuscript and analysis of data. J.N. participated in data collection and analysis, reviewing manuscript. All authors read and approved the final manuscript.

Ethics Approval and Consent to Participate

The study protocol was approved by the Ethics Committee of the Jaipur Dental College (protocol No. 155).

Conflict of Interest

No potential conflict of interest relevant to this article was reported.

References

1. Ugolini A, Mapelli A, Segù M, Zago M, Codari M, Sforza C. Three-dimensional mandibular motion in skeletal Class III patients. *Cranio* 2018;36:113-20. <https://doi.org/10.1080/08869634.2017.1299830>
2. Jasim HH. Effect of the impacted third molars on the development of temporomandibular joint (TMJ) clicking. *J Int Oral Health* 2019; 11:393-7. https://doi.org/10.4103/jioh.jioh_310_18
3. Murphy MK, MacBarb RF, Wong ME, Athanasiou KA. Temporomandibular disorders: a review of etiology, clinical management, and tissue engineering strategies. *Int J Oral Maxillofac Implants* 2013;28:e393-414. <https://doi.org/10.11607/jomi.te20>
4. Clark GT. Etiologic theory and the prevention of temporomandibular disorders. *Adv Dent Res* 1991;5:60-6. <https://doi.org/10.1177/08959374910050010901>
5. Juhl GI, Jensen TS, Norholt SE, Svensson P. Incidence of symptoms and signs of TMD following third molar surgery: a controlled, prospective study. *J Oral Rehabil* 2009;36:199-209. <https://doi.org/10.1111/j.1365-2842.2008.01925.x>
6. Fischer DJ, Mueller BA, Critchlow CW, LeResche L. The association of temporomandibular disorder pain with history of head and neck injury in adolescents. *J Orofac Pain* 2006;20:191-8.
7. Barbosa C, Gavinha S, Soares T, Manso MC. Coincidence and awareness of the relationship between temporomandibular disorders and jaw injury, orthodontic treatment, and third molar removal in university students. *J Oral Facial Pain Headache* 2016;30:221-7. <https://doi.org/10.11607/ofph.1587>
8. Mirmohamadsadeghi H, Alavi O, Karamshahi M, Tabrizi R. Prevalence of temporomandibular joint problems in candidate patients for impacted third molar surgery with and without the previous temporomandibular disorder: a prospective study. *Dent Hypotheses* 2019;10:29-33. https://doi.org/10.4103/denthyp.denthyp_48_19
9. De Rossi SS, Greenberg MS, Liu F, Steinkeler A. Temporomandibular disorders: evaluation and management. *Med Clin North Am* 2014;98:1353-84. <https://doi.org/10.1016/j.mcna.2014.08.009>
10. Lopes V, Mumenya R, Feinmann C, Harris M. Third molar surgery: an audit of the indications for surgery, post-operative complaints and patient satisfaction. *Br J Oral Maxillofac Surg* 1995;33:33-5. [https://doi.org/10.1016/0266-4356\(95\)90083-7](https://doi.org/10.1016/0266-4356(95)90083-7)
11. DeAngelis AF, Chambers IG, Hall GM. Temporomandibular joint disorders in patients referred for third molar extraction. *Aust Dent J* 2009;54:323-5. <https://doi.org/10.1111/j.1834-7819.2009.01157.x>
12. Bertoli FM, Antoniuk SA, Bruck I, Xavier GR, Rodrigues DC, Losso EM. Evaluation of the signs and symptoms of temporomandibular disorders in children with headaches. *Arq Neuropsiquiatr* 2007;65:251-5. <https://doi.org/10.1590/s0004-282x2007000200012>
13. Pullinger AG, Seligman DA. TMJ osteoarthritis: a differentiation of diagnostic subgroups by symptom history and demographics. *J Craniomandib Disord* 1987;1:251-6.
14. Huang GJ, Rue TC. Third-molar extraction as a risk factor for temporomandibular disorder. *J Am Dent Assoc* 2006;137:1547-54. <https://doi.org/10.14219/jada.archive.2006.0090>
15. Deliverska EG, Petkova M. Complications after extraction of impacted third molars - literature review. *J IMAB* 2016;22:1202-11. <https://doi.org/10.5272/jimab.2016223.1202>
16. Honda K, Natsumi Y, Urade M. Correlation between MRI evidence of degenerative condylar surface changes, induction of articular disc displacement and pathological joint sounds in the temporomandibular joint. *Gerodontology* 2008;25:251-7. <https://doi.org/10.1111/j.1741-2358.2008.00219.x>
17. Kurita H, Ohtsuka A, Kobayashi H, Kurashina K. The relationship between the degree of disk displacement and ability to perform disk reduction. *Oral Surg Oral Med Oral Pathol Oral Radiol Endod* 2000;90:16-20. <https://doi.org/10.1067/moe.2000.107222>
18. Akhter R, Hassan NM, Ohkubo R, Tsukazaki T, Aida J, Morita M. The relationship between jaw injury, third molar removal, and orthodontic treatment and TMD symptoms in university students in Japan. *J Orofac Pain* 2008;22:50-6.
19. Kim JY, Jee HG, Song HC, Kim SJ, Kim MR. Clinical and pathologic features related to the impacted third molars in patients of different ages: a retrospective study in the Korean population. *J Dent Sci* 2017;12:354-9. <https://doi.org/10.1016/j.jds.2017.01.004>
20. Abouelhuda AM, Kim HS, Kim SY, Kim YK. Association between headache and temporomandibular disorder. *J Korean Assoc Oral Maxillofac Surg* 2017;43:363-7. <https://doi.org/10.5125/jkaoms.2017.43.6.363>

How to cite this article: Bhardwaj A, Gupta S, Narula J. Mischievous mandibular third molars camouflaging temporomandibular joint disorders. *J Korean Assoc Oral Maxillofac Surg* 2022;48:155-158. <https://doi.org/10.5125/jkaoms.2022.48.3.155>