



Randomized clinical trial to evaluate the efficacy and safety of two types of sandblasted with large-grit and acid-etched surface implants with different surface roughness

Jun-Hyung Jeon¹, Min-Joong Kim¹, Pil-Young Yun^{1,2}, Deuk-Won Jo³, Young-Kyun Kim¹

¹Department of Oral and Maxillofacial Surgery, Section of Dentistry, Seoul National University Bundang Hospital, Seongnam,

²Department of Dentistry and Dental Research Institute, School of Dentistry, Seoul National University, Seoul,

³Department of Prosthodontics, Section of Dentistry, Seoul National University Bundang Hospital, Seongnam, Korea

Abstract (J Korean Assoc Oral Maxillofac Surg 2022;48:225-231)

Objectives: This study aims to evaluate the efficacy and safety of two types of sandblasted with large-grit and acid-etched (SLA) surface implants with different surface roughness.

Patients and Methods: This study was conducted based on a clinical record review of 55 patients (mean age, 53.00 years). A total of 80 SLA surface implants was placed. Among the 80 implants, 38 implants placed in 29 subjects had surface roughness (Ra) of 3.09 μm (test group, TG), while the other 42 implants placed in 31 subjects had a surface roughness (Ra) of 2.50 μm (control group, CG). A comparison was made of implant primary/secondary stability; success and survival rates; marginal bone loss; and soft tissue assessment including probing pocket depth (PPD), plaque index (PI), gingival index (GI), and bleeding on probing (BOP) between the groups at 1 year after implant placement.

Results: Among the implants that were initially registered, 1 from the TG and 4 from the CG dropped out, leaving 37 implants in the TG and 38 implants in the CG to be traced and analyzed. Although 1 TG case showed unstable primary stability, all cases showed stable secondary stability. Success and survival rates at 1 year after implant placement were 100% in both groups. Marginal bone loss was 0.07 mm and 0.00 mm for the TG and CG, respectively, but the difference was not significant. Among the several parameters for evaluation of soft tissue, the TG showed lower PI at 1 year after implant placement (TG=0.00, CG=0.29; $P=0.0004$), while the remaining categories showed no significant difference between the groups.

Conclusion: This study shows that the two types of SLA implants with different surface roughness have no difference in efficacy or safety. Therefore, both of the implants can be used safely and with promising outcomes.

Key words: Dental implants, Osseointegration, SLA, Surface roughness

[paper submitted 2022. 5. 6 / revised 1st 2022. 6. 19, 2nd 2022. 8. 9 / accepted 2022. 8. 12]

I. Introduction

The stability of a dental implant depends on the level of osseointegration, which is affected by several factors such as the shape, structure, and surface of the implant. Early titanium implants had a smooth, mechanically polished surface,

but studies revealed that implants with a rough surface are more stable and superior in the long term^{1,2}. The purpose of surface treatment of implants is to improve osseointegration between the bone and the implant by generating micro-irregularities that produce a larger contact area³. Accordingly, various methods have been proposed to increase the initial fixation force based on mechanical and chemical stimulation of the implant surface. Examples of such treatments include a blasting method that sprays TiO_2 or Al_2O_3 particles to scratch the surface, an acid-etched method that erodes the implant surface with a high-temperature acidic solution to increase the roughness, a porous sintering method, an anodizing method, and sandblasted with large-grit and acid-etched (SLA) methods^{4,5}.

Recently, the SLA method, which combines the blasting and acid-etch methods, has been widely applied in implant

Young-Kyun Kim

Department of Oral and Maxillofacial Surgery, Section of Dentistry, Seoul National University Bundang Hospital, 82 Gumi-ro 173beon-gil, Bundang-gu, Seongnam 13620, Korea

TEL: +82-31-787-7541

E-mail: kyk0505@snuh.org

ORCID: <https://orcid.org/0000-0002-7268-3870>

© This is an open-access article distributed under the terms of the Creative Commons Attribution Non-Commercial License (<http://creativecommons.org/licenses/by-nc/4.0/>), which permits unrestricted non-commercial use, distribution, and reproduction in any medium, provided the original work is properly cited.

Copyright © 2022 The Korean Association of Oral and Maxillofacial Surgeons.

processing. The SLA method increases surface roughness (Ra) at both the macro and micro levels because acid corrosion after particle blasting further disrupts the surface. This method fosters increased osseointegration by facilitating contact of the rough surface with a larger number of osteoblasts and their surface energy compared with a smooth surface. The reported 10-year survival rate and incidence of peri-implantitis of SLA surface implants are 99.7% and 7.0%, respectively, indicating an adequate long-term prognosis^{6,7}. Goyal and Kaur⁸ observed that increased roughness can simultaneously increase the surface area of the implant, improve cell migration and attachment to the implant, and enhance the osseointegration process. However, excessively increasing Ra without consideration of the characteristics of the implant can prevent bone from adhering to the implant surface. Therefore, the optimal Ra of the implant should be dependent upon the characteristics of the surface treatments done on the implants⁹.

According to Knabe et al.¹⁰, for SLA implants, it is suggested that an Ra of 3.43 μm exhibits the highest stability. The Ra of one of the most widely used SLA implants approved in Korea is 2.50 μm. Therefore, Sewon Medics has developed an SLA implant with further increased Ra while maintaining other conditions. This clinical study was conducted to evaluate the safety and effectiveness of SLA implants with increased Ra compared to previously-licensed SLA implants.

II. Patients and Methods

This prospective clinical study was conducted after receiving approval from the Institutional Review Board (IRB) of Seoul National University Bundang Hospital (IRB No. E-1909-564-003). From March 2020 to September 2021, 55 subjects who underwent dental implant placement due to tooth loss at Seoul National University Bundang Hospital Dental Clinic were registered. Two types of implants with different Ra were used, both of which were SLA surface, internal connection, titanium implants. The implant used in the test group (TG) was IH2 SLA fixture (Sewon Medics, Busan, Korea), with an Ra of 3.09 μm. The implant used in the control group (CG) was TSIII SA (Osstem Implant, Seoul, Korea), which has an Ra of 2.50 μm and is currently licensed and widely used in Korea.

In this clinical trial, 55 patients were enrolled according to strict pre-defined inclusion and exclusion criteria.(Table 1) A total of 80 SLA implants were randomly assigned to the TG and CG and placed in 55 healthy subjects who provided written informed consent to implant surgery for restoration of missing teeth. Of these, 38 implants in 29 subjects were included in the TG and 42 implants in 31 subjects were included in the CG. Five subjects received both TG and CG implants.

All implants were placed by a single surgeon without bone graft. Immediately after implant placement, primary stability (implant stability quotient, ISQ) was measured using an Osstell Mentor (Osstell, Gothenburg, Sweden). The second sur-

Table 1. Inclusion and exclusion criteria

Inclusion criteria	Age over 19 years	
	Patients with at least one (maximum 3) missing teeth needing implantation	
	Patients with fair oral hygiene	
	For fertile female patients who have agreed on contraception	
	Patients who voluntarily participated in the research	
	Patients willing to abide by the program	
	Predicted implant site has 1-3 quality bone density and a sufficient quantity of bone	
	Opposing teeth and adjacent teeth exist and will not undergo implantation within the follow-up period	
	Exclusion criteria	Patients with severe periodontitis or infection
		Patients with bone lesions or a relevant surgical procedure
		Patients with bone-related disease
		Patients who smoke 20 or more cigarettes per day
		Alcohol or drug addiction
Patients with severe clenching or bruxism		
Patients who underwent extraction <8 weeks before		
Patients who had radiation therapy within 6 months		
Patients who received any kind of GBR (guided bone regeneration) within 6 months		
Systemic condition that contraindicates oral surgical procedures		
Pregnant or lactating or the possibility of becoming pregnant		
Cases that need bone augmentation		

Jun-Hyung Jeon et al: Randomized clinical trial to evaluate the efficacy and safety of two types of sandblasted with large-grit and acid-etched surface implants with different surface roughness. J Korean Assoc Oral Maxillofac Surg 2022

gery was performed 20 weeks after implant placement in the upper jaw and 8 weeks after implant placement in the mandible. Secondary stability was measured during the second surgery using the Osstell Mentor. The threshold of implant stability measured by ISQ was set to 60 based on the results of Rodrigo et al.¹¹, where it was reported that implant failure rarely occurs when ISQ >60 and failure rates rise to 19% when ISQ is >60^{11,12}. The final implant prosthesis was loaded with a single crown by a single prosthodontist 4 weeks after the second surgery.

Medical records and radiographic information (panoramic view, periapical view) were used to evaluate implant success and survival rates, marginal bone loss, and soft tissue factors including probing pocket depth (PPD), plaque index (PI), gingival index (GI), and bleeding on probing (BOP) at 1 year after implant placement.

1. Success rate

The implant success rate 1 year after placement was compared between groups as follows.

$$\text{Success rate (\%)} = \frac{\text{Number of cases of implant success}}{\text{Total number of cases}} \times 100$$

Success of the implant was noted when all of the following conditions were satisfied¹³: 1) The implant was not fractured and survived in the placed position; 2) There was no persistent pain, foreign body sensation, or dysesthesia; 3) There was no inflammation accompanied by suppuration around the implant; 4) The PPD on the buccal (or labial), palatal (or lingual), mesial, and distal sides was less than 5 mm; 5) The implant showed no mobility; and 6) There was no radiolucent lesion around the implant and no marginal bone loss on apical radiographic examination.

2. Survival rate

The implant survival rate at 1 year after placement was compared and evaluated between the groups as follows.

$$\text{Survival rate (\%)} = \frac{\text{Number of cases of implant survival}}{\text{Total number of cases}} \times 100$$

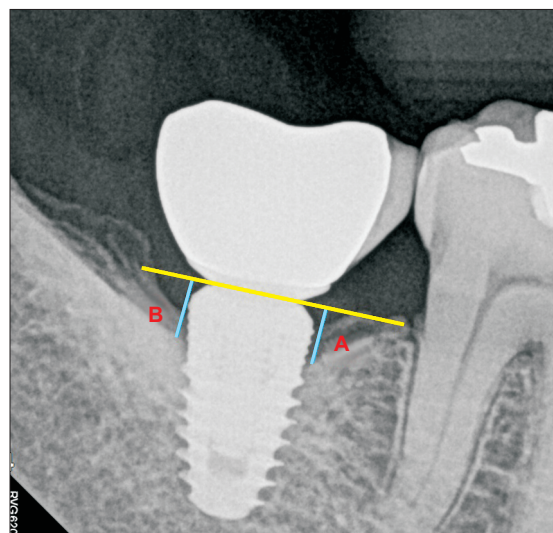


Fig. 1. Landmarks of the radiographic measurements. A point: Linear distance from implant shoulder to contact point of implant and bone (mesial surface), B point: Linear distance from implant shoulder to contact point of implant and bone (distal surface). The mean value of A point and B point was set as the marginal bone resorption amount.

Jun-Hyung Jeon et al: Randomized clinical trial to evaluate the efficacy and safety of two types of sandblasted with large-grit and acid-etched surface implants with different surface roughness. J Korean Assoc Oral Maxillofac Surg 2022

Implant survival was defined as implant persistence at the implanted site.

3. Marginal bone loss

The amount of marginal bone loss at 1 year after implant placement was evaluated using a baseline periapical radiograph collected 2 weeks after implant placement. Marginal bone loss was measured as the distance between the shoulder of the implant and the uppermost part of the bone in contact with the implant and averaged between the mesial and distal sides. The measurements were calculated as a proportion of the actual length of the implant and the length on radiographs.(Fig. 1)

4. Soft tissue evaluation

Soft tissue evaluation involved examination of PPD, PI, GI, and BOP. PPD was measured using a periodontal probe at four sites (buccal [or labial], palatal [or lingual], mesial, and distal) along the tooth¹⁴. PI was evaluated as follows: 0 for no plaque, 1 for a thin plaque layer at the gingival margin, only detectable by scraping with a probe, 2 for a moderate layer of plaque along the gingival margin, interdental spaces, and free but when plaque is visible to the naked eye, and 3 for

Table 2. Number of implants and subjects by group

Group	Registered	Lost	Final
Test group	38 (29)	1 (1)	37 (28)
Control group	42 (31)	4 (2)	38 (29)
Total	80 (55) ¹	5 (3)	75 (52)

¹Five patients received both types of implants.

Values are presented as No. of implants (No. of subjects).

Jun-Hyung Jeon et al: Randomized clinical trial to evaluate the efficacy and safety of two types of sandblasted with large-grit and acid-etched surface implants with different surface roughness. J Korean Assoc Oral Maxillofac Surg 2022

Table 3. Demographic analysis between groups

	TG	CG	P-value
Sex			0.8930
Male	16	16	
Female	12	13	
Age (yr)			0.1387
Number	28	29	
Mean±SD	55.10±10.54	50.83±11.64	
Median	58.00	54.00	
Min, Max	27.00, 73.00	23.00, 71.00	
Severe clenching/bruxism			-
Yes	0	0	
No	28	29	
Drinking			0.7072
Yes	3	4	
No	25	25	
Smoking			0.6713
Yes	2	5	
No	26	24	

(TG: test group, CG: control group, SD: standard deviation, Min: minimum, Max: maximum)

Jun-Hyung Jeon et al: Randomized clinical trial to evaluate the efficacy and safety of two types of sandblasted with large-grit and acid-etched surface implants with different surface roughness. J Korean Assoc Oral Maxillofac Surg 2022

abundant plaque along the gingival margin, interdental spaces filled with plaque. The Levene GI was evaluated as follows: 0 for normal gingiva, no inflammation, no discoloration, no bleeding, 1 for mild inflammation, slight erythema, minimal superficial alterations, no bleeding, 2 for moderate inflammation, erythema, BOP, and 3 for severe inflammation, severe erythema and swelling, spontaneous bleeding and possible ulceration. BOP was evaluated positive if bleeding occurred within 30 seconds after periodontal probing and negative if not¹⁴.

The results of primary and secondary stability, survival rate, success rate, marginal bone loss, and soft tissue evaluation were analyzed using IBM SPSS Statistics (ver. 25.0; IBM, Armonk, NY, USA). Statistical analysis was performed with the chi-square test, Fisher's exact test, and multiple regression analysis, which tested the significance of any association at a level of 95%.

Table 4. Implantation site by group (unit: No. of implants)

Group	Anterior	Premolar	Molar	Total (%)
TG (n=37)				
Upper jaw	-	4	5	9 (24.3)
Lower jaw	-	5	23	28 (75.7)
CG (n=38)				
Upper jaw	2	3	5	10 (26.3)
Lower jaw	-	5	23	28 (73.7)

(TG: test group, CG: control group)

Jun-Hyung Jeon et al: Randomized clinical trial to evaluate the efficacy and safety of two types of sandblasted with large-grit and acid-etched surface implants with different surface roughness. J Korean Assoc Oral Maxillofac Surg 2022

Table 5. Implant primary/secondary stability

Group	Primary stability (ISQ)		Secondary stability (ISQ)	
	Mean±SD	<60	Mean±SD	<60
TG (n=37)	79.7±10.22	1	82.1±11.12	0
CG (n=38)	82.9±10.00	0	84.4±10.31	0
P-value	>0.999		>0.999	

(ISQ: implant stability quotient, SD: standard deviation, TG: test group, CG: control group)

Jun-Hyung Jeon et al: Randomized clinical trial to evaluate the efficacy and safety of two types of sandblasted with large-grit and acid-etched surface implants with different surface roughness. J Korean Assoc Oral Maxillofac Surg 2022

Table 6. Evaluation of the success rate, survival rate, and marginal bone loss (MBL) 1 year after implant placement

Group	Success rate (%)	Survival rate (%)	MBL (mm)
TG (n=37)	100	100	0.07
CG (n=38)	100	100	0.00
P-value	-	-	0.0778

(TG: test group, CG: control group)

Jun-Hyung Jeon et al: Randomized clinical trial to evaluate the efficacy and safety of two types of sandblasted with large-grit and acid-etched surface implants with different surface roughness. J Korean Assoc Oral Maxillofac Surg 2022

III. Results

Among the 38 TG and 42 CG implants that were initially registered, 1 TG patient and 2 CG patients dropped out during follow-up. The TG patient failed to complete follow-up, and the 2 CG patients had more than 3 missing teeth 8 weeks before implantation and thus did not meet the inclusion category. Therefore, 37 TG implants and 38 CG implants were followed and analyzed in this clinical trial, as shown in Table 2. Analysis of basic demographic data (sex, age, severe clenching/bruxism, and drinking and smoking habits) was conducted, and no statistically significant differences were found between the two groups.(Table 3)

The implantation sites were 4 maxillary premolars, 5 maxillary molars, 5 mandibular premolars, and 23 mandibular molars in the TG and 2 maxillary incisors and 3 maxillary premolars, 5 maxillary molars, 5 mandibular premolars, and

Table 7. Evaluation of soft tissue 1 year after implant placement (categorical analysis)

	TG (n=37)	CG (n=38)	Total (n=75)	P-value
PPD (mm)	3.01	2.95	2.98	0.2690
PI				0.0004*
0	37	27	64	
1	0	11	11	
2	0	0	0	
3	0	0	0	
GI	32	32	64	0.7806
0	5	6	11	
1	0	0	0	
2	0	0	0	
3				
BOP				-
Yes	0	0	0	
No	37	38	75	

(TG: test group, CG: control group, PPD: probing pocket depth, PI: plaque index, GI: gingival index, BOP: bleeding on probing)

* $P < 0.05$; statistically significant.

Values are presented as mean only or number only.

Jun-Hyung Jeon et al: Randomized clinical trial to evaluate the efficacy and safety of two types of sandblasted with large-grit and acid-etched surface implants with different surface roughness. *J Korean Assoc Oral Maxillofac Surg* 2022

23 mandibular molars in the CG, as shown in Table 4.

The mean primary stability of implants in the 37 cases in the TG was 79.7 ISQ, and a single case showed a primary stability lower than 60. The mean primary stability of the 38 cases in the CG was 82.9 ISQ, and none of the cases showed stability lower than 60. Also, mean secondary stability was 82.1 ISQ in the TG and 84.4 ISQ in the CG, and none of the cases showed values lower than 60. (Table 5)

The success and survival rates 1 year after implant placement were 100% for both groups. Marginal bone loss 1 year after implant placement was 0.07 mm for the TG and 0.00 mm for the CG, but this difference was not significant ($P = 0.0778$). (Table 6)

The evaluation of soft tissue 1 year after implant placement showed a significantly lower PI in the TG compared to the CG (TG=0.00, CG=0.29; $P = 0.0004$), while the other categories were not significantly different between groups. (Tables 7, 8)

IV. Discussion

Dental implants have become a universal treatment method for restoration of lost teeth. Many advancements in implant shape and surface have been made in order to promote osseointegration and ensure long-term stability¹⁵. Dental implants started out as a machined, smooth-surface external-type implants, now known as the Branemark system, after which internal connection-type implants were adopted, which are now more widely used¹⁶⁻¹⁸. Different types of implant fix-

Table 8. Evaluation of soft tissue 1 year after implant placement (continuous analysis)

	TG (n=37)	CG (n=38)	Total (n=75)	P-value
PPD (mm)				0.2690
Number	37	38	75	
Mean	3.01	2.95	2.98	
Median	3.00	3.00	3.00	
Min, Max	2.50, 3.75	2.00, 4.00	2.00, 4.00	
PI				0.0004*
Number	37	38	75	
Mean	0.00	0.29	0.15	
Median	0.00	0.00	0.00	
Min, Max	0.00, 0.00	0.00, 1.00	0.00, 1.00	
GI				0.7887
Number	37	38	75	
Mean	0.14	0.16	0.15	
Median	0.00	0.00	0.00	
Min, Max	0.00, 1.00	0.00, 1.00	0.00, 1.00	

(TG: test group, CG: control group, PPD: probing pocket depth, Min: minimum, Max: maximum, PI: plaque index, GI: gingival index)

* $P < 0.05$; statistically significant.

Jun-Hyung Jeon et al: Randomized clinical trial to evaluate the efficacy and safety of two types of sandblasted with large-grit and acid-etched surface implants with different surface roughness. *J Korean Assoc Oral Maxillofac Surg* 2022

tures have been introduced for different purposes. A straight body allows easy control of implantation depth and has an excellent self-tapping ability, while a tapered body is useful for immediate implantation after tooth extraction and shows excellent initial fixation by compacting trabecular bone when needed¹⁹⁻²¹. However, according to Jang et al.²², there is no significant difference in long-term clinical prognosis between tapered and straight implants, and the selection should be based on the implantation site and operator's preference. Implant surface treatment improves the wettability of the surface and increases bone-implant contact to improve osseointegration. The SLA method, which currently is the most widely used technique, employs TiO₂ or Al₂O₃ particles for surface abrasion, and several studies mention that 75- μ m aluminum particles are most effective for sandblasting. The second step, acid treatment, increases micro-roughness to further increase osseointegration²³⁻²⁶.

This study was conducted to compare the short-term clinical prognosis of two internal connection-type, tapered, SLA-surface implants with different surface roughness. The implant used for the TG was the submerged-type IH2 SLA Fixture developed by Sewon Medics and is a titanium internal hex with an 11-degree Morse taper structure. Surface roughness with this implant was 3.09 μ m after SLA treatment. The implant used for the CG was the common TSIII SA implant developed by Osstem Implant, which is also a submerged-type, titanium internal hex with an 11-degree Morse taper structure. The surface roughness of the TSIII SA

is 2.50 μm .

In this clinical trial, complications were reported in 3 cases (TG: 3 cases, CG: 0 case). The 3 treatment site complications were 'implant site discharge,' 'implant site swelling,' and 'implant site hemorrhage,' all of which are classified as 'General disorders and administration site conditions' according to MedDRA's SOC (System Organ Class) criteria. All 3 complications were 'mild' and had little or no relevance to the implant procedure. All 3 cases recovered before final follow-up. Both types of SLA surface implants compared in this clinical study had a 100% success rate, and marginal bone loss of less than 0.1 mm. Soft tissue measures 1 year after implant placement also showed stable results in both groups. Although 1 case from the TG showed unstable primary stability, all cases eventually showed stable ISQ in terms of secondary stability, proving the effectiveness and safety of both implants.

The implants were placed in patients with relatively good condition, and the second surgery and prosthetic loading proceeded after sufficient healing, producing good clinical results. There was no difference in clinical performance according to surface roughness under the SLA modification. This prospective randomized clinical trial has value as a reference for clinical research for approval of dental devices.

Surface roughness is indisputably an important factor determining dental implant osseointegration. Although the results of this study indicate that an implant with increased surface roughness show similar stability to preexisting implants, the ideal surface roughness for osseointegration and primary stability remains unclear⁹. Further innovative studies at the nanoscale level may provide valuable insight into dental implantology.

V. Conclusion

This study demonstrated that two types of SLA implants with different surface roughness showed similar efficacy and safety. Both of these implants can be used safely and with promising outcomes.

ORCID

Jun-Hyung Jeon, <https://orcid.org/0000-0003-1691-5400>

Min-Joong Kim, <https://orcid.org/0000-0001-5660-221X>

Pil-Young Yun, <https://orcid.org/0000-0001-6097-1229>

Deuk-Won Jo, <https://orcid.org/0000-0002-3646-4275>

Young-Kyun Kim, <https://orcid.org/0000-0002-7268-3870>

Authors' Contributions

J.H.J. participated in data collection and wrote the manuscript. K.Y.K. participated in the study design and coordination and helped to draft the manuscript. M.J.K., P.Y.Y., and D.W.J. participated in the data collection. All authors read and approved the final manuscript.

Ethics Approval and Consent to Participate

This prospective clinical study was conducted after receiving approval from the Institutional Review Board of Seoul National University Bundang Hospital (IRB No. E-1909-564-003), and the written informed consent was obtained from all patients.

Conflict of Interest

No potential conflict of interest relevant to this article was reported.

References

1. Kim HK, Lee EY, Kim JJ. Five-year retrospective radiographic follow-up study of dental implants with sandblasting with large grit, and acid etching-treated surfaces. *J Korean Assoc Oral Maxillofac Surg* 2015;41:317-21. <https://doi.org/10.5125/jkaoms.2015.41.6.317>
2. Rosales-Leal JJ, Rodríguez-Valverde MA, Mazzaglia G, Ramón-Torregrosa PJ, Díaz-Rodríguez L, García-Martínez O, et al. Effect of roughness, wettability and morphology of engineered titanium surfaces on osteoblast-like cell adhesion. *Colloids Surf A Physicochem Eng Asp* 2010;365:222-9. <https://doi.org/10.1016/j.colsurfa.2009.12.017>
3. Elkhaweldi A, Lee DH, Wang WCW, Cho SC. The survival rate of RBM surface versus SLA surface in geometrically identical implant design. *J Oral Biol* 2014;1:8.
4. Smeets R, Stadlinger B, Schwarz F, Beck-Broichsitter B, Jung O, Precht C, et al. Impact of dental implant surface modifications on osseointegration. *Biomed Res Int* 2016;2016:6285620. <https://doi.org/10.1155/2016/6285620>
5. Buser D, Janner SF, Wittneben JG, Brägger U, Ramseier CA, Salvi GE. 10-Year survival and success rates of 511 titanium implants with a sandblasted and acid-etched surface: a retrospective study in 303 partially edentulous patients. *Clin Implant Dent Relat Res* 2012;14:839-51. <https://doi.org/10.1111/j.1708-8208.2012.00456.x>
6. Kim SB, Yun PY, Kim SY, Yi YJ, Kim JY, Kim YK. Prospective randomized clinical trial of hydrophilic tapered implant placement at maxillary posterior area: 6 weeks and 12 weeks loading. *J Adv Prosthodont* 2016;8:396-403. <https://doi.org/10.4047/jap.2016.8.5.396>
7. Kim MJ, Yun PY, Chang NH, Kim YK. The long-term evaluation of the prognosis of implants with acid-etched surfaces sandblasted with alumina: a retrospective clinical study. *Maxillofac Plast Reconstr Surg* 2020;42:10. <https://doi.org/10.1186/s40902-020-00255-6>

8. Goyal N, Kaur R. Effect of various implant surface treatments on osseointegration - a literature review. *Indian J Dent Sci* 2012;4:154-7.
9. Jemat A, Ghazali MJ, Razali M, Otsuka Y. Surface modifications and their effects on titanium dental implants. *Biomed Res Int* 2015;2015:791725. <https://doi.org/10.1155/2015/791725>
10. Knabe C, Klar F, Fitzner R, Radlanski RJ, Gross U. In vitro investigation of titanium and hydroxyapatite dental implant surfaces using a rat bone marrow stromal cell culture system. *Biomaterials* 2002;23:3235-45. [https://doi.org/10.1016/s0142-9612\(02\)00078-9](https://doi.org/10.1016/s0142-9612(02)00078-9)
11. Rodrigo D, Aracil L, Martin C, Sanz M. Diagnosis of implant stability and its impact on implant survival: a prospective case series study. *Clin Oral Implants Res* 2010;21:255-61. <https://doi.org/10.1111/j.1600-0501.2009.01820.x>
12. Matos GRM. Surface roughness of dental implant and osseointegration. *J Maxillofac Oral Surg* 2021;20:1-4. <https://doi.org/10.1007/s12663-020-01437-5>
13. Papaspyridakos P, Chen CJ, Singh M, Weber HP, Gallucci GO. Success criteria in implant dentistry: a systematic review. *J Dent Res* 2012;91:242-8. <https://doi.org/10.1177/0022034511431252>
14. Newman M, Takei H, Klokkevold P, Carranza F. Carranza's clinical periodontology. 12th ed. St. Louis (MO): Saunders; 2014.
15. Gittens RA, Olivares-Navarrete R, Schwartz Z, Boyan BD. Implant osseointegration and the role of microroughness and nanostructures: lessons for spine implants. *Acta Biomater* 2014;10:3363-71. <https://doi.org/10.1016/j.actbio.2014.03.037>
16. Albrektsson T, Brånemark PI, Hansson HA, Lindström J. Osseointegrated titanium implants. Requirements for ensuring a long-lasting, direct bone-to-implant anchorage in man. *Acta Orthop Scand* 1981;52:155-70. <https://doi.org/10.3109/17453678108991776>
17. Anil S, Anand PS, Alghamdi H, Jansen JA. Dental implant surface enhancement and osseointegration. In: Turkyilmaz I, ed. *Implant dentistry*. London: IntechOpen; 2011:83-108.
18. Elias CN, Meirelles L. Improving osseointegration of dental implants. *Expert Rev Med Devices* 2010;7:241-56. <https://doi.org/10.1586/erd.09.74>
19. Lee JH, Jeong SN. Efficacy of deep convolutional neural network algorithm for the identification and classification of dental implant systems, using panoramic and periapical radiographs: a pilot study. *Medicine (Baltimore)* 2020;99:e20787. <https://doi.org/10.1097/MD.00000000000020787>
20. O'Sullivan D, Sennerby L, Meredith N. Influence of implant taper on the primary and secondary stability of osseointegrated titanium implants. *Clin Oral Implants Res* 2004;15:474-80. <https://doi.org/10.1111/j.1600-0501.2004.01041.x>
21. Javed F, Ahmed HB, Crespi R, Romanos GE. Role of primary stability for successful osseointegration of dental implants: factors of influence and evaluation. *Interv Med Appl Sci* 2013;5:162-7. <https://doi.org/10.1556/IMAS.5.2013.4.3>
22. Jang WW, Kang DW, Kim YK. Long-term evaluation of the prognosis of straight and tapered implant with resorbable blast media surface: retrospective clinical study. *Oral Biol Res* 2019;43:23-31. <https://doi.org/10.21851/obr.43.01.201903.23>
23. Chambrone L, Shibli JA, Mercúrio CE, Cardoso B, Preshaw PM. Efficacy of standard (SLA) and modified sandblasted and acid-etched (SLActive) dental implants in promoting immediate and/or early occlusal loading protocols: a systematic review of prospective studies. *Clin Oral Implants Res* 2015;26:359-70. <https://doi.org/10.1111/clr.12347>
24. van Velzen FJ, Ofec R, Schulten EA, Ten Bruggenkate CM. 10-Year survival rate and the incidence of peri-implant disease of 374 titanium dental implants with a SLA surface: a prospective cohort study in 177 fully and partially edentulous patients. *Clin Oral Implants Res* 2015;26:1121-8. <https://doi.org/10.1111/clr.12499>
25. Shi X, Xu L, Violin KB, Lu S. Improved osseointegration of long-term stored SLA implant by hydrothermal sterilization. *J Mech Behav Biomed Mater* 2016;53:312-9. <https://doi.org/10.1016/j.jmbbm.2015.08.038>
26. Lee JT, Cho SA. Biomechanical evaluation of laser-etched Ti implant surfaces vs. chemically modified SLA Ti implant surfaces: Removal torque and resonance frequency analysis in rabbit tibias. *J Mech Behav Biomed Mater* 2016;61:299-307. <https://doi.org/10.1016/j.jmbbm.2016.03.034>

How to cite this article: Jeon JH, Kim MJ, Yun PY, Jo DW, Kim YK. Randomized clinical trial to evaluate the efficacy and safety of two types of sandblasted with large-grit and acid-etched surface implants with different surface roughness. *J Korean Assoc Oral Maxillofac Surg* 2022;48:225-231. <https://doi.org/10.5125/jkaoms.2022.48.4.225>