



Sensory change after implant surgery: related factors for recovery

Joon-Ho Jung, Ji-Hoon Ko, Jeong-Kui Ku*, Jae-Young Kim, Jong-Ki Huh

Department of Oral and Maxillofacial Surgery, Gangnam Severance Hospital, Yonsei University College of Dentistry, Seoul, Korea

Abstract (J Korean Assoc Oral Maxillofac Surg 2022;48:297-302)

Objectives: This retrospective study aimed to analyze data on nerve damage in patients who complained of sensory changes after dental implant surgery, the clinical results according to proximity of the implant fixture to the inferior alveolar nerve (IAN) canal, and the factors affecting recovery of sensation.

Materials and Methods: The electronic medical records of 64 patients who had experienced sensory change after implant surgery were reviewed. Patients were classified by sex, age, implant installation sites, recovery rate and the distance between the implant fixture and IAN canal on computed tomography (CT). The distance was classified into Group I ($D > 2$ mm), Group II ($2 \text{ mm} \geq D > 0$ mm), and Group III ($D \leq 0$ mm).

Results: The 64 patients were included and the mean age was 57.3 ± 7.3 years. Among the 36 patients who visited our clinic more than two times, 21 patients (58.3%) reported improvement in sensation, 13 patients (36.1%) had no change in sensation, and 2 patients (5.6%) reported worsening sensation. In Group II, symptom improvement was achieved in all patients regardless of the removal of the implant fixture. In Group III, 8 patients (40.0%) had reported symptom improvement with removal of the implant fixture, and 2 patients (33.3%) of recovered patients showed improvement without removal. Removal of the implant fixture in Group III did not result in any significant difference in recovery ($P=0.337$), although there was a higher possibility of improvement in sensation in removal cases.

Conclusion: Clinicians first should consider removing the fixture when it directly invades the IAN canal. However, in cases of sensory change after dental implant surgery where the drill or implant fixture did not invade the IAN canal, other indirect factors such as flap elevation and damage due to anesthesia should be considered as causes of sensory change. Removal of the implant should be considered with caution in these situations.

Key words: Dental implant, Adverse effects, Inferior alveolar nerve, Sensation disorders, Prognosis

[paper submitted 2022. 8. 26 / revised 2022. 9. 30 / accepted 2022. 10. 3]

I. Introduction

The inferior alveolar nerve (IAN) is a branch of the trigeminal nerve responsible for sensation of the mandibular teeth, lower lip, and chin. IAN injuries can be caused by iatrogenicity due to anatomical variations, treatment based on improper

diagnosis, or unskilled performance during procedures such as surgical extraction of the mandibular third molar¹, dental implant surgery², root canal treatment³, IAN block anesthesia⁴, and orthognathic surgery⁵. Neuropathies like hypoesthesia, paresthesia, and dysesthesia may be present in patients with IAN injury. These symptoms can impair essential functions such as speech, swallowing, and mastication, reducing quality of life⁶. In addition, injuries to the IAN are rare but can potentially cause chronic neuropathic pain syndrome⁷.

A series of studies previously reported that the most frequent cause of injury to the IAN is surgical extraction of a mandibular third molar. However, as dental implant surgery has become more common, the incidence of related injury to the IAN has increased⁸. According to several recent studies, sensory changes after surgical extraction of a mandibular third molar occurred in 0.3%-8.4% of cases⁹, temporary sensory changes in 0.8%-5.7%¹⁰, and permanent sensory changes in 0.7%¹¹. In other studies on dental implant surgery, the frequency of sensory change due to injury to the IAN was re-

Jong-Ki Huh

Department of Oral and Maxillofacial Surgery, Gangnam Severance Hospital, Yonsei University College of Dentistry, 211 Eonju-ro, Gangnam-gu, Seoul 06273, Korea

TEL: +82-2-2019-4560

E-mail: omsuh@yuhs.ac

ORCID: <https://orcid.org/0000-0002-7381-3972>

*Current affiliation: Department of Oral and Maxillofacial Surgery, Research Institute of Clinical Medicine of Jeonbuk National University-Biomedical Research Institute of Jeonbuk National University Hospital, Jeonbuk National University School of Dentistry, Jeonju, Korea

© This is an open-access article distributed under the terms of the Creative Commons Attribution Non-Commercial License (<http://creativecommons.org/licenses/by-nc/4.0/>), which permits unrestricted non-commercial use, distribution, and reproduction in any medium, provided the original work is properly cited.

Copyright © 2022 The Korean Association of Oral and Maxillofacial Surgeons.

ported to be 0.0%-13.0%¹². The possibility of permanent sensory change after dental implant surgery was approximately 3.4 times higher than that occurring after surgical extraction of a mandibular third molar¹³. These results demonstrate the large impact of sensory changes after dental implant surgery.

Sensory changes after dental implant surgery can be caused by pressure on the IAN due to bone compression¹⁴ when the implant fixture is placed within 2 mm of the IAN canal or to hematoma formation due to dental implant surgery. Such nerve damage belongs to the neurapraxia type of Seddon and Sunderland's classification of nerve damage, and complete recovery of sensation can be expected. If over-drilling occurs during dental implant surgery or the implant fixture invades the IAN canal, nerve damage, such as axonotmesis or neurotmesis, can occur. Although some degree of sensory recovery can be expected, such an injury often results in permanent damage¹³. However, IAN block anesthesia or mental nerve injury due to flap elevation during dental implant surgery can also cause sensory change with the possibility of permanence^{4,15}.

In general, if sensory changes occur after dental implant surgery, a non-surgical approach such as medication should be used as treatment¹⁶. While several reports have suggested that the implant fixture be removed within 36 hours¹⁷, cases with sensory recovery without removal of the implant fixture have been reported¹⁶.

This study aimed to 1) analyze the data on nerve damage in patients who complained of sensory changes after dental implant surgery, 2) evaluate the prognosis of sensory changes according to proximity of the implant fixture to the IAN canal, and 3) identify the factors affecting recovery of sensation.

II. Materials and Methods

From 2011 to 2021, raw data of 293 patients who visited the Department of Oral and Maxillofacial Surgery at Gangnam Severance Hospital with sensory changes (hypoesthesia, paresthesia, dysesthesia, etc.) were collected from Yonsei Medical Center's Severance Open BIG data. In total, 64 patients satisfied the inclusion criteria. This retrospective study complied with the tenets of the Declaration of Helsinki and was approved by the Institutional Review Board (IRB) of Gangnam Severance Hospital (IRB approval No. 2021-0958-001).

The inclusion criteria were: (1) adult patients aged >19 years, 2) complaint of sensory changes after dental implant surgery of the mandible, and 3) computed tomography (CT) showing a relationship between dental implant surgery and the IAN canal. The exclusion criteria were: 1) patients with a medical history or syndrome associated with sensation, 2) patients with abnormal neural symptoms in the facial area before dental treatment, and 3) patients who complained of osteomyelitis of the jaw.

The data of 64 patients, including sex, age, implant surgery site, medication status, and whether the implant fixtures were removed or not, were examined through the electronic medical record. Based on the shortest distance (D) between the implant fixture or the drilling location and the IAN canal on CT images, the patients were classified into Group I ($D > 2$ mm), Group II ($2 \text{ mm} \geq D > 0$ mm), and Group III ($D \leq 0$ mm). (Fig. 1)

Among the 64 patients, 36 visited our clinic more than two times for symptoms of sensory change. For those 36 patients,

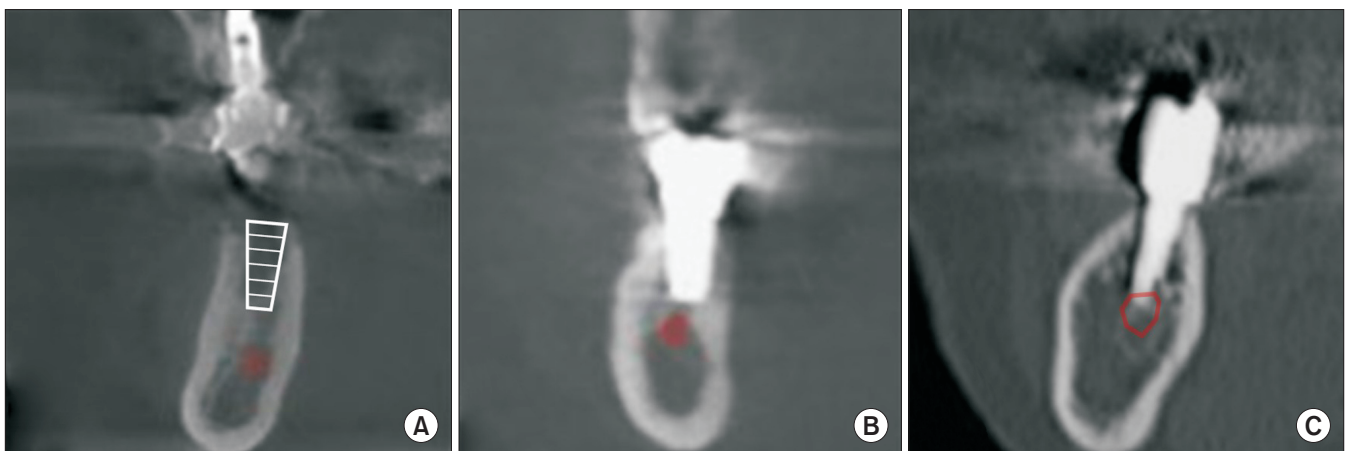


Fig. 1. Distance (D) between the implant fixture and the inferior alveolar nerve canal. A. Group I ($D > 2$ mm). B. Group II ($2 \text{ mm} \geq D > 0$ mm). C. Group III ($D \leq 0$ mm).

Joon-Ho Jung et al: Sensory change after implant surgery: related factors for recovery. J Korean Assoc Oral Maxillofac Surg 2022

Table 1. Demographic data of the patients

Variable	Value
Sex	
Male	20 (31.3)
Female	44 (68.8)
Age (yr)	
30-49	18 (28.1)
50-69	38 (59.4)
≥70	8 (12.5)
Location of the dental implant (No. of fixtures)	
Premolar	25
Molar	72

Values are presented as number (%) or number only.

Joon-Ho Jung et al: Sensory change after implant surgery: related factors for recovery. *J Korean Assoc Oral Maxillofac Surg* 2022

the degree of sensory change was subjectively evaluated using the visual analog scale (VAS). Improvement in sensation was defined by increased feeling during probing using an explorer in the lower lip and chin. Based on the evaluation criteria, patients who expressed improvement in sensation at least once were classified as ‘Improved,’ those who did not exhibit improvement were classified as ‘Stationary,’ and those who complained of worsened sensation were classified as ‘Aggravated.’

Statistical and analytical processing was performed using IBM SPSS Statistics (ver. 26; IBM, Armonk, NY, USA). Subjective recovery, difference in recovery period between Group II and Group III, and status of implant fixture removal and recovery in Group III were identified using the chi-square and Fisher’s exact tests. Statistical significance was defined as *P*-value of 0.05 or less.

III. Results

The patients included 44 females and 20 males. The age distribution ranged from 32-82 years, and the mean age was 57.3±7.3 years. Dental implant surgery associated with sensory changes was more frequent in the molar area (72 fixtures) than in the premolar area (25 fixtures), with the second molar being the most frequent site (27 fixtures).(Table 1)

A total of 31 patients (86.1%) received oral medication treatment with a steroid (Solondo; Yuhan, Seoul, Korea) and vitamin B (Beecom [Yuhan] and Vitamedin [CJ HealthCare, Seoul, Korea]). Implant fixtures were removed in 20 patients (55.6%).

Among the 36 patients who visited our clinic more than two times, 21 patients (58.3%) reported improvement in sensation, 13 patients (36.1%) had no change in sensation, and 2 patients (5.6%) reported worsening sensation. The mean time

Table 2. Comparison of demographic data between Group II and Group III

	Group II (n=12) (2 mm ≥ D > 0 mm)	Group III (n=21) (D ≤ 0 mm)	<i>P</i> -value
Sex			0.825
Male	3 (25.0)	6 (28.6)	
Female	9 (75.0)	15 (71.4)	
Age (yr)	52.17±11.86	58.24±12.13	0.617
Location			0.176
Pre-molar	3	10	
Molar	16	21	

(D: distance between the implant fixture or drilling location)

Values are presented as number (%), mean±standard deviation, or number only.

No significant difference was observed on Fisher’s exact test (*P*>0.05).

Joon-Ho Jung et al: Sensory change after implant surgery: related factors for recovery. *J Korean Assoc Oral Maxillofac Surg* 2022

Table 3. Recovery of patients according to radiographic proximity between the apex of the fixture and the inferior alveolar nerve canal in Group II and Group III

Distance (D)	Improved	Stationary	Aggravated	Total	<i>P</i> -value
Group II (2 mm ≥ D > 0 mm)	12	0	0	12	0.001
Group III (D ≤ 0 mm)	8	11	2	21	

Values are presented as number (%).

No significant difference was found on Fisher’s exact test (*P*=0.001).

Joon-Ho Jung et al: Sensory change after implant surgery: related factors for recovery. *J Korean Assoc Oral Maxillofac Surg* 2022

to subjective improvement in sensation was 172.9±76.7 days. All cases of improvement involved medication. Of the 15 patients whose sensation did not improve or worsened, 10 were treated with medication. Among them, 9 patients (60.0%) visited our clinic 6 months after the occurrence of sensory changes.

Radiographic images were available for 3, 12, and 21 patients in Group I, Group II, and Group III, respectively. In Group II, removal of the implant fixture was performed in 4 patients, while improvement in sensation was achieved in all patients regardless of such removal. In addition, improvement was observed within 6 months. Among the Group III patients, 8 patients (40.0%) reported improvement in sensation with removal of the implant fixture, 2 patients (33.3%) exhibited improvement without removal of the implant fixture, and most of them showed improvement within 6 months. However, 1 patient demonstrated improvement between 6 and 12 months.

In Group II and Group III, there were no significant differences based on the results of the chi-square test for site of implant surgery regarding cause, sex, age, and sensory change.

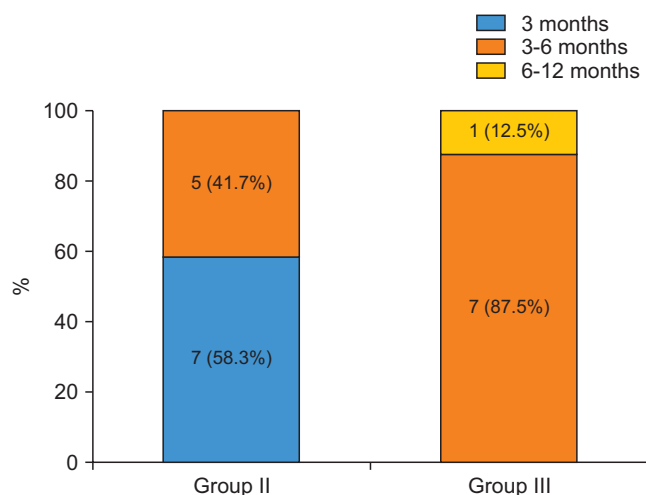


Fig. 2. Comparison of the recovery period between Group II and Group III. A significant difference was found on Fisher's exact test ($P=0.005$), and the tendency for earlier recovery was found in Group II. (Group II: $2\text{ mm} \geq D > 0\text{ mm}$, Group III: $D \leq 0\text{ mm}$, D: distance between the implant fixture or drilling location)

Joon-Ho Jung et al: Sensory change after implant surgery: related factors for recovery. J Korean Assoc Oral Maxillofac Surg 2022

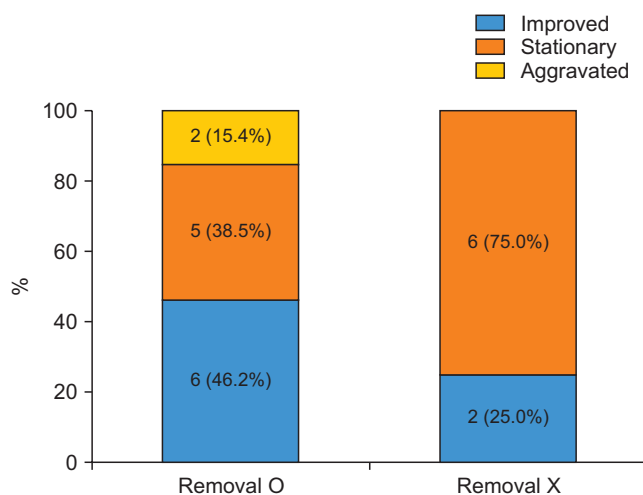


Fig. 3. Comparison of the recovery rate of Group III between removal and non-removal of implant fixtures. A significant difference was not found on Fisher's exact test ($P=0.337$), but there was a higher possibility of improvement in sensation in removal cases.

Joon-Ho Jung et al: Sensory change after implant surgery: related factors for recovery. J Korean Assoc Oral Maxillofac Surg 2022

(Table 2) There was a significant difference in the rate of sensory recovery between Group II and Group III ($P=0.001$). All patients in Group II exhibited improvement in sensation, but 13 of the 21 patients (61.9%) in Group III did not. (Table 3) In addition, the difference in recovery period between Group II and Group III was significant ($P=0.005$). In Group II, more than half (58.3%) of the improved patients demonstrated improvement within 3 months. However, in patients who showed improvement in Group III, almost all (87.5%) exhibited improvement between 3 and 6 months. (Fig. 2) In Group III, removing the implant fixture did not result in any significant difference in recovery of sensation ($P=0.337$), although it did increase the rate of improvement in sensation. (Fig. 3)

IV. Discussion

Based on the results, sensory changes after dental implant surgery were twice as common in females than in males, and middle-aged (50-69 years) individuals accounted for more than half (59.4%) of the sensory changes. Consistent with several studies, this result may be attributed to proximity of implant placement to the IAN canal because the mandible is smaller in women and the elderly¹⁸⁻²⁰. The most frequent site of sensory change after dental implant surgery is the mandibular second molar area, where the distance between the alveolar crest and the IAN canal is the shortest¹⁸. Therefore, professional diagnostic equipment such as CT must be used

to measure the distance between the path of the IAN canal and the alveolar bone crest accurately in order to perform ideal dental implant surgery in the mandibular second molar area.

In this study, it was assumed that the prognosis of sensory changes after dental implant surgery would be affected by proximity to the IAN canal. The proximity of the implant fixture or drilling location to the IAN canal significantly contributed to sensory recovery. In Group II without direct injury to the IAN, all patients exhibited improvement in sensation regardless of removal of the implant fixture. However, in Group III with direct injury to the IAN, there was a much lower possibility of improvement in sensation compared to Group II, even in cases of aggravation. In addition, for recovery period, Group II demonstrated an improvement in sensation within a much shorter period of time than Group III. This indicates that direct injury to the IAN canal increases not only the recovery period, but also the risk of permanent sensory changes.

Khawaja and Renton²¹ reported that early removal of an implant fixture invading the IAN canal could reduce the possibility of neuropathy. In addition, Juodzbaly et al.¹⁷ suggested that removal of an implant fixture invading the IAN canal be performed within 36 hours after dental implant surgery to prevent infection of the damaged nerve and to reduce the degree of nerve compression due to edema. In addition, direct application of steroids (dexamethasone) to the nerve damage site or oral administration of steroids in the early stages of

healing is recommended. This study also showed that removal of an implant fixture invading the IAN canal increased the possibility of improvement in sensation.

Several studies have mentioned that a safe distance of at least 2 mm should be maintained between the implant fixture or drilling location and the IAN canal during dental implant surgery in the mandible. They demonstrated that pressure on the IAN canal due to bone compression could occur at an implant fixture placed adjacent to the IAN canal^{14,18,22}. The results showed a relatively higher possibility of sensory change even without direct invasion of the IAN canal in Group II. Therefore, surgeons must consider a safe distance between the implant fixture and the IAN canal.

In addition, removal of the implant fixture should be carefully considered since a 100% improvement rate was observed in Group II in this study, even without fixture removal. As shown in the results, sensory changes occurred in Group I with a distance greater than 2 mm between the implant fixture or drilling location and the IAN canal, and there were several cases with no improvement. This indicates that sensory changes could occur after dental implant surgery through indirect factors such as nerve injury from block anesthesia (chemical injury, mechanical injury from the needle, etc.), damage to the mental nerve through flap elevation, or damage from releasing the incision of the mandibular gingiva. Therefore, clinicians must consider several factors that could cause sensory changes after dental implant surgery to establish a better treatment plan for nerve complications.

The limitations of this study were the small number of study participants and the difficulty in determining the extent of nerve complications and duration of damage. In addition, the absence of objective indicators for sensory recovery and medication treatment without discriminating between the groups are limitations. Further studies should be conducted with more patients and include objective indicators for measuring sensory changes.

V. Conclusion

When the implant fixture or drilling location directly invaded the IAN canal, there was a higher possibility of improvement in sensation when the implant fixture was removed. In cases where the drilling location or the implant fixture did not invade the IAN canal, the sensory change may not be permanent. In such cases, other indirect factors, such as flap elevation and damage by anesthesia, should be considered as the cause of sensory changes after dental implant surgery. Re-

moval of the implant fixture should be considered carefully in these instances.

In cases of sensory changes after dental implant surgery, clinicians must consider several factors that could cause sensory changes before removing an implant fixture such as distance between the implant fixture and the IAN canal on CT images.

ORCID

Joon-Ho Jung, <https://orcid.org/0000-0002-2880-2748>

Ji-Hoon Ko, <https://orcid.org/0000-0002-8263-2778>

Jeong-Kui Ku, <https://orcid.org/0000-0003-1192-7066>

Jae-Young Kim, <https://orcid.org/0000-0002-9423-438X>

Jong-Ki Huh, <https://orcid.org/0000-0002-7381-3972>

Authors' Contributions

J.H.J. and J.H.K. participated in data collection. J.H.J. wrote the manuscript. J.H.J., J.K.K., J.Y.K., and J.K.H. participated in the study design and performed the statistical analysis. J.K.K., J.Y.K., and J.K.H. participated in the coordination and helped to draft the manuscript. All authors read and approved the final manuscript.

Ethics Approval and Consent to Participate

This retrospective study was approved by the IRB of Gangnam Severance Hospital (approval No. 2021-0958-001), and the informed consent was waived by the IRB.

Conflict of Interest

No potential conflict of interest relevant to this article was reported.

References

1. Sarikov R, Juodzbaly G. Inferior alveolar nerve injury after mandibular third molar extraction: a literature review. *J Oral Maxillofac Res* 2014;5:e1. <https://doi.org/10.5037/jomr.2014.5401>
2. Juodzbaly G, Wang HL, Sabaly G, Sidlauskas A, Galindo-Moreno P. Inferior alveolar nerve injury associated with implant surgery. *Clin Oral Implants Res* 2013;24:183-90. <https://doi.org/10.1111/j.1600-0501.2011.02314.x>
3. López-López J, Estrugo-Devesa A, Jané-Salas E, Segura-Egea JJ. Inferior alveolar nerve injury resulting from overextension of an endodontic sealer: non-surgical management using the GABA analogue pregabalin. *Int Endod J* 2012;45:98-104. <https://doi.org/10.1111/j.1365-2591.2011.01939.x>
4. Pogrel MA. Permanent nerve damage from inferior alveolar nerve

- blocks: a current update. *J Calif Dent Assoc* 2012;40:795-7.
5. Phillips C, Essick G. Inferior alveolar nerve injury following orthognathic surgery: a review of assessment issues. *J Oral Rehabil* 2011;38:547-54. <https://doi.org/10.1111/j.1365-2842.2010.02176.x>
 6. Yekta SS, Koch F, Grosjean MB, Esteves-Oliveira M, Stein JM, Ghassemi A, et al. Analysis of trigeminal nerve disorders after oral and maxillofacial intervention. *Head Face Med* 2010;6:24. <https://doi.org/10.1186/1746-160X-6-24>
 7. Pigg M. Chronic intraoral pain--assessment of diagnostic methods and prognosis. *Swed Dent J Suppl* 2011;(220):7-91.
 8. Choi YC, Kwon JS, Kim ST, Ahn HJ. Analysis of patients with dysesthesia after mandibular nerve injury. *J Oral Med Pain* 2009;34:379-85.
 9. Leung YY, Fung PP, Cheung LK. Treatment modalities of neurosensory deficit after lower third molar surgery: a systematic review. *J Oral Maxillofac Surg* 2012;70:768-78. <https://doi.org/10.1016/j.joms.2011.08.032>
 10. Kim JW, Cha IH, Kim SJ, Kim MR. Which risk factors are associated with neurosensory deficits of inferior alveolar nerve after mandibular third molar extraction? *J Oral Maxillofac Surg* 2012;70:2508-14. <https://doi.org/10.1016/j.joms.2012.06.004>
 11. Kjølle GK, Bjørnland T. Low risk of neurosensory dysfunction after mandibular third molar surgery in patients less than 30 years of age. A prospective study following removal of 1220 mandibular third molars. *Oral Surg Oral Med Oral Pathol Oral Radiol* 2013;116:411-7. <https://doi.org/10.1016/j.oooo.2013.06.024>
 12. Burstein J, Mastin C, Le B. Avoiding injury to the inferior alveolar nerve by routine use of intraoperative radiographs during implant placement. *J Oral Implantol* 2008;34:34-8. [https://doi.org/10.1563/1548-1336\(2008\)34\[34:AITTIA\]2.0.CO;2](https://doi.org/10.1563/1548-1336(2008)34[34:AITTIA]2.0.CO;2)
 13. Steinberg MJ, Kelly PD. Implant-related nerve injuries. *Dent Clin North Am* 2015;59:357-73. <https://doi.org/10.1016/j.cden.2014.10.003>
 14. Greenstein G, Carpentieri JR, Cavallaro J. Nerve damage related to implant dentistry: incidence, diagnosis, and management. *Comp Contin Educ Dent* 2015;36:652-9; quiz 660.
 15. Velasco-Torres M, Padiál-Molina M, Avila-Ortiz G, García-Delgado R, Catena A, Galindo-Moreno P. Inferior alveolar nerve trajectory, mental foramen location and incidence of mental nerve anterior loop. *Med Oral Patol Oral Cir Bucal* 2017;22:e630-5. <https://doi.org/10.4317/medoral.21905>
 16. Jang SI, Paeng JY. Non-surgical management of inferior alveolar nerve damage after implant installation. *J Dent Implant Res* 2018;37:18-22. <https://doi.org/10.54527/jdir.2018.37.1.18>
 17. Juodzbalys G, Wang HL, Sabalys G. Injury of the inferior alveolar nerve during implant placement: a literature review. *J Oral Maxillofac Res* 2011;2:e1. <https://doi.org/10.5037/jomr.2011.2101>
 18. Greenstein G, Tarnow D. The mental foramen and nerve: clinical and anatomical factors related to dental implant placement: a literature review. *J Periodontol* 2006;77:1933-43. <https://doi.org/10.1902/jop.2006.060197>
 19. Voon YS, Patil PG. Safe zone in anterior mandible related to the genial tubercle for implant osteotomy in a Chinese-Malaysian population: a CBCT study. *J Prosthet Dent* 2018;119:568-73. <https://doi.org/10.1016/j.prosdent.2017.05.011>
 20. Helmi MF, Huang H, Goodson JM, Hasturk H, Tavares M, Natto ZS. Prevalence of periodontitis and alveolar bone loss in a patient population at Harvard School of Dental Medicine. *BMC Oral Health* 2019;19:254. <https://doi.org/10.1186/s12903-019-0925-z>
 21. Khawaja N, Renton T. Case studies on implant removal influencing the resolution of inferior alveolar nerve injury. *Br Dent J* 2009;206:365-70. <https://doi.org/10.1038/sj.bdj.2009.258>
 22. Du Toit J, Gluckman H, Gamil R, Renton T. Implant injury case series and review of the literature part 1: inferior alveolar nerve injury. *J Oral Implantol* 2015;41:e144-51. <https://doi.org/10.1563/aaid-joi-D-14-00022>

How to cite this article: Jung JH, Ko JH, Ku JK, Kim JY, Huh JK. Sensory change after implant surgery: related factors for recovery. *J Korean Assoc Oral Maxillofac Surg* 2022;48:297-302. <https://doi.org/10.5125/jkaoms.2022.48.5.297>