



# What do we know about uncommon complications associated with third molar extractions? A scoping review of case reports and case series

Naichuan Su<sup>1</sup>, Sana Harroui<sup>1</sup>, Fred Rozema<sup>2,3</sup>, Stefan Listl<sup>4,5</sup>, Jan de Lange<sup>3</sup>, Geert J.M.G. van der Heijden<sup>1</sup>

<sup>1</sup>Department of Oral Public Health, Academic Center for Dentistry Amsterdam (ACTA), University of Amsterdam and Vrije Universiteit Amsterdam, Amsterdam, <sup>2</sup>Department of Oral Medicine, Academic Center for Dentistry Amsterdam (ACTA), University of Amsterdam and Vrije Universiteit Amsterdam, Amsterdam, <sup>3</sup>Department of Oral and Maxillofacial Surgery, Amsterdam University Medical Center (UMC), Academic Center for Dentistry Amsterdam (ACTA), University of Amsterdam and Vrije Universiteit Amsterdam, Amsterdam, <sup>4</sup>Radboud Institute for Health Sciences, Radboud University Nijmegen Medical Center, Nijmegen, The Netherlands, <sup>5</sup>Department of Conservative Dentistry, Section for Translational Health Economics, Heidelberg University Hospital, Heidelberg, Germany

**Abstract** (J Korean Assoc Oral Maxillofac Surg 2023;49:2-12)

The current study aimed to explore the types and frequencies of uncommon complications associated with third molar extractions based on a scoping review of case reports and case series. The study used an electronic literature search based on PubMed and Embase up to March 31, 2020, with an update performed on October 22, 2021. Any case reports and case series that reported complications associated with third molar extractions were included. The types of complications were grouped and the main symptoms of each type of complication were summarized. A total of 51 types of uncommon complications were identified in 248 patients from 186 studies. Most types of complications were post-operative. In the craniofacial and cervical regions, the most frequent complications included iatrogenic displacement of the molars or root fragments in the craniofacial area, late mandibular fracture, and subcutaneous emphysema. In other regions, the most frequent complications include pneumomediastinum, pneumorrhachis, pneumothorax, and pneumopericardium. Of the patients, 37 patients had life-threatening uncommon complications and 20 patients had long-term/irreversible uncommon complications associated with third molar extractions. In conclusion, a variety of uncommon complications associated with third molar extractions were identified. Most complications occurred in the craniofacial and cervical regions and were mild and transient.

**Key words:** Uncommon complications, Third molar, Tooth extraction, Case reports, Review

[paper submitted 2022. 7. 14 / revised 2022. 8. 27 / accepted 2022. 8. 29]

## I. Introduction

Third molar extraction is one of the most frequent procedures undertaken in the National Health Service in the UK<sup>1</sup>. In the US, it has been reported that 10 million impacted third molars were extracted from approximately 5 million people each year at an annual cost of over US\$ 3 billion<sup>2</sup>. Prophylactic extraction of asymptomatic impacted teeth is one of the most common reasons for the extraction<sup>3-5</sup>. It has been report-

ed that prophylactic extraction can prevent possible pathologies such as caries and root resorption of adjacent teeth, periodontitis, gingivitis, periodontal disease, and the development of cysts or tumors<sup>6</sup>, and can also remove a cause of crowding of the dentition<sup>7</sup>. In some Western countries, the prophylactic extraction of asymptomatic third molars has long been considered “appropriate care”<sup>4,8</sup>. It has been shown that about 85% of third molar extractions in Australia<sup>5</sup> and 44% in the UK<sup>8</sup> are likely to be prophylactic. However, a Dutch clinical guideline for third molars recommends more conservative strategies than preventive surgeries for asymptomatic molars that are fully bone impacted, fully erupted, and functional with good cleaning, or that have a close anatomical relationship with the mandibular nerve canal<sup>9</sup>. Another reason for the extraction of third molars is when they are symptomatic or have already caused diseases, such as pain associated with infection, dental caries, or altered periodontal health of the adjacent teeth<sup>3,10</sup>. The extraction of third molars is also con-

### Naichuan Su

Department of Oral Public Health, Academic Center for Dentistry Amsterdam (ACTA), University of Amsterdam and Vrije Universiteit Amsterdam, 5F, Gustav Mahlerlaan 3004, 1081 LA Amsterdam, The Netherlands  
TEL: +31-205980484

E-mail: n.su@acta.nl

ORCID: <https://orcid.org/0000-0001-8034-9410>

© This is an open-access article distributed under the terms of the Creative Commons Attribution Non-Commercial License (<http://creativecommons.org/licenses/by-nc/4.0/>), which permits unrestricted non-commercial use, distribution, and reproduction in any medium, provided the original work is properly cited.

Copyright © 2023 The Korean Association of Oral and Maxillofacial Surgeons.

sidered to be indicated when the molars may interfere with planned prosthodontic, orthodontic, or surgical treatments<sup>10</sup>.

Several previous studies have reported common complications associated with third molar extractions<sup>11-15</sup>. The prevalence of the complications ranged from 4.6% to 30.9% in one previous study<sup>11</sup>. Approximately 10% of patients of third molar extractions, have sought post-surgical emergency appointments<sup>12,13</sup>. The complications may occur intraoperatively or postoperatively. The most common intraoperative complications included bleeding, damage to adjacent teeth, injury to surrounding tissues, displacement of teeth into adjacent spaces, and fracture of the root<sup>14</sup>, while the most common postoperative complications included dry socket, pain, swelling, trismus, infection, and hemorrhage<sup>15</sup>. These complications have been well-known and well-documented in both research and clinical practice.

In clinical practice, weighing the risks and benefits associated with the extraction of third molars is an important task for both patients and clinicians when they make decisions. Before any surgical procedures, the patient should be provided with full information on the pros and cons of surgery, as well as perioperative risks and postoperative complications, including the potential for any uncommon complications<sup>11</sup>. Additionally, while most clinicians already have an in-depth understanding of common complications, there is an urgent need to increase the clinicians' awareness of possible uncommon complications because such knowledge may help clinicians recognize complications early to ensure adequate therapy<sup>16</sup> and to optimize the clinical management of third molar extraction.

To date, multiple case reports or case series reported different uncommon complications. Brauer<sup>16</sup> conducted a systematic review to summarize possible uncommon complications, which included abscess formation, displacement of teeth and instruments, asphyxia death, life-threatening hemorrhage, brain abscess, epidural abscess, benign paroxysmal positional vertigo, subcutaneous and tissue space emphysema, subdural empyema, and herpes zoster syndrome. Even if those complications were very rare, they could be clinically important and could have devastating outcomes. To the best of our knowledge however, the review from Brauer<sup>16</sup> was the only one that focused on uncommon complications of third molar extractions to date. Their review only summarized uncommon complications based on 22 studies through 2008. However, there were more cases with uncommon complications reported since then, and some of the complications were newly identified<sup>17-19</sup>. Therefore, an up-to-date summary of

uncommon complications is needed.

The aim of the present study is to explore the types and frequencies of uncommon complications associated with third molar extractions based on a scoping review of case reports and case series.

## II. Materials and Methods

The scoping review was carried out based on the Preferred Reporting Items for Systematic Reviews and Meta-Analyses Extension for Scoping Reviews (PRISMA-ScR) checklist<sup>20</sup>.

### 1. Search strategy

Relevant publications were searched in electronic bibliographic sources, including PubMed and Embase, without language restriction, up to March 31, 2020 and an update of the search was performed on October 22, 2021. A combination of free text words and systematic vocabulary (MeSH [Medical Subject Headings] for PubMed and Emtree terms for Embase) relevant to "case report/series", "third molar", "teeth extraction", and "complication" was used in the search strategies. The search strategy is presented in Supplementary Table 1.

To improve the comprehensiveness of the search and identify potentially eligible studies that were not retrieved from the databases, hand searching was used<sup>21</sup>. That is, all the references cited in the studies eligible for inclusion were inspected (backward citation searching). The hand searching was performed via PubMed from November 2 to 8, 2021 by N.S.

### 2. Eligibility criteria

The publications that met the following criteria were included:

(1) They included patients who underwent simple or surgical extraction of third molar(s), regardless of age, sex, nationality, race, educational level, occupation, and characteristics of the molar. A simple extraction means that the tooth was visible above the gingiva and could be removed in one piece. A surgical extraction meant that the tooth was not visible in the oral cavity and the extraction could involve the removal of gingival tissue, bone, or both. In surgical extractions, the tooth could be removed in pieces.

(2) They reported complication(s) associated with third molar extractions. The complications could be preoperative,

intraoperative, or postoperative. Preoperative complications were defined as complications identified during anesthesia before extraction. Intraoperative complications were defined as complications identified during an extraction procedure. Postoperative complications were defined as complications identified after a third molar extraction.

(3) They were case reports or case series because both play a prominent role in rare diseases or rare complications in terms of their recognition and full description<sup>22</sup>. A case report was defined as a detailed report for observation of a patient that included uncommon complication(s) associated with a third molar extraction<sup>23</sup>. A case series was defined as a group or series of case reports in which only patients with uncommon complications were sampled<sup>23</sup>.

When the full text of a publication was not available, the publication also could have been included if the abstract of the publication provided sufficient information to determine that it met the eligibility criteria.

The publications that met the following criteria were excluded:

- (1) Duplicate publications.
- (2) Published before 1990.
- (3) Written in a language other than English.

Two reviewers (N.S. and S.H.) independently assessed the titles and abstracts of all the identified studies from the electronic searches. Full texts were obtained for studies that met the eligibility criteria, or where a clear decision could not be made from the titles and abstracts alone. In the latter case, the selection was based on the full-text reading. Any disagreement between the reviewers was resolved by a consensus discussion. One reviewer (N.S.) screened the titles, abstracts, and full texts of all the identified studies from the hand searching.

### 3. Data charting

For all the included studies, the variables, which were charted using a standardized form, included characteristics from the following four domains: the study, the patient, the extracted third molar associated with the complication(s), and the complication(s) associated with the third molar extraction.

The study characteristics included the name of the first authors, publication years, number of included patients, and the countries where the studies were performed. The patient characteristics included age, sex, and history of general health. The characteristics of the extracted third molars that

were associated with complications included the location of the molars (maxillary vs mandibular, and left vs right), impaction status of the molars (impacted vs unimpacted), and symptoms of the molars (asymptomatic vs symptomatic). The characteristics of the complications included the names of the complications, severity of the complications (life-threatening vs non-life-threatening), impact of the complications on the patients (transient vs long-term/irreversible), the timing of the complications (pre-, intra-, or postoperative), and locations where the complications occurred (craniofacial and cervical vs other regions). The severity and impact of the complications were determined based on the information reported in the included studies, other previous literature, and the reviewers' clinical knowledge. The details of the categorization of the variables are presented in Table 1.

The variables were charted by two reviewers (N.S. and S.H.). One reviewer charted the variables from half of the included studies and the other reviewer charted the other half. Then, the two reviewers cross-checked the charted variables. Any disagreement between the reviewers was resolved by a consensus discussion.

### 4. Statistical analysis

The types of complications reported in the included studies were grouped and the main symptoms of each type of complication were summarized. The patients with reported life-threatening complications and the patients with the long-term/irreversible impact caused by complications associated with third molar extractions were summarized.

## III. Results

The initial search identified a total of 473 records from PubMed and Embase. During the screening of titles and abstracts, 203 of them met the eligibility criteria and were included for the subsequent full-text review. Another 73 records were identified for full-text review from the hand searching. During the screening of full-texts, 90 studies did not meet the eligibility criteria and were eventually excluded. Therefore, a total of 186 studies were included for the subsequent analysis in the present study.(Fig. 1) The 186 studies were from 30 countries, most of which were from the US (n=28), Turkey (n=23), the UK (n=15), Brazil (n=14), and Japan (n=14). In the 186 studies, five had no available full text option and were included as abstracts only.

A total of 248 patients were included in the study. Of the

**Table 1.** Characteristics of the included patients, their extracted third molars, and associated complications

Variable	Category	Total sample size (n=248)	Patients with life-threatening complications (n=37)	Patients with long- term/irreversible complications (n=20)
Patient characteristics				
Age (yr)		34±14	36±15	35±16
Sex	Female	124 (50.0)	16 (43.2)	14 (70.0)
	Male	121 (48.8)	21 (56.8)	6 (30.0)
	Unknown	3 (1.2)	0 (0)	0 (0)
Reported history of disease	No	215 (86.7)	21 (56.8)	13 (65.0)
	Yes <sup>1</sup>	33 (13.3)	16 (43.2)	7 (35.0)
Characteristics of the extracted third molars with the complications				
Location of the molars	Maxilla	48 (19.4)	10 (27.0)	4 (20.0)
	Mandible	185 (74.6)	18 (48.6)	12 (60.0)
	Unknown	15 (6.0)	9 (24.3)	4 (20.0)
Location of the molars	Left	114 (46.0)	16 (43.2)	9 (45.0)
	Right	119 (48.0)	14 (37.8)	9 (45.0)
	Both sides	9 (3.6)	3 (8.1)	2 (10.0)
	Unknown	6 (2.4)	4 (10.8)	0 (0)
	Unimpacted	15 (6.0)	3 (8.1)	0 (0)
Impaction status of the molars	Impacted	108 (43.5)	7 (18.9)	5 (25.0)
	Unknown	125 (50.4)	27 (73.0)	15 (75.0)
Symptoms of the molars	Asymptomatic	15 (6.0)	1 (2.7)	0 (0)
	Symptomatic	47 (19.0)	7 (18.9)	4 (20.0)
	Unknown	186 (75.0)	29 (78.4)	16 (80.0)
The characteristics of complications				
Severity of complications	Non-life-threatening	211 (85.1)	-	17 (85.0)
	Life-threatening	37 (14.9)	-	3 (15.0)
Impact of complications	Transient	228 (91.9)	34 (91.9)	-
	Long-term or irreversible	20 (8.1)	3 (8.1)	-
Timing of complications	Preoperative	16 (6.5)	0 (0)	1 (5.0)
	Intraoperative	94 (37.9)	0 (0)	6 (30.0)
	Postoperative	138 (55.6)	37 (100)	13 (65.0)
Location of complications	Craniofacial and cervical	209 (84.3)	21 (56.8)	18 (90.0)
	Other regions	39 (15.7)	16 (43.2)	2 (10.0)

<sup>1</sup>Two patients were pregnant.

Values are presented as mean±standard deviation or number (%).

Naichuan Su et al: What do we know about uncommon complications associated with third molar extractions? A scoping review of case reports and case series. *J Korean Assoc Oral Maxillofac Surg* 2023

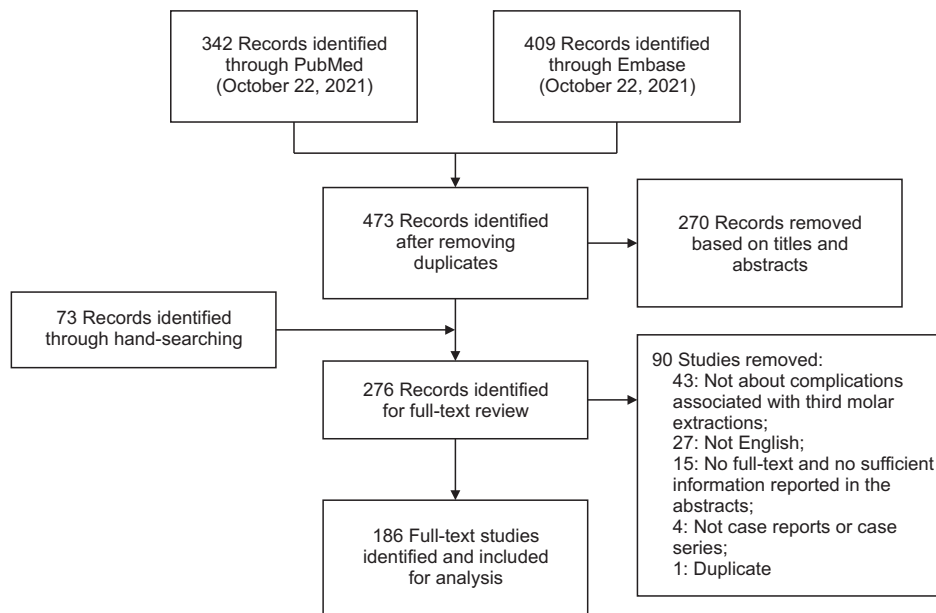
patients, 124 patients (50.0%) were female and 121 patients (48.8%) were male. The sex of the other three patients was not reported. The mean age±standard deviation (SD) of the patients was 34±14 years. The history of disease was reported in 31 patients, such as diabetes, hypertension, ischemic stroke, depression, B-type hepatitis, polycystic ovarian syndrome, grand-mal epilepsy, rheumatoid arthritis, leflunomide-induced pancytopenia, lung transplant, and extensive arteriovenous malformation. Two patients were pregnant when their third molars were extracted. Postoperative complications were identified in most of the included patients (55.6%), while intraoperative and preoperative complications were identified in 37.9% and 6.5% of the patients, respectively. The postoperative complications were identified from 0 to 3 years after the third molar extractions. Most of the identified complications were not life-threatening and only had a transient impact on patients. The characteristics of the included

patients, their extracted third molars, and associated complications are presented in Table 1.

### 1. Craniofacial and cervical complications

Most of the reported complications were identified in the craniofacial and cervical regions. Among the complications, most of them were postoperative and associated with the extraction of mandibular third molars. Table 2 summarizes the complications in the craniofacial and cervical regions.

Preoperative complications were identified in 15 patients. All the identified preoperative complications were visual disturbances. The most frequent complication was transient diplopia, which was identified in nine patients. The transient diplopia was identified as IANB (inferior alveolar nerve block anesthesia) in four patients and as PSAN (posterior superior alveolar nerve block) in five patients.



**Fig. 1.** Flow diagram of study inclusion. Naichuan Su et al: What do we know about uncommon complications associated with third molar extractions? A scoping review of case reports and case series. J Korean Assoc Oral Maxillofac Surg 2023

Intraoperative complications were identified in 93 patients. In terms of the extraction of mandibular third molars, the most frequent complication was iatrogenic displacement of third molars or root fragments in the craniofacial spaces (n=41), such as the submandibular (n=14), sublingual (n=11), or pterygomandibular (n=8) spaces. The second most frequent complication was iatrogenic mandibular (angle) fracture, which was identified in 18 patients. With respect to the extraction of maxillary third molars, iatrogenic displacement of third molars or root fragments in the craniofacial spaces was the most frequently identified complication, which was identified in 18 patients. The most frequent place in which the maxillary third molars or root fragments were displaced was the infratemporal fossa, which was identified in 11 of the 18 patients.

Postoperative complications were identified in 128 patients. In terms of the extraction of mandibular third molars, the most frequent complication was late mandibular fracture, which was identified in 37 patients. Late mandibular fracture occurred due to improper surgical performance (iatrogenic) (n=33) or to osteomyelitis (n=4) that was associated with the third molar extractions. The second most frequent complication was subcutaneous emphysema in the orofacial and cervical region, which was identified in 22 patients. In 18 patients, subcutaneous emphysema was not limited to the facial and cervical region but extended to the thorax. The third most frequent complication was osteomyelitis of the mandible, which was identified in nine patients. Among the nine patients, four developed a secondary late fracture of the mandible. In terms

of the extraction of maxillary third molars, the most frequent complication was infection and/or abscess in the craniofacial and cervical region, such as in the periorbital, buccal, and paranasal regions, which was identified in six patients.

## 2. Complications in other regions

Compared with complications in the craniofacial and cervical regions, complications in other regions associated with third molar extractions were less common. Among the complications in other regions, most of them were postoperative and associated with the extraction of mandibular third molars. Table 3 summarizes the complications in other regions.

In one patient a preoperative complication was identified as recurrent aspiration pneumonia due to bilateral-associated laryngeal paralysis after general anesthesia for a third molar extraction. An intraoperative complication, aspiration of the tooth into the bronchus of the lung when the mandibular third molar was extracted, was identified in another patient. Postoperative complications were identified in most patients with complications in other regions. With respect to the extraction of mandibular third molars, the most frequent postoperative complications were pneumomediastinum (air in the mediastinum), pneumorrhachis (air in the spinal epidural space), pneumothorax (air in the pleural space between lung and chest wall), and pneumopericardium (air in the pericardial cavity), which were identified in 18 patients. Among those complications, the most frequently identified complication was pneumomediastinum, which occurred in 17 patients.

**Table 2.** Summary of the uncommon complications associated with third molar extractions in the craniofacial and cervical regions

Complications	No. of patients <sup>1</sup>	Main complaints	Location of the extracted third molar that caused the complications
Preoperative	15		
Transient diplopia due to IANB or PSAN block	9	Double vision, blurry vision, inability to abduct eyeballs	Maxilla: 5 Mandible: 4
Transient loss of vision after IANB	2	Blindness	Maxilla: 2 Mandible: 0
Branch retinal artery occlusion	1	Painless sudden visual loss and blurred vision	Unknown: 1
Other ophthalmic complications after IANB or Gow-Gates injection	6	Blanching of skin in facial, infraorbital, buccal or palatal region, numbness in infraorbital region, amaurosis, ophthalmoplegia, upper eyelid ptosis, and mydriasis	Maxilla: 6 Mandible: 0
Intraoperative	93		
Iatrogenic displacement of the tooth or root fragments into the craniofacial and cervical area	59	Orofacial pain, limitation of mouth opening, orofacial swelling, and difficulty in swallowing	Maxilla: 18 Mandible: 41
Iatrogenic mandibular (angle) fracture	17	Orofacial pain, cracking sound, limitation of mouth opening, and paresthesia of lower lip	Maxilla: 0 Mandible: 17
Iatrogenic mandibular nerve injury (lingual nerve, mandibular alveolar neurovascular bundle, and inferior alveolar nerve)	7	Pain, paresthesia and dysesthesia in tongue, lower lip or chin, and taste loss	Maxilla: 0 Mandible: 7
Iatrogenic breakage and/or migration of a dental tool in the craniofacial area	7	Orofacial pain, limitation of mouth opening, and orofacial swelling	Maxilla: 0 Mandible: 7
Styloid fracture	1	Ear bleeding, dysphagia, orofacial pain, limitation of mouth opening, otalgia, tinnitus, and temporomandibular joint pain	Maxilla: 0 Mandible: 1
Maxillary tuberosity fracture	1	Bleeding from nasal cavity and swelling and ecchymosis of the cheek and buccal mucosa	Maxilla: 1 Mandible: 0
External auditory canal injury	1	Ear bleeding, limitation of mouth opening, mild swelling, tearing of the external auditory canal soft tissue, and crust formation	Maxilla: 0 Mandible: 1
Postoperative	128		
Late mandibular fracture	37	Pain, cracking sound, tenderness, altered occlusion, trismus, and swelling in the mandibular region, and paresthesia of the lower lip and mental region	Maxilla: 0 Mandible: 37
Subcutaneous emphysema in orofacial and cervical region	27	Facial and cervical swelling with crepitus, facial and cervical pain, difficulty in swallowing	Maxilla: 4 Mandible: 22 Unknown: 1
Infection/abscess in the craniofacial and neck region	17	Orofacial and neck pain, orofacial swelling, trismus, limitation of mouth opening, fever, and erythema	Maxilla: 6 Mandible: 7 Unknown: 4
Osteomyelitis of the mandible	9	Trismus, orofacial pain and swelling, tenderness on masseter muscles, and fever	Maxilla: 0 Mandible: 9
Severe orofacial hemorrhage	6	Intraoral bleeding, orofacial swelling, and vomiting blood	Maxilla: 2 Mandible: 4
Facial or carotid artery pseudoaneurysm	5	Growing and pulsating swelling in orofacial region, and bleeding	Maxilla: 1 Mandible: 4
Myositis ossificans of masticatory muscles	4	Progressive limitation of mouth opening, dull pain and muscle tenderness, pain exacerbated with chewing, and swelling	Maxilla: 1 Mandible: 3
Facial hematoma	3	Facial pain and swelling	Maxilla: 3 Mandible: 0
A delayed paresthesia of inferior alveolar nerve	3	Alteration of sensitivity of chin and lower lip	Maxilla: 0 Mandible: 3
Brain abscess	3	Severe headache, fever, and tachycardia	Maxilla: 1 Mandible: 0 Unknown: 2
Meningitis or meningoencephalitis	2	Severe headache, fever, neck rigidity, and mental status changes	Maxilla: 1 Mandible: 0 Unknown: 1
Fulminant mucormycosis of maxillary sinuses	2	Headache, blurred vision, pain and swelling in posterior maxilla, proptosis of globe, ophthalmoplegia, nasal sanguineous discharge, and nausea	Maxilla: 2 Mandible: 0
Ludwig's angina (fulminating infection of the neck involving deeper fascial spaces)	2	Pain and swelling in orofacial and cervical regions, trismus, fever, pain on swallowing and dysphagia	Maxilla: 0 Mandible: 2
Temporomandibular disorders	2	Pain, swelling, and numbness in joints, and limitation of mouth opening,	Maxilla: 0 Mandible: 2

**Table 2.** Continued

Complications	No. of patients <sup>1</sup>	Main complaints	Location of the extracted third molar that caused the complications
Traumatic changes (neuroma) of the inferior alveolar nerve	2	Hyperesthesia and paresthesia in mandible regions and lower lip, and orofacial pain	Maxilla: 0 Mandible: 2
Sensorineural hearing loss	2	Pain with a hearing loss	Unknown: 2
Anterior ischemic optic neuropathy	1	Painless visual loss	Maxilla: 0 Mandible: 1
Nonfatal cerebral air embolism	1	Generalized epileptic status	Maxilla: 0 Mandible: 1
Benign aggressive follicular lymphoid hyperplasia	1	Diffuse swelling in the maxilla region	Maxilla: 1 Mandible: 0
Temporal giant cell arteritis	1	Progressive visual alteration until blindness, orofacial and eye pain, and localized headache	Maxilla: 1 Mandible: 0
Retrobulbar hemorrhage	1	Intermittent blurriness, double vision, and orofacial pain	Maxilla: 1 Mandible: 0
Chronic cavernous sinus thrombophlebitis	1	Facial pain, fever, severe headache with diplopia, left sixth nerve palsy, nausea, vomiting, right eye ptosis and proptosis, bilateral ophthalmoplegia, conjunctival edema, and a dilated pupil	Maxilla: 1 Mandible: 0
Secondary benign paroxysmal positional vertigo	1	Intense vertigo and nausea on turning the head	Unknown: 1
Subdural empyema and herpes zoster oticus (Ramsay Hunt syndrome)	1	Bell's palsy, vesicles on external auditory meatus, facial pain and swelling, vomiting, trismus, fever, severe frontal headache, drowsiness, hemiparesis, and focal seizures	Unknown: 1
Transient contralateral hypoglossal nerve palsy due to general anesthesia	1	Difficulty in swallowing, and tongue deviation on protrusion	Maxilla: 0 Mandible: 1
Herpetic gingivostomatitis with mental nerve neuropathy	1	Febrile and irritation pain in the oral cavity, numbness in the lower lip and mental skin area, and erythematous lesions in the retromolar mucous membranes	Maxilla: 0 Mandible: 1
Delay-onset chronic and antibiotic-resistant wound infection	1	Swelling and pain around the extraction site and the adjacent cheek	Maxilla: 0 Mandible: 1
Incomplete peripheral facial palsy	1	Facial palsy, and weakness in the facial muscles	Maxilla: 0 Mandible: 1
Transient diplopia due to post-extraction hemorrhage	1	Double vision and blurry vision	Maxilla: 1 Mandible: 0

<sup>1</sup>Sum of the complications may be not equal because some patients may have more than one complication.

Naichuan Su et al: What do we know about uncommon complications associated with third molar extractions? A scoping review of case reports and case series. J Korean Assoc Oral Maxillofac Surg 2023

Pneumothorax was the second most frequently identified complication, occurring in four patients. The reported postoperative complications associated with maxillary third molar extractions were very rare. Only two patients were reported to have pneumomediastinum, pneumothorax, or pneumopericardium, and another patient was reported to have mediastinitis.

### 3. Life-threatening complications

Of the 248 included patients, life-threatening complications were identified in 37 patients, of which 21 patients were males and 16 patients were females (Supplementary Table 2). The mean age±SD of the 37 patients was 36±15 years. The summary of the characteristics of the 37 patients are presented in Table 1. The most commonly reported life-threatening complications included severe abscess/infection, mediastini-

tis, and massive hemorrhage.

Among the 37 patients with life-threatening complications, a total of three patients died due to a third molar extraction. Two patients died from asphyxia resulting from airway obstruction caused by hematoma after extraction of a mandibular third molar. Both of the patients were males, in their 70s, and had liver cirrhosis, as determined by their autopsies. Another patient died from a bilateral brain abscess after extraction of a third molar. The patient was a 25-year-old female. The patient had partial ornithine transcarbamylase deficiency (OTCD) and was in post-resection status for an embryonal sarcoma of the liver. The reported main reason for the death was that the local formation of ammonia in the brain abscesses combined with acute metabolic decompensation in the setting of OTCD due to infection contributed to the exacerbation of brain edema and irreversible encephalopathy. This caused rapid deterioration and progressive decline of the

**Table 3.** Summary of uncommon complications associated with third molar extractions in other regions

Complications	No. of patients	Main complaints	Location of the extracted third molar that caused the complications
Preoperative	1		
Recurrent aspiration pneumonia due to bilateral associated laryngeal paralysis after general anesthesia	1	Hoarseness, difficulty swallowing, and tongue deviated towards one side upon protrusion	Maxilla: 0 Mandible: 1
Intraoperative	1		
Aspiration of the tooth into the bronchus of the lung	1	A mild cough	Maxilla: 0 Mandible: 1
Postoperative	37		
Pneumomediastinum, pneumorrhachis, pneumothorax, and pneumopericardium	21	Chest pain and tightness, dyspnea, dysphagia, and swelling and crepitus in the chest region	Maxilla: 2 Mandible: 18 Unknown: 1
Mediastinitis	6	Cough, fever, trismus, pain on inspiration, dysphagia, and dyspnea with compressive pain in the midline of the upper thorax	Maxilla: 1 Mandible: 4 Unknown: 1
Lemierre syndrome	3	Pain and swelling in submandibular and cervical region, fever, nausea, vomiting, headache, severe acute hypoxic respiratory failure, and septic shock with multiorgan failure	Maxilla: 0 Mandible: 3
Asphyxia death related to post-extraction hematoma	2	Orofacial pain, difficulty in eating, dyspnea, dysphagia, and unconsciousness	Maxilla: 0 Mandible: 2
Pneumonia	1	Not reported	Maxilla: 0 Mandible: 1
Fatal disseminated intravascular coagulation	1	A grand mal seizure progressing to status epilepticus, hyperpyrexia, sinus tachycardia, acute and profound hypotension, septicemic shock, intraoral bleeding, severe gastrointestinal bleeding, severe epistaxis, and acute tubular and renal cortical necrosis	Maxilla: 0 Mandible: 1
Guillain-Barré syndrome	1	Vomiting, diarrhea, increasing muscle weakness, rapid fatigue in arms and legs, and inability to walk and stand on toes	Unknown: 1
Chest wall abscess	1	Pyrexia, tachycardia, restriction of neck movements with mild obliteration of supraclavicular space, and a swelling in the chest wall	Maxilla: 0 Mandible: 1
Pubic osteomyelitis	1	Pain in the groin and buttocks, fever, inability to stand on toes, and pain and restriction of hip flexion and extension	Unknown: 1

Naichuan Su et al: What do we know about uncommon complications associated with third molar extractions? A scoping review of case reports and case series. *J Korean Assoc Oral Maxillofac Surg* 2023

patient's neurological status and eventually death.

#### 4. Complications with long-term or irreversible impact on patients

Of the 248 included patients, 20 patients were reported to have complications with long-term or irreversible impact after third molar extractions. Of those 20 patients, 6 patients were males and 14 patients were females (Supplementary Table 3). The mean age $\pm$ SD of the patients was 35 $\pm$ 16 years. The summary of the characteristics of the 20 patients are presented in Table 1. The most commonly reported complication with long-term or irreversible impact on patients was the injury of the lingual nerve or the inferior alveolar nerve during the extractions (n=6). This was mainly because the nerve injury could cause long-term persistent pain in the orofacial region, which could significantly affect patient quality of life.

## IV. Discussion

In the present study, we identified a total of 51 types of uncommon complications associated with third molar extractions in 248 patients. Most uncommon complications were identified in the craniofacial and cervical regions after the extraction procedures. Iatrogenic displacement of the molars or root fragments into the craniofacial area, late mandibular fracture, and subcutaneous emphysema in the orofacial and cervical regions were the most frequently identified uncommon complications. Among all the identified complications, most of them were transient and non-life-threatening, which indicated that most of the complications only had a short-term and mild impact on the patients. However, a small number of patients suffered persistent and life-threatening complications, including death. In total, 37 patients were identified to have life-threatening complications and 20 patients had long-term or irreversible complications associated with third molar extraction.



The present study summarizes uncommon complications, and their primary symptoms, associated with third molar extractions. For clinicians, the findings of the present study help increase the awareness of possible uncommon complications that they may encounter when they perform a third molar extraction. This awareness can also help clinicians balance the benefits and harm of a third molar extraction more comprehensively and make optimal decisions on treatment strategies for their patients. Furthermore, considering that many uncommon complications seem to be iatrogenic, including displacement of the tooth or root fragments into the craniofacial area, subcutaneous emphysema, mandibular nerve injury, breakage and/or migration of a dental tool in the craniofacial area, and mandibular fracture, the results indicate that clinicians should take more efforts to avoid such complications. For example, clinicians should improve their surgical expertise and take adequate preoperative clinical and radiographic examination of the patients. Regarding the patients, the findings of the study can help them understand the potential risks of third molar extractions and help them make decisions more cautiously together with their clinicians so that legal disputes caused by potential complications can be avoided. The findings of the present study also provide useful information to policymakers when they make clinical policies on management strategies for third molars and indications of third molar extractions. Eventually, the findings of the present study can improve patient health outcomes.

However, it should be noted that the mechanisms that link some identified uncommon complications with third molar extractions are still unknown. Whether some uncommon complications, such as Guillain-Barré syndrome<sup>24</sup> and sensorineural hearing loss<sup>25</sup>, are caused directly by the extraction procedures or the uncommon complications occur due to some other reason is not clear. Additionally, the risk of uncommon complications may not be the same for all patients. A patient's health may be an important factor of serious uncommon complications. Among the patients included in the study, patients with a history of disease or who were pregnant were 8.7 and 4.2 times more likely to have life-threatening complications and long-term/irreversible complications, respectively, than patients with no history of disease or who were not pregnant. Patients with mandibular third molar extractions had 2.5 times higher odds to have a life-threatening complication than those with maxillary third molar extractions. Therefore, in terms of complications that are serious but extremely rare, it may not be necessary to impact the regular treatment plans, clinical guidelines, and policies for

normal patients. However, the clinicians need to be more cautious about the treatment of high-risk patients.

In interpreting the findings of the present study, some limitations should be taken into consideration. First, we could not use uniform criteria for the judgment of uncommon complications in the present review, because a standardized classification of uncommon complications does not exist, and various definitions may have been used in the included reports. Furthermore, to the best of our knowledge, no previous report provided the exact prevalence of the reported complications in third molar extractions. Hence, all the complications that were reported in the form of case reports or case series were assumed to be uncommon<sup>26</sup> and were included in the present review. Also, no authors in the included case reports reported any standardized definitions they used to judge if the reported complications were uncommon. Whether a complication was worth reporting in a case report due to its rarity was completely determined by the authors based on their own subjective judgment. Additionally, whether the uncommon complications were life-threatening or long-term/irreversible was determined based on our own subjective judgment, rather than standardized criteria because no commonly used standardized classification systems are currently available for the fatality and permanence of the complications. This, however, could bias the results of the review.

Second, only case reports and case series were included in the study. There were several methodological limitations in these types of studies. One of the important limitations was the publication bias<sup>27</sup>. For example, the identified uncommon complications in the present study may be only the tip of the iceberg, and there could be more uncommon complications that were not reported in publications because the public reporting of such negative events may not be encouraged in some national cultures<sup>28</sup> and some researchers or clinicians may not be enthusiastic to publish the case reports or case series<sup>27</sup>. Therefore, the included case reports and case series may not be representative of the entire spectrum of uncommon complications associated with third molar extractions. Another methodological limitation is that the case reports or case series were always retrospective. Therefore, the medical records may not contain all relevant important data and documentation of the clinical data was not performed according to a standardized protocol in many of the included case reports and case series<sup>27</sup>. Thus, many included patients had missing values in some important variables, such as the impaction status and symptoms of the molars in the study. However, case reports and case series are often the major or even the only

source for detecting uncommon adverse events<sup>26</sup>. For uncommon complications associated with third molar extractions, other types of studies designed with a higher ranking on the evidence hierarchy, such as randomized controlled trials or cohort studies, are impossible to run due to a lack of patients to be enrolled.

## V. Conclusion

Many uncommon complications associated with third molar extractions were identified in the present scoping review. Most complications associated with the extraction of mandibular third molars were postoperative in the craniofacial and cervical regions. Most complications were mild and transient, while a small number of complications were potentially life-threatening and long-term or irreversible.

## ORCID

Naichuan Su, <https://orcid.org/0000-0001-8034-9410>

Sana Harroui, <https://orcid.org/0000-0002-5101-6083>

Fred Rozema, <https://orcid.org/0000-0001-8196-8811>

Stefan Listl, <https://orcid.org/0000-0002-8176-3397>

Jan de Lange, <https://orcid.org/0000-0003-0096-8217>

Geert J.M.G. van der Heijden, <https://orcid.org/0000-0003-4979-2099>

## Authors' Contributions

N.S. participated in the study design, study searching, screening of eligible studies, data collection, data interpretation, statistical analysis, and manuscript writing. S.H. participated in the study design, study searching, screening of eligible studies, and data collection. F.R. participated in the study design. S.L. participated in the study design. J.L. participated in the study design. G.J.M.G.H. participated in the study design and data interpretation. All authors read, commented on, and approved the final manuscript.

## Funding

No funding to declare.

## Supplementary Materials

Supplementary data is available at <https://www.jkaoms.org/>

## Conflict of Interest

No potential conflict of interest relevant to this article was reported.

## References

- McArdle LW, Renton T. The effects of NICE guidelines on the management of third molar teeth. *Br Dent J* 2012;213:E8. <https://doi.org/10.1038/sj.bdj.2012.780>
- Friedman JW. The prophylactic extraction of third molars: a public health hazard. *Am J Public Health* 2007;97:1554-9. <https://doi.org/10.2105/ajph.2006.100271>
- Alfadil L, Almajed E. Prevalence of impacted third molars and the reason for extraction in Saudi Arabia. *Saudi Dent J* 2020;32:262-8. <https://doi.org/10.1016/j.sdentj.2020.01.002>
- Mettes TG, Nienhuijs ME, van der Sanden WJ, Verdonschot EH, Plasschaert AJ. Interventions for treating asymptomatic impacted wisdom teeth in adolescents and adults. *Cochrane Database Syst Rev* 2005;2:CD003879. <https://doi.org/10.1002/14651858.cd003879.pub2>
- Anjrini AA, Kruger E, Tennant M. Cost effectiveness modelling of a 'watchful monitoring strategy' for impacted third molars vs prophylactic removal under GA: an Australian perspective. *Br Dent J* 2015;219:19-23. <https://doi.org/10.1038/sj.bdj.2015.529>
- Santosh P. Impacted mandibular third molars: review of literature and a proposal of a combined clinical and radiological classification. *Ann Med Health Sci Res* 2015;5:229-34. <https://doi.org/10.4103/2141-9248.160177>
- Tüfekçi E, Svensk D, Kallunki J, Huggare J, Lindauer SJ, Laskin DM. Opinions of American and Swedish orthodontists about the role of erupting third molars as a cause of dental crowding. *Angle Orthod* 2009;79:1139-42. <https://doi.org/10.2319/091708-481r.1>
- Hounsoume J, Pilkington G, Mahon J, Boland A, Beale S, Kotas E, et al. Prophylactic removal of impacted mandibular third molars: a systematic review and economic evaluation. *Health Technol Assess* 2020;24:1-116. <https://doi.org/10.3310/hta24300>
- Kennisinstituut Mondzorg. *Klinische praktijkrichtlijn: derde molaar*. Utrecht: Kennisinstituut Mondzorg; 2020.
- Peñarocha-Diogo M, Camps-Font O, Sánchez-Torres A, Figueiredo R, Sánchez-Garcés MA, Gay-Escoda C. Indications of the extraction of symptomatic impacted third molars. A systematic review. *J Clin Exp Dent* 2021;13:e278-86. <https://doi.org/10.4317/jced.56887>
- Chen YW, Chi LY, Lee OK. Revisit incidence of complications after impacted mandibular third molar extraction: a nationwide population-based cohort study. *PLoS One* 2021;16:e0246625. <https://doi.org/10.1371/journal.pone.0246625>
- Sigron GR, Pourmand PP, Mache B, Stadlinger B, Locher MC. The most common complications after wisdom-tooth removal: part 1: a retrospective study of 1,199 cases in the mandible. *Swiss Dent J* 2014;124:1042-6, 1052-6.
- Lee CT, Zhang S, Leung YY, Li SK, Tsang CC, Chu CH. Patients' satisfaction and prevalence of complications on surgical extraction of third molar. *Patient Prefer Adherence* 2015;9:257-63. <https://doi.org/10.2147/ppa.s76236>
- Sayed N, Bakathir A, Pasha M, Al-Sudairy S. Complications of third molar extraction: a retrospective study from a tertiary health-care centre in Oman. *Sultan Qaboos Univ Med J* 2019;19:e230-5. <https://doi.org/10.18295/squmj.2019.19.03.009>
- Osunde O, Saheeb B, Basse G. Indications and risk factors for complications of lower third molar surgery in a Nigerian teaching hospital. *Ann Med Health Sci Res* 2014;4:938-42. <https://doi.org/10.1007/s12245-014-0098-4>

- org/10.4103/2141-9248.144919
16. Brauer HU. Unusual complications associated with third molar surgery: a systematic review. *Quintessence Int* 2009;40:565-72.
  17. González-Navarro B, Arranz-Obispo C, Albuquerque R, Jané-Salas E, López-López J. Osteomyelitis of the jaw (with pathological fracture) following extraction of an impacted wisdom tooth. A case report. *J Stomatol Oral Maxillofac Surg* 2017;118:306-9. <https://doi.org/10.1016/j.jormas.2017.05.003>
  18. Gupta N. 585: Disseminated pneumococcal infection resulting in cerebral vasculopathy. *Crit Care Med* 2019;47:273. <https://doi.org/10.1097/01.ccm.0000551337.15698.dc>
  19. Karaali S, Emekli U. Myositis ossificans traumatica of the medial pterygoid muscle after third molar tooth extraction: a case report and review of literature. *J Oral Maxillofac Surg* 2018;76:2284.e1-5. <https://doi.org/10.1016/j.joms.2018.06.174>
  20. Tricco AC, Lillie E, Zarin W, O'Brien KK, Colquhoun H, Levac D, et al. PRISMA extension for scoping reviews (PRISMA-ScR): checklist and explanation. *Ann Intern Med* 2018;169:467-73. <https://doi.org/10.7326/m18-0850>
  21. Briscoe S, Bethel A, Rogers M. Conduct and reporting of citation searching in Cochrane systematic reviews: a cross-sectional study. *Res Synth Methods* 2020;11:169-80. <https://doi.org/10.1002/jrsm.1355>
  22. Nakamura T, Igarashi H, Ito T, Jensen RT. Important of case-reports/series, in rare diseases: using neuroendocrine tumors as an example. *World J Clin Cases* 2014;2:608-13. <https://doi.org/10.12998/wjcc.v2.i11.608>
  23. Mathes T, Pieper D. Clarifying the distinction between case series and cohort studies in systematic reviews of comparative studies: potential impact on body of evidence and workload. *BMC Med Res Methodol* 2017;17:107. <https://doi.org/10.1186/s12874-017-0391-8>
  24. Dawson K. Guillain-Barré syndrome complicating the surgical removal of third molar teeth. *J Oral Maxillofac Surg* 1994;52:1316-7. [https://doi.org/10.1016/0278-2391\(94\)90055-8](https://doi.org/10.1016/0278-2391(94)90055-8)
  25. Srinivasan B, Ethunandan M, Markus A. Sensorineural hearing loss after dental extraction under general anesthesia: report of a case. *J Oral Maxillofac Surg* 2008;66:1939-41. <https://doi.org/10.1016/j.joms.2007.08.052>
  26. Rao A, Ramam M. The case for case reports. *Indian Dermatol Online J* 2014;5:413-5. <https://doi.org/10.4103/2229-5178.142480>
  27. Nissen T, Wynn R. The clinical case report: a review of its merits and limitations. *BMC Res Notes* 2014;7:264. <https://doi.org/10.1186/1756-0500-7-264>
  28. Raimo N, Zito M, Caragnano A. Does national culture affect integrated reporting quality? A focus on GLOBE dimensions. In: Mihajlović D, Đorđević B, eds. *The 9th International Symposium on Natural Resources Management book of proceedings*. Zaječar: Leibniz Information Center for Economics; 2019:383-392.

**How to cite this article:** Su N, Harroui S, Rozema F, Listl S, de Lange J, van der Heijden GJMG. What do we know about uncommon complications associated with third molar extractions? A scoping review of case reports and case series. *J Korean Assoc Oral Maxillofac Surg* 2023;49:2-12. <https://doi.org/10.5125/jkaoms.2023.49.1.2>