

# 전두부피판과 이개복합조직이식술을 이용한 외비의 재건 치험례

박봉욱 · 변준호

경상대학교 의과대학 치과학교실 구강악안면외과

**Abstract** (J. Kor. Oral Maxillofac. Surg. 2005;31:350-355)

## A CASE REPORT OF THE EXTERNAL NOSE RECONSTRUCTION USING FOREHEAD FLAP AND AURICULAR COMPOSITE GRAFTS

Bong-Wook Park, June-Ho Byun

*Department of Dentistry, College of Medicine, Gyeongsang National University*

There are various surgical methods for reconstruction of the nasal defect. Among them, there is some difference in the choosing the proper reconstruction method according to defect size and position. When the defect involved the tip, the columella, and the alar, the local flaps may be preferred, because they can provide sufficient amount of tissue. However, the composite grafts from the ear have been effectively used in reconstructions of smaller sized defects of the columella and ala. We excised total external nose because of squamous cell carcinoma on the nasal tip, columella, and nasal septum. We reconstructed the nasal tip, both alae, and columella with forehead flap. After division of the regional flap, we found partial necrosis of the columella and narrowness of the nostril. So, we used chondrocutaneous auricular composite grafts for reconstruction of the columella and both nostrils. We used the file-folder designed auricular composite graft for reconstruction of columella and the wedge shaped ear helical composite grafts for widening of nostrils. 6 months later, there were no significant problems, except some mismatched dark color in the grafted alar tissues. Here, we report a successful reconstruction of large nasal defect using combined two different reconstructive methods.

**Key words:** Large nasal defect, Forehead flap, Auricular composite graft

### I. 서 론

### 가

(auricular composite graft)

<sup>6)</sup>

(external nose)

<sup>1), 2), 3)</sup>

(free flap)

<sup>4)</sup>

(air way)

<sup>1)</sup>

가

(nasal tip),

(columella),

(nasal septum)

(flap division)

(nostril)

가

(nasal alae)

가

(local

flap)

<sup>3)</sup>,

(fore-

head flap),

(nasolabial flap)

(dorsal

### II. 증례보고

nasal flap) <sup>5)</sup>,

61

(Fig. 1).

### 박 봉 욱

660-702 경남 진주시 칠암동

경상대학교 의과대학 치과학교실 구강악안면외과

**Bong-Wook Park**

Department of OMFS, Gyeongsang National University Hospital,

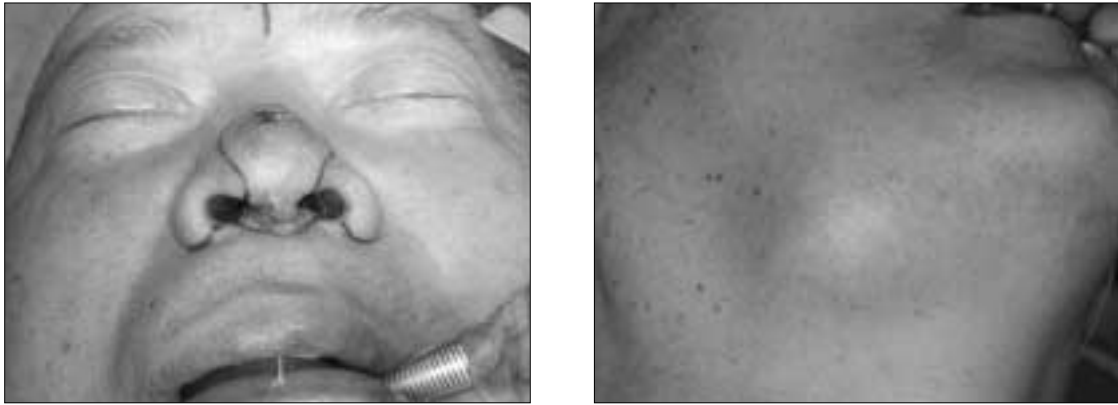
Chilam-Dong, Jinju City, Gyeongnam, 660-702, Korea

Tel: +82-55-750-8264 Fax: +82-55-761-7024

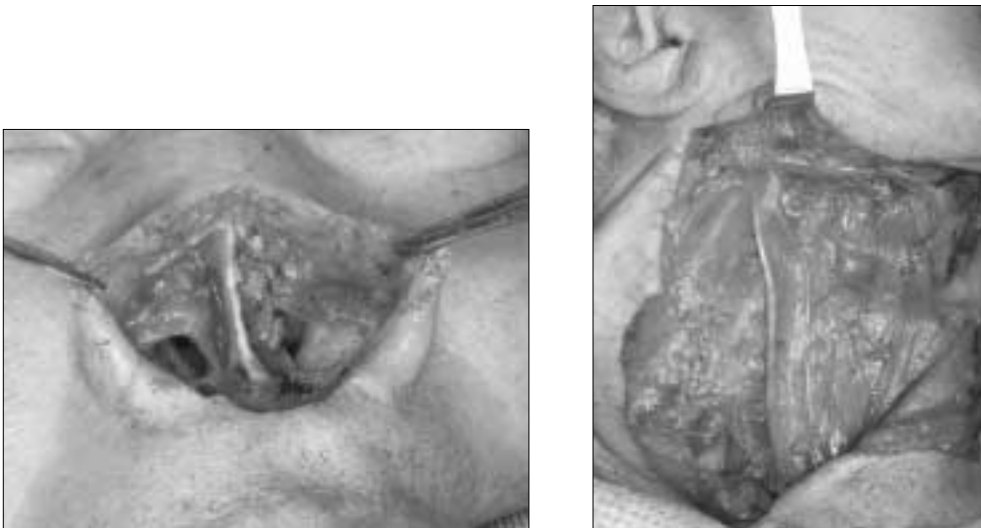
E-mail: parkbw@nongae.gsnu.ac.kr

, CT

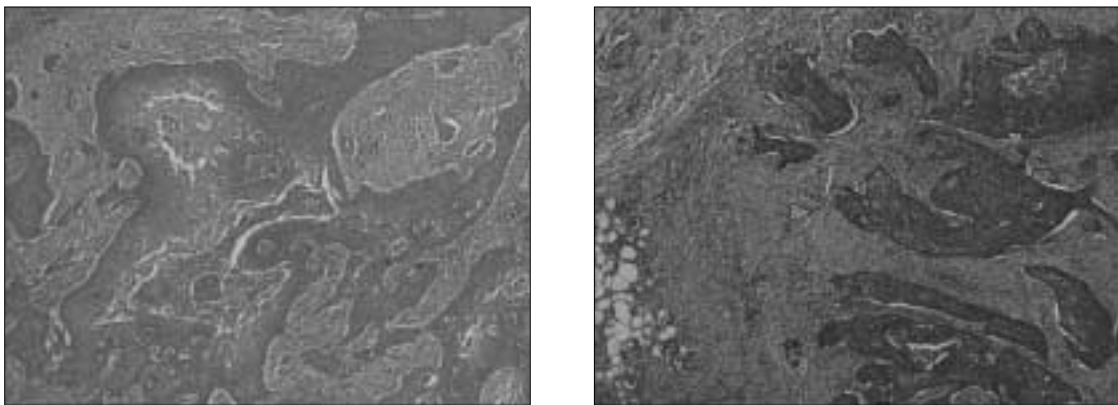
가



**Fig. 1.** Preoperative views. Note the cancer lesions on external nose (Lt.) and large mass on Rt. submandibular region (Rt.).

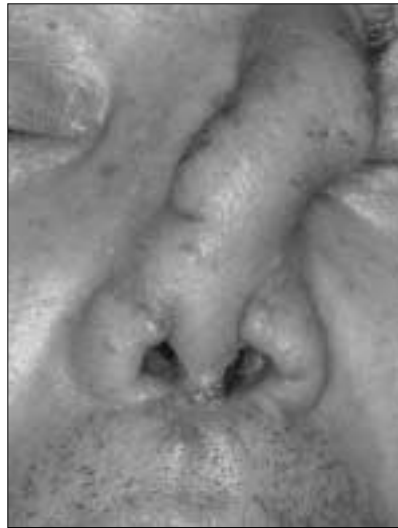
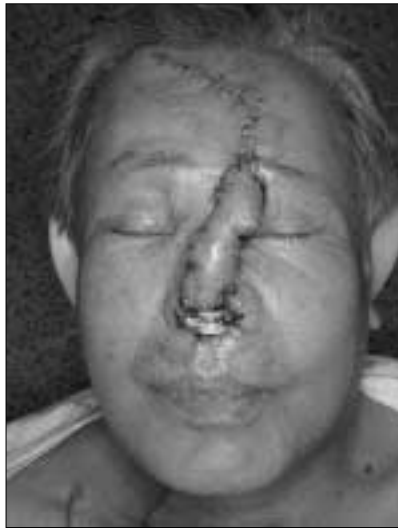
**Fig. 2.** After excision of the nasal tumors (Lt.) and unilateral radical neck dissection (Rt.).

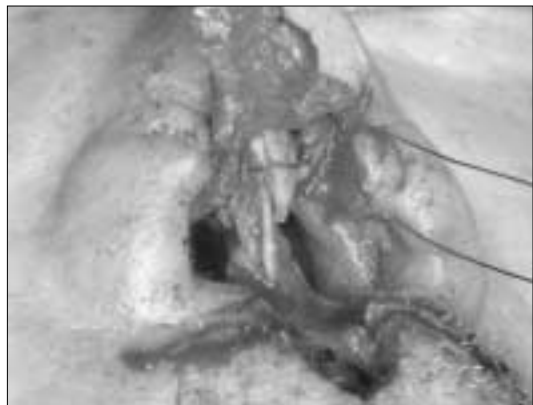
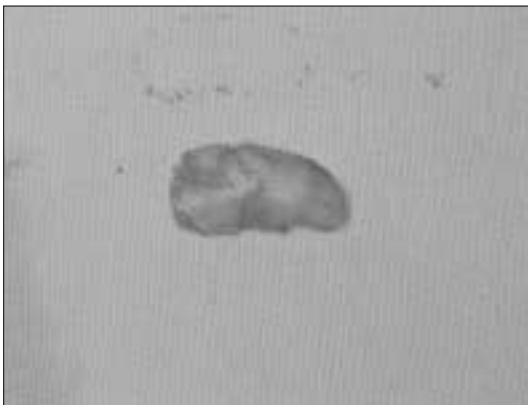


**Fig. 3.** The histologic features of nasal (Lt.) and submandibular (Rt.) tumors. We could see the well differentiated squamous cell carcinomas on the both specimens.

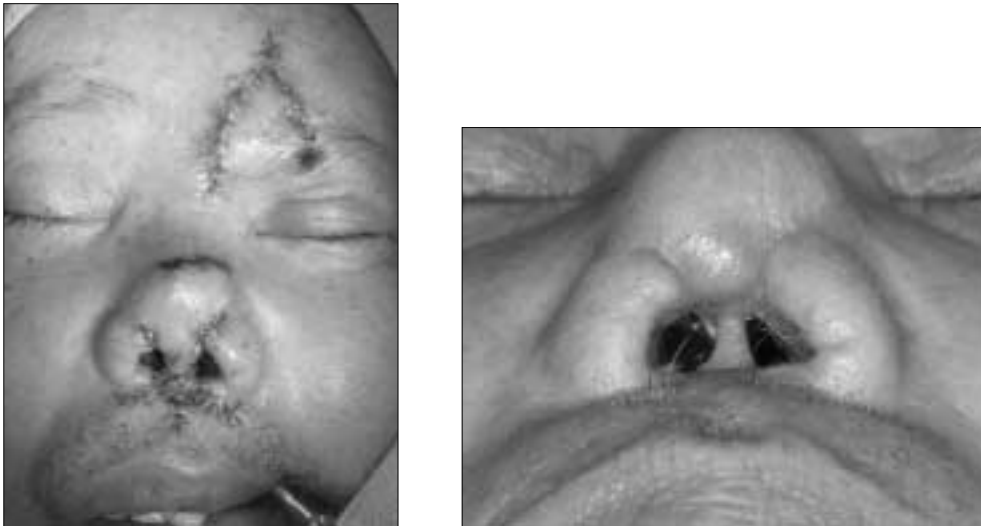
(Fig. 2). (margin negative) (supratrochlear artery) (flap pedicle) (superior orbital rim) (nasal mucosal flap) (intranasal lining) (Fig. 4). 3 (flap division) (auricular concha) (auricular cartilage) (Fig. 5). 가 가 (nostril) (Fig. 6). (chondrocutaneous auricular composite grafts) 12×10 mm (Fig. 7) (file-folder) (nasal septal cartilage) (nasal (ear helix) 12 mm (full thickness) 3




**Fig. 4.** Immediately after (Lt.) and 3 weeks later (Rt.) of the forehead flap on the nasal defects.



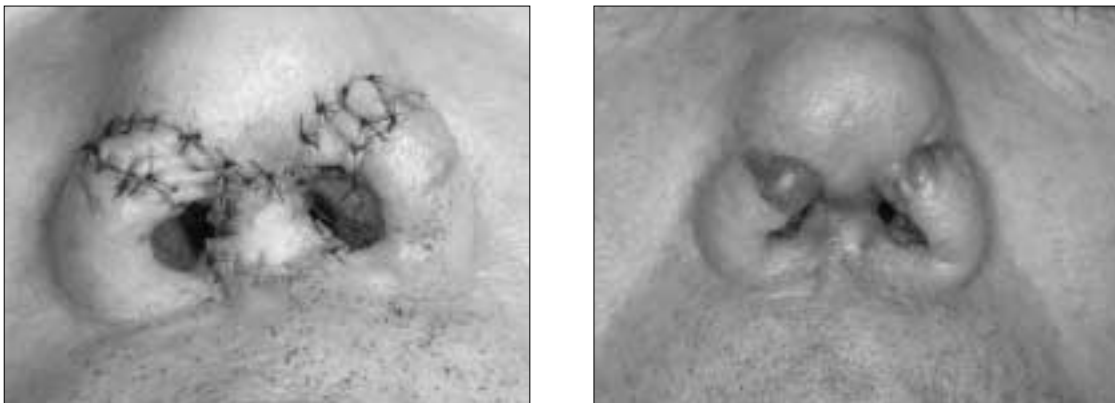
**Fig. 5.** Auricular cartilage from the ear concha (Lt). It was grafted on the nasal tip for it's augmentation at the same time as flap division (Rt.).



**Fig. 6.** Immediately after the forehead flap division and the nasal tip augmentation (Lt.). Note the partial loss of columella and the narrowness of nostrils during healing period (Rt.).



**Fig. 7.** Chondrocutaneous auricular composite tissues from the ear concha (Lt.) and helix (Rt.). The former was folded like as file-folder for reconstruction of the columella and the latter was inserted in the ala for widening of the nostril.



**Fig. 8.** Immediately after (Lt.) and 6 months later (Rt.) of the auricular composite grafts on the columella and the both alae. Note the satisfied reconstruction of the external nose, but some mismatched dark color was remaining until this time.

(Fig. 7) (wedge) (mastoid process) 6 7

Millard<sup>8)</sup>가 (seagull flap) 가

(Fig. 8).

III. 총괄 및 고찰

2000

(midforehead flap) Kazanjian<sup>7)</sup> Millard<sup>8)</sup> (nasal ala) (seagull flap) Burget Menick<sup>9)</sup> (hairline)

Mangold<sup>10)</sup> (dorsal nasal artery), (supratrochlear artery), (supraorbital artery) (superficial temporal artery) (median and paramedian)

(composite tissue graft) Koenig<sup>13)</sup>

Dupertuis<sup>14)</sup> (ear lobe), Brown<sup>15)</sup> Meade<sup>16)</sup> (ear helix), Cho<sup>4)</sup> Pegram<sup>17)</sup> (alar base)

2 cm

(auricular concha) 3 (full thickness)

(intranasal lining) (nasal septal mucosal flaps)

12) 10-20%

(ear cartilage graft) 가

4) , Brown<sup>15)</sup>

3

1 cm

1 cm

가

, Park<sup>18)</sup> 가

(flap pedicle)

가 5-15 mm

2

, 17 mm

가 가

10 mm

, Ahn<sup>19)</sup>

(auricular concha)

(file-folder)

Kim <sup>3)</sup>

3

12 × 10 mm

<sup>19)</sup> Kim <sup>3)</sup>

6 mm 가

<sup>15)</sup>

가 1 cm

Ahn

10 mm

, Brown

가

가 12 mm

3

가 10 mm

가

2

가

6

가

IV. 결 론

가

가 가

2

3

6

참고문헌

1. Ozek C, Gundogan H, Bilkay U, Alper M, Cagdas A: Nasal columella reconstruction with a composite free flap from the root of auricular helix. *Microsurgery* 2002;22:53-56.
2. Tang Chen YB, Chen HC, Randall P: Reconstruction of a compound facial deformity involving the columella, nasal base, and upper lip. *Plast Reconstr Surg* 1991;87:950-953.
3. Kim YO, Park BY, Lee WJ: Aesthetic reconstruction of the nasal tip using a folded composite graft from the ear. *Br J Plast Surg* 2004; 57:238-244.
4. Cho BC, Park JW, Baik BS: Correction of severe secondary cleft lip nasal deformity using a composite graft: current approach and review. *Ann Plast Surg* 2002;48:131-137.
5. Alford EL, Baker SR, Shumrick KA: Midforehead flaps In: Baker SR, Swanson NA. *Local flaps in facial reconstruction* 1st ed. St. Louis, Mosby, 1995:197-223.
6. Lehman JA Jr, Garrett WS Jr: Earlobe composite grafts for the correction of nasal defects. *Plast Reconstr Surg* 1971;47:12-16.
7. Kazanjian VH: The repair of nasal defects with the median forehead flap: primary closure of the forehead wound. *Surg Gynecol Obstet* 1946;83:37.
8. Millard DR Jr: Total reconstructive rhinoplasty and a missing link. *Plast Reconstr Surg* 1966;37:167-183.
9. Burget GC, Menick FJ: Nasal reconstruction: seeking a fourth dimension. *Plast Reconstr Surg* 1986;78:145-157.
10. Mangold V, Lierse W, Pfeifer G: The arteries of the forehead as the basis of nasal reconstruction with forehead flaps. *Acta Anat* 1980;107 :18-25.
11. Shumrick KA, Smith TL: The anatomic basis for the design of forehead flaps in nasal reconstruction. *Arch Otolaryngol Head Neck Surg* 1992;118:373-379.
12. Kastenbauer ER: Reconstructive surgery of the external nose In: Tardy ME Jr, Kastenbauer ER. *Head and neck surgery* 2nd ed. New York, Georg Thieme Verlag, 1995:303-359.
13. Koenig F: Zur Deckung von Defekten der Nasenflugel. *Berl Klin Wochenschr* 1902;39:137-138.
14. Dupertuis SM: Free ear lobe grafts of skin and fat. *Plast Reconstr Surg* 1946;1:135-144.
15. Brown JB, Cannon B: Composite free grafts of skin and cartilage from the ear. *Surg Gynecol Obstet* 1946;82:253-255.
16. Meade RJ: Composite ear grafts for construction of columella. *Plast Reconstr Surg* 1959;23:134-147.
17. Pegram M: Repair of congenital short columella. *Plast Reconstr Surg* 1954;14: 305-307.
18. Park JB, Jang HJ, Hong IP, Kim JH, Lee SI: Survival rate of composite to graft according to graft size and microscopic examination: experimental study on ear of rabbit. *J Korean Soc Plast Reconstr Surg* 1996;23:1204-1210.
19. Ahn SJ, Park BJ, Lee YH: Columella lengthening with reinforced composite graft: a file-folder design in the bilateral cleft lip nose deformity. *J Korean Soc Plast Reconstr Surg* 1997;24:949-959.