

Expression of transforming growth factor-1 in bone regeneration after the implantation of particulate dentin and plaster of Paris

Young-Chul Huh¹, Su-Gwan Kim¹, Jeong-Sun Kim¹, Jung-Hoon Yoon², Do-Kyung Kim³

¹Department of Oral & Maxillofacial Surgery, ²Department of Oral Pathology,

³Department of Oral Physiology, College of Dentistry, Chosun University, Gwangju, Korea

Abstract

Purpose: This study was performed to investigate the expression of the transforming growth factor (TGF)-1, in a rat calvarium defect model using particulate dentin and/or plaster of Paris, and correlate the bone regeneration process with the histologic events.

Materials and Methods: Thirty-two Sprague-Dawley rats were divided into 4 groups of 8 animals each. A 1.0 cm-sized calvarial defects were made and the defect was filled with different graft materials as follows : Group A, the defects were filled with a mixture of particulate dentin and plaster of Paris with a 2:1 ratio; Group B, the defects were filled with plaster of Paris only; Group C, defects were filled with particulate dentin only; Group D, untreated control group. The animals were sacrificed by 1, 2, 4, 8 weeks after implantation. Excised wound tissues were processed for histology, immunohistochemistry and RT-PCR for the analysis of TGF-1 expression.

Results: Gene expression of TGF-1 was detected for all experimental groups. The highest gene expression was observed in the specimen taken at the first week after implantation in Group A. According to the histologic and immunohistochemical studies, TGF-1 positive osteoblast-like cells were found in the early stage of healing after the implantation of particulate dentin and plaster of Paris.

Conclusion: These findings suggest that TGF-1 may be related to new bone formation at the early healing process after the implantation of particulate dentin and plaster of Paris.

Key words

Bone regeneration, Transforming growth factor-1, Particulate dentin and plaster of Paris

INTRODUCTION

Bone graft is used to restore defects in the oromaxillary area¹. The bone regeneration process after bone graft can be summed up to the integration process involving inflammation, followed by granulation, vascularization, and extracellular matrix formation². Restoration after bone graft involves the integration process of host tissue to the new bone or graft material and its mechanism differs whether the graft material is autograft, allograft, or

xenograft. There is no doubt that autograft is the most ideal for the restoration of soft tissue defect^{1,2}. Autograft has the osteogenesis, osteoinduction and osteoconductive properties and at the same time shows no immune rejection and heals fast. However, the biggest drawbacks using autograft are a limited harvesting bone volume, bone resorption after graft and secondary defect at the donor site³. Thus, many different graft materials such as allograft, xenograft and heterograft are used clinically, and many attempts have been made to develop ideal bone graft materials⁴⁻⁶.

Among those bone graft materials, the combination of particulate dentin and plaster of Paris is reported as the resorbable material having bioaffinity and showing osteoconductive healing process¹. Easily obtainable particulate dentin is mainly composed of hydroxyapatite. Plaster of Paris is inexpensive, can be purchased and

* Corresponding author

Su-Gwan Kim, DDS, PhD
Department of Oral and Maxillofacial Surgery,
College of Dentistry, Chosun University
421, SeoSeogDong, DongGu, GwangJu City, 501-825, Korea
Tel: 82-62-220-3815 Fax: 82-62-228-7316
E-mail: SGCKIM@chosun.ac.kr

sterilized easily, and completely resorbable^{1-3,5}). Through many experimental studies, researchers showed the potential of the biomaterial formed by combining an appropriate ratio of particulate dentin, which is mainly composed of hydroxyapatite, and plaster of Paris, which increases the stability of graft material and promotes bone healing, to be used in soft tissue restoration, osteoconductive restoration and for membrane function¹⁻⁵).

It is well known that bone graft materials would induce the formation of new bone having high density through osteogenesis and osteoconduction and that growth factors are involved in the wound healing process including new bone formation⁷⁻¹⁰). The important growth factors discussed during the healing process of bone defect are connective tissue growth factor (CTGF)⁷), bone morphogenic protein-4 (BMP-4)⁸), and transforming growth factor- (TGF-⁸⁻¹⁰). However, the molecular biologic mechanism involved during this healing process after the implantation of particulate dentin and plaster of Paris has not been determined. TGF-, an important controlling factor during wound healing, acts as the strongest stimulating factor for the formation of connective tissue during the wound healing process⁸⁻¹⁰). CTGF belonging to the CCN family is the secreting peptide containing abundant cysteine and is secreted from fibroblasts and vascular endothelial cells⁷). Termed by Urist¹¹), BMP having the potential to induce the formation of cartilage and bone from nonskeletal mesodermal cells is the first multifunctional growth factor confirmed in bone matrix, is known as the growth factor belonging in the TGF- family and inducing bone formation, and is divided into several subfamilies based on the traditional protein homology of protein structure¹²). Among several BMP subfamilies, BMP-2 and BMP-4 having closely related base sequences have an excellent new bone formation property so that they are expected to be the important controlling factors during new bone formation after bone graft implantation^{8,10}). By confirming the expression of TGF-1 through protein distribution and mRNA expression after the implantation of plaster of Paris, particulate dentin, and the combination of these two materials into the areas of bone defect, this study was conducted to understand the signal pathway of growth factors involved during the bone healing process of these implant materials and to establish the biochemical mechanism to develop new bone graft materials, which would promote bone formation.

MATERIALS AND METHODS

A. Materials

1. Study animal and materials

a. Study animal

The animal used in this study was 32 male and female Sprague-Dawley rats weighing more than 200g grown under the same conditions without limiting water and feed.

b. Implant materials

(1) Particulate dentin

Particulate dentin was obtained from healthy extracted human teeth, which were washed in physiological saline solution, ashified at 950 °C in a furnace, and made into powder at 100 mesh(0.149 mm).

(2) Plaster of Paris

Plaster of Paris (calcium sulfate hemihydrate) was purchased from Gypsum Co.

(3) Combination of particulate dentin and plaster of Paris

Particulate dentin and plaster of Paris were mixed at a weight ratio of 2:1, wrapped in paper, and sterilized in ethylene-oxide gas.

2. Methods

a. Implantation of implant materials

Ketamine (90 mg/kg) and xylazine (10 mg/kg) were intramuscularly injected into the rat femur for anesthesia and gentamycin(5 mg/kg) was also injected intramuscularly for the prevention of infection. The surgery area was shaved and sterilized. After injecting 2 % lidocaine HCl(1:100,000 epinephrine) to prevent bleeding, the calvarial bone was resected and the periosteum was exposed. On the exposed calvarial bone, a circular full thickness defect having 1cm diameter was formed using a #1/4 round bur. The defect was filled with the graft material prepared by combining particulate dentin and plaster of Paris at a weight ratio of 2:1 (Experimental group A where n=8). It was filled with plaster of Paris in Experimental group B (n=8) and with particulate dentin in Experimental group C (n=8). It was not filled in the control group D (n=8). The wound was washed and sterilized after surgery and sutured thoroughly including the periosteum.

b. Sacrifice of rats

Two rats were sacrificed in each group by 1, 2, 4 and 8 weeks of implantation by administering over-dose ether. A bone sample was taken from the implantation site, in which 1/2 was fixed in 10% formalin and 1/2 was stored in nitrogen to isolate RNA and protein.

B. Study methods

1. Preparation of decalcified tissue samples

The sample taken from the implantation site was fixed in 10% formalin for 3 days and decalcified in 5% formic acid-sodium citrate for 5 days. It was embedded in paraffin according to the conventional method and prepared into 4 m slices, which were stained with Hematoxylin-Eosin (H-E) and histologically observed under optical microscope.

2. Immunohistochemical staining

The expression of TGF-1, which is the growth factor involved in bone formation, was observed using immunohistochemistry. The primary antibody for TGF-1 was monoclonal antibody (OSN4-2, Takara, Japan). Immunohistochemistry was performed according to the conventional peroxidase avidin-biotin complex method as follows. After deparaffining the sample using xylene, acetone, and 100%, 95%, and 75% alcohol, it was washed in running water. It was then treated at room temperature with 0.4 mg/ml Proteinase K (V302B, Promega) for 5 min. TBS (Tris buffered saline, TBS999, ScyTek) was used to wash the sample 3 times for 5 min each to remove any reagents left over. It was treated with 3% H₂O₂ for 5 min at room temperature to remove endogenous peroxidase activity. It was again washed with TBS, reacted with the streptavidin biotin universal detection system for 10 min at room temperature, and reacted with TGF- β 1 primary antibody at 5 g/ml for 90 min at room temperature. It was then washed with TBS, reacted with biotin marker secondary antibody at room temperature for 10 min, washed with TBS, reacted with streptavidin peroxidase (Cat No. 2391, Immunotech) at room temperature for 10 min, washed with TBS, and decolorized with DAB at room temperature for 2 min. The reaction was stopped by placing the sample in distilled water. For counterstaining, Mayer's hematoxylin (HMM500, ScyTek) was used to treat the sample at room temperature for 20 sec. The degree of TGF-1 expression was analyzed at each period by designating a score in which +/-

was given when no or some expression was shown, + when some staining was shown in cells scattered in normal mature bone, ++ when medium grade staining was shown in the cytoplasm, and +++ when strong staining was shown in the cytoplasm.

3. RT-PCR (RT-PCR Analysis)

The expression of TGF-1 mRNA was analyzed using reverse transcriptase-polymerase chain reaction (RT-PCR). The remaining 1/2 tissue sample in the control group and experimental groups not fixed in formalin was frozen quickly in liquid nitrogen and homogenized. Trizol (Invitrogen Co., USA) was added into the homogenized sample, which was treated with 1/10-fold chloroform, and the supernatant was discarded. The pellet was treated with the same amount of isopropanol, washed with DEPC-70% ethanol, dried and dissolved in DEPC-DW. Absorbance was read at 260 nm to quantify the amount of RNA, and reverse transcription reaction was done. To the reactant, 1 RT buffer (Promega, USA), 20 M of dNTP, 0.25 g of oligo(dT)15 primer, 5 units of AMV (Avian Myoblastosis Virus) reverse transcriptase (Promega, USA), 2 g of RNA and DEPC-DW added to bring up the total volume to 10 l, and the reaction was carried out at 42°C for 60 min. After the reaction, 5 l of RT product was mixed with 1 × PCR of buffer (Promega, USA), 10 pmol sense and antisense primer, 1 unit of Taq polymerase, and distilled water to bring up the total volume of 25 l. Then, the mixture was treated at 58°C for 30 min, and 30 cycles at 92°C for 15 sec, at 60°C for 30 sec, and at 72°C for 30 sec, and at 72°C for 10 min. For each factor shown in Table 1, the sense primer and antisense primer were applied for the primer sequence. After mixing 2 l of 6 loading buffer (0.25% bromphenol blue, 0.25% xylene cyanol, 30% glycerol in water) into 5 l of the resultant solution was taken from each sample after PCR, electrophoresis was performed for 30 sec in agarose gel at 100 V. After ethidium bromide staining was performed, the sample was observed with a ultraviolet projector and polaroid pictures were taken.

RESULTS

A. Histopathological findings

Experimental group A (Particulate dentin and plaster of Paris combined implantation)

a. Findings by one week (A-1)

Around the freed graft material an active infiltration of chronic inflammation cells and multinuclear foreign giant cells was shown, whereas the edema of connective tissue, proliferation of radiating immature fibroblasts and vascularization were weak. In the margin of existing bone defect, some proliferation of new bone trabecula separated from the graft material was shown.

b. Finding by 2 weeks (A-2)

Compared with the findings by 1 week, the edema of connective tissue was decreased, but the vascularization and proliferation of fibroblasts were active around the freed graft material. The infiltration of chronic inflammation cells and multinuclear foreign giant cells was similar to that of week 1. The proliferation of new bone trabecula shown in bone defect was active. In the margin, the proliferation of osteoblasts was active. Some osteoid tissue was fused with the graft material, covering a part of graft material.

c. Finding by 4 weeks (A-4)

The inflammation of connective tissue around the freed graft material was decreased, whereas the vascularization and fibroblast proliferation were active, with its density increased. In the area of bone defect, new bone trabecula was covering around the graft material with no connective tissue involvement, fusing with the existing bone. The reversal line was distinct in the interior of new bone, and the proliferation of osteoblasts was active around the margin.

d. Finding by 8 weeks (A-8)

Compared with the findings by 4 weeks, the inflammation of connective tissue was decreased around the freed graft material and the fibroblast proliferation was active, with its density increased. New bone trabecula was completely covering around the graft material in the area of bone defect so that new bone and existing bone could not be distinguished, with the distinction possible only with the reversal line and the graft material in the new bone. Furthermore, new bone trabecula proliferated into the freed graft material.

Experimental group B (Plaster of Paris implantation)

a. Findings by 1 week (B-1)

Around freed plaster of Paris, the infiltration of acute

and chronic inflammation cells and multinuclear foreign giant cells, the edema of connective tissue, the proliferation of immature radiating fibroblasts, and the granulation with active vascularization were observed. Some new bone trabecula separated from plaster of Paris was proliferated in the area of bone defect.

b. Findings by 2 weeks (B-2)

Freed plaster of Paris was divided into small granules and surrounded by dense connective tissue and multinuclear foreign giant cells. Compared with the findings by 1 week, the infiltration of inflammation cells was decreased in the adjacent connective tissue, whereas vascularization and immature fibroblast proliferation were active. In the area of bone defect the proliferation of new bone trabecula separated from plaster of Paris granules was decreased compared with the findings by 1 week.

c. Findings by 4 weeks (B-4)

The vascularization and the infiltration of inflammation cells were decreased in the connective tissue around plaster of Paris whereas the proliferation of fibroblast was active, showing dense connective tissue. The proliferation of new bone trabecula not fused with plaster of Paris granules was increased in the margin of the existing area of bone defect.

d. Findings by 8 weeks (B-8)

The connective tissue around plaster of Paris was dense as in the findings by 4 weeks. In the area of existing bone defect the proliferation of new bone trabecula not fused with plaster of Paris was also increased compared with the findings by 4 weeks.

Experimental group C (Particulate dentin implantation)

a. Findings by 1 week (C-1)

Around the freed graft material the infiltration of chronic inflammation cells and multinuclear foreign giant cells was active, whereas the vascularization and the proliferation of immature radiating fibroblasts were weak in the connective tissue. In the margin of existing bone defect, some new bone trabecula was proliferated, trabecula, and osteoblasts was actively proliferating around the trabecula with some of these cells fused with the graft material.

b. Findings by 2 weeks (C-2)

Around the freed graft material, the finding of inflammation was decreased, whereas the proliferation of new bone trabecula seen in the area of bone defect and osteoblasts around this area was active. Some osteoid tissue was fused with the graft material, covering a part of graft material. The proliferation of new bone trabecula, distant from the margin of bone defect, was seen, fusing with the graft material.

c. Findings by 4 weeks (C-4)

Around the freed graft material, the inflammation of connective tissue was decreased, whereas fibroblast proliferation and collagen deposit were increased, increasing connective tissue density. The area of bone defect around the graft material was completely covered by new bone trabecula without any involvement of connective tissue, fusing completely with the existing bone. The reversal line was distinct in the newly formed bone, and the proliferation of osteoblasts was active in its margin.

d. Findings by 8 weeks (C-8)

Around the freed graft material the density of connective tissue was increased further compared with the findings by 4 weeks. New bone trabecula was completely covering the area of bone defect around the graft material so that the distinction from the existing bone was difficult, with the distinction possible only with the reversal line or the existence of graft material in the new bone. New bone trabecula was formed around the freed graft material, connected with new bone.

Control group (Bone defect group, Group D)

a. Findings by 1 week (D-1)

The findings included acute and chronic inflammation of connective tissue, immature fibroblasts, and the granularization characterized by vascularization and edema. In the area near the bone defect, osteoblast activity and new bone formation were weak.

b. Findings by 2 weeks (D-2)

Connective tissue inflammation and edema were decreased, whereas fibroblast activity was increased and its density was increased. In the area near the bone defect, the formation of new bone trabecula was active and osteoblast activity was increased.

c. Findings by 4 weeks (D-4)

Compared with the findings by 2 weeks, connective tissue inflammation and edema were significantly decreased, but fibroblast proliferation and collagen deposit were increased. In the area near the bone defect, the formation of new bone trabecula was active, the amount of new bone was increased, and the reversal line was seen.

d. Findings by 8 weeks (D-8)

The area of bone defect was filled with dense fibrotic connective tissue with fibroblast and collagen deposit. In the area near the bone defect, the amount of new bone was increased significantly compared with that by 4 weeks, and the reversal line was distinctive.

B. RT-PCR (RT-PCR Analysis)

RT-PCR was used to analyze the expression of TGF-1 mRNA, and the results are shown in Fig. 1. The results obtained by adjusting the pattern of TGF-1 mRNA expression on agarose gel to that of GAPDH mRNA expression are shown as a graph. We found that the expression of TGF-1 mRNA was weak in all groups. However, compared with Group A (particulate dentin and plaster of Paris combined implantation) or Group B (plaster of Paris implantation), the expression of TGF-1 mRNA was high in Group C (particulate dentin implantation) by 1 week of implantation. This expression was decreased with time so that it was similar to that in other groups by 2 weeks of implantation.

C. Findings with immunohistochemistry

1. Experimental group A (Particulate dentin and plaster of Paris combined implantation)

The expression was strong in the early stage (by 1 and 2 weeks of implantation) around osteoid tissue, osteoblasts and osteocytes. However, it decreased with time (by 4 and 8 weeks of implantation) (Fig. 2A, B). The expression of TGF-1 protein was maintained at constant levels in extracellular matrix or endothelial cells.

2. Experimental group B (Plaster of Paris implantation)

The expression was strong around osteoid tissue including extracellular matrix and endothelial cells, and osteoblasts and osteocytes inside the defect at the early stage, but decreased with time (Fig. 2C, D). However, it

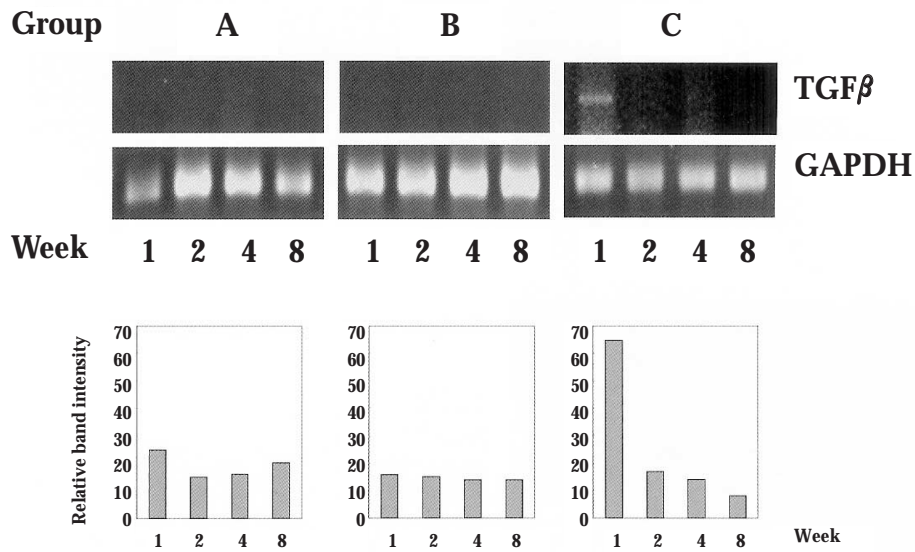


Fig. 1. TGF-1 mRNA expression after the implantation of particulate dentin and plaster of Paris (RT-PCR).

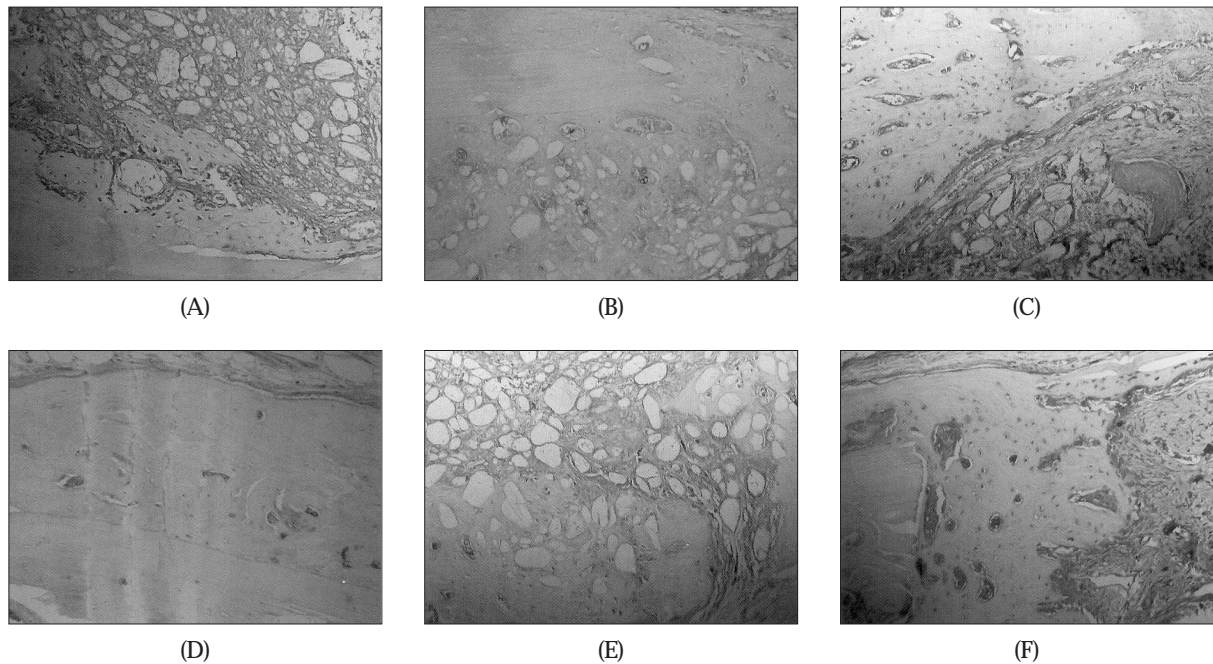


Fig. 2. TGF-1 protein expression after the implantation of particulate dentin and plaster of Paris (Immunohistochemistry).

- A. Photomicrograph of the group A-2; TGF-1 was expressed in the osteoblasts and osteocytes, and together with proliferating mesenchymal cells ($\times 200$).
- B. Photomicrograph of the group A-4; There were decreased TGF-1 expression compared to the A-2 group ($\times 200$).
- C. Photomicrograph of the group B-4; TGF-1 was expressed in the osteoblasts and osteocytes, but the osteoid formation was decreased than the A-4 group ($\times 200$).
- D. Photomicrograph of the group B-8; Active new bone formation was observed, but TGF-1 expression was highly decreased ($\times 200$).
- E. Photomicrograph of the group C-4; Active new bone formation around graft materials was observed, and the TGF-1 was moderately expressed in the osteoid and surrounding mesenchymal cells ($\times 200$).
- F. Photomicrograph of the group D-4; TGF-1 was highly expressed in the osteoblasts and surrounding mesenchymal cells, but the bony defects was still present ($\times 200$).

did not change significantly in interstitial cells around the graft material.

3. Experimental group C (Particulate dentin implantation)

The expression was strong around osteoid tissue including extracellular matrix and endothelial cells, and osteoblasts and osteocytes inside the defect at the early stage, but decreased with time. Especially, the expression of TGF-1 protein was maintained at constant levels in interstitial cells around the graft material (Fig. 2E).

4. Control group D (Bone defect group, Group D)

The expression was strong around osteoid tissue including extracellular matrix and endothelial cells, and osteoblasts and osteocytes inside the defect at the early stage, but decreased with time (Fig. 2F). Especially, the expression of TGF-1 protein was weak by 8 weeks. The results of immunohistochemistry are summarized in Table 2.

DISCUSSION

The biological response mechanism involved in bone tissue after applying an external mechanical stimulus or graft implantation is not understood completely. It is believed that local growth factors would play an important role in inducing the proliferation, differentiation and activation of osteoblasts during the bone healing process⁸. This belief is based on the finding that TGF- and BMP-4 promote bone formation *in vivo*^{8,10,13,14}. In the present study, we observed the mRNA and protein expressions of TGF-1, which is a well-known growth factor, after implanting particulate dentin and plaster of Paris into an area of bone defect. We found that the expression of TGF-1 mRNA was very weak in most groups. It was only strong by 1 week after implanting particulate dentin. However, the expression of TGF-1 protein was observed in all experimental groups including the control group. Especially, it was increased uniformly in the cells participating in new bone formation, suggesting that different graft materials would induce TGF-1 protein to promote new bone formation.

In the early stage, the expression of TGF-1 protein was strong in mesenchymal cells, which is similar to osteoblasts and fibroblast, but gradually decreased in various cells. According to the overall histologic and immunohistochemistry findings, we think that TGF- β 1

would stimulate bone formation after graft implantation. Thus, particulate dentin and plaster of Paris used in this study were not probably the materials promoting bone formation. Similar to the result of previous studies^{1,3}, they are characterized by the healing process involving osteoconduction. Nonetheless, we could not tell whether other growth factors are involved in bone formation because we only examined only TGF-1 among those growth factors participating in bone formation. Especially, the finding, that the expression of TGF-1 was strongest by 1 and 2 weeks of implantation in all experimental groups but weak by 4 and 8 weeks of implantation, suggests that other growth factors would participate in the later stage of healing.

During the extraction and healing process, Kanyama et al⁷ observed the expression of CTGF-positive osteoblasts in the later stage of wound healing, suggesting that new bone formation is deeply involved during the healing process of extract wound. As the down stream mediator for TGF- action, CTGF acts on connective cells to stimulate cellular proliferation and extracellular matrix synthesis¹⁵⁻¹⁸. In other words, the expression of CTGF gene is selectively controlled by TGF-, inducing the expression of CTGF mRNA in cultured fibroblasts¹⁸. Thus, further studies are needed on whether other growth factors such as BMP and CTGF would participate after the implantation of various graft materials and comparative studies are needed with different graft materials such as Bio-oss used extensively in clinical settings.

TGF- β is the polypeptide growth factor having various functions and exists in two homology forms, ie, TGF-1 and 2 having similar amino acid sequences. Initially found in tumor cells, researchers found that TGF- β and its receptor exist in almost all types of cells. This growth factor has high homology so that it plays an important role during wound healing¹⁰⁻¹⁹. TGF- β has been examined extensively and is considered important for vascularization and as well as collagen synthesis. TGF-1 also up-regulate the expression of vascular endothelial growth factor(VEGF). VEGF is essential for vascularization and thus, for bone formation. The results from studies on the extraction and healing processes showed that the expressions of TGF-1 and VEGF were increased at the same time with increasing bone formation by 2 and 12 weeks after extraction, showing the biological characteristics and interaction of these two growth factors¹⁰. During the wound healing process, TGF-1 acts as a chemotaxic factor or dissociating factor to induce the proliferation and

differentiation of undifferentiated cells into fibroblasts, osteoblasts or chondroblasts¹⁹). Osteocytes synthesize the growth factor, TGF-, and store this growth factor in extracellular matrix, where this growth factor is stored the most in the body. Once bone is injured and the latent form of TGF- is released and activated in acidic state, the activated TGF- would induce the differentiation of undifferentiated mesenchymal cells into fibroblasts, osteoblasts, or chondroblasts. Furthermore, it would stimulate the formation of collagen, fibronectin or plasminogen activating factor in osteocytes²⁰⁻²²). Also in the present study, the expression of TGF-1 protein was increased in the early stage of implantation in all experimental groups but decreased by 4 weeks. The expression was shown related with inflammatory cells such as in extracellular matrix, mesenchymal cells similar to fibroblasts, or vascular endothelial cells. On the other hand, the expression of TGF-1 was also decreased as inflammation response decreased.

In this study, the expression of TGF-1 mRNA was weak in all experimental groups. However, considering the basal level of expression, the expression of mRNA could be confirmed. However, this expression was shown the strongest by 1 week after implanting particulate dentin and decreased gradually afterwards. With this result, we could not tell whether only particulate dentin would induce TGF-1. However, we could not ignore the possibility that the expression of TGF-1 mRNA may have been the highest before 1 week, considering the finding from distraction osteogenesis (DO) that the expression of TGF-1 mRNA was the highest in DO 4-day group, which was 450% of the normal level and gradually decreased to the point that it was 82% by DO 7 days⁸). Thus, we need to examine the expression of mRNA and its protein by less than 1 week of implantation to confirm the expression of mRNA.

CONCLUSION

In this study, we observed the mRNA expression of TGF-1, which is a well-known growth factor, after the implantation of particulate dentin and plaster of Paris into bone defect areas. According to the results, the expression of TGF-1 mRNA was very weak and was strongest by 1 week of particulate dentin implantation. However, the expression of TGF-1 protein was observed in all study groups including in the control group. It was particularly increased uniformly in cells participating in

new bone formation, suggesting that new bone formation was promoted by inducing TGF-1 protein, which is bone growth hormone by various bone graft materials. Although we believed that TGF-1 would promote bone formation after the implantation of bone graft materials, this promotion was not significant compared with the defect in the control group. Thus, we believe that particulate dentin and plaster of Paris used in this study promoted osteoconduction, rather than stimulating bone formation, as found in the previous studies. In all experimental groups, the expression of TGF-1 protein was strong by 1 and 2 weeks of graft implantation and weak by 4 and 8 weeks, suggesting that other growth factors might be involved after the healing process.

REFERENCES

1. Kim SG, Yeo HH, Kim YK: Grafting of large defects of the jaws with a particulate dentin-plaster of Paris combination. *Oral Surg Oral Med Oral Pathol Oral Radiol Endod* 1999;88:22.
2. Kim SG, Kim HK, Lim SC: Combined implantation of particulate dentin, plaster of Paris, and a bone xenograft (Bio-Oss) for bone regeneration in rats. *J Cranio-Maxillofac Surg* 2001;29:282.
3. Kim SG, Chung JH, Kim YK, et al: The use of particulate dentin-plaster of Paris combination with/without platelet-rich plasma in the treatment of bone defects around implants. *Int J Oral Maxillofac Implants* 2002;60:82.
4. Kim SG, Kim WG, Park JC, et al: A comparative study of osseointegration of AVANA implants in a demineralized freeze-dried bone alone or with platelet-rich plasma. *J Oral Maxillofac Surg* 2002;60:1018.
5. Kim SY, Kim SG, Lim SC, et al: Effects on bone formation in ovariectomized rats after implantation of particulate dentin and plaster of Paris mixture. *J Oral Maxillofac Surg* 2004;62:852.
6. Moghaddam H, Sandor GKB, Holmes HHI, et al: Histomorphometric evaluation of bone regeneration using allogeneic and alloplastic bone substitutes. *J Oral Maxillofac Surg* 2004;62:202.
7. Kanyama M, Kuboki T, Akiyama K, et al: Connective tissue growth factor expressed in rat alveolar bone regeneration sites after tooth extraction. *Arch Oral Biol* 2003;48:723.
8. Yates KE, Troulis MJ, Kaban LB, et al: IGF-1, TGF-, and BMP-4 are expressed during distraction osteogenesis of the pig mandible. *Int J Oral Maxillofac Surg* 2002;31:173.
9. Yeung HY, Lee KM, Fung KP, et al: Sustained expression of transforming growth factor-1 by distraction during distraction osteogenesis. *Life Sci* 2002;71:67.
10. Lalani Z, Wong M, Meng EMB, et al: Spatial and temporal localization of transforming growth factor-1, bone morphogenic protein-2, and platelet-derived growth factor-A in healing tooth extraction sockets in a rabbit model. *J Oral Maxillofac Surg* 2003;61:1061.
11. Urist MR: Bone: formation by autoinduction. *Science* 1965;150:893.
12. Sakou T: Bone morphogenetic proteins: from basic studies to clinical approaches. *Bone* 1998;22: 591.
13. Joyce ME, Roberts AB, Sporn MB, et al: Transforming growth factor-beta and the initiation of chondrogenesis and

- osteogenesis in the rat femur. *J Cell Biol* 1990;110:2195.
14. Wang EA, Rosen V, D' Alessandro JS, et al. Recombinant human bone morphogenetic protein induces bone formation. *Proc Natl Acad Sci USA* 1990;87:2220.
 15. Ryseck RP, Macdonald-Bravo H, Mattei MG, et al: Structure, mapping, and expression of fisp-12, a growth factor-inducible gene encoding a secreted cysteine-rich protein. *Cell Growth Differ* 1991;2:225.
 16. Bork P: The modular architecture of a new family of growth regulators related to connective tissue growth factor. *FEBS Lett* 1993;327:125.
 17. Brigstock D: The connective tissue growth factor/cysteine-rich/nephroblastoma overexpressed (CCN) family. *Endocr Rev* 1999;20:189.
 18. Lau LF, Lam SC: The CCN family of angiogenic regulators: the integrin connection. *Exp Cell Res* 1999;248:44-57.
 19. Sporn MB, Roberts AB. The multifunctional nature of growth factors. In: Sporn MB, Roberts AB, editors. *Handbook of experimental pharmacology: Peptide growth factors and their receptors*. New York: Springer-Verlag 1990:3-15.
 20. Robey PG, Young MF, Flanders KC, et al: Osteoblasts synthesize and respond to transforming growth factor-type beta (TGF-beta) *in vitro*. *J Cell Biol* 1987;105:457.
 21. Lind M, Schumacker B, Soballe K, et al: Transforming growth factor-beta enhances fracture healing in rabbit tibiae. *Acta Orthopaed Scand* 1993;64:553.
 22. Terrell TG, Working PK, Chow CP, et al: Pathology of recombinant human transforming growth factor-beta 1 in rats and rabbits. *Int Rev Exp Pathol* 1993;34:43.