

다형성 선종에서 발생한 구개부의 상피성-근상피암종

김경욱 · 한세진

Abstract (J. Kor. Oral Maxillofac. Surg. 2007;33:479-484)

EPITHELIAL-MYOEPITHELIAL CARCINOMA ARISING IN PLEOMORPHIC ADENOMA OF PALATE

Kyung-Wook Kim, Se-Jin Han

Dept. of Oral and Maxillofacial Surgery, College of Dentistry, Dankook University

A case of epithelial-myoepithelial carcinoma transformed in pleomorphic adenoma occurring in palate of a 61 years old woman is reported. The tumor was composed of 2 different components, pleomorphic adenoma and epithelial myoepithelial carcinoma, accounting for approximately 40% and 60% of whole tumor, respectively.

As the results of the immunohistopathologic study, epithelial-myoepithelial carcinoma showed multiple tubular or solid nest, which were separated by a basement membrane and considered of variable proportion of 2 cell types, cuboidal epithelial cells positive for cytokeratin and clear myoepithelial cells positive for glial fibrillary acid protein, whereas the myoepithelial nest of pleomorphic adenoma intermingled with hyaline and myxoid stroma. The malignancy was demonstrated by convincing evidence of invasion into the submucosa, although the epithelial-myoepithelial carcinoma component was mostly surrounded by the pleomorphic adenoma components. An increased immunoreactivity of proliferating cell nuclear antigen in the epithelial myoepithelial carcinoma area in comparison to the pleomorphic adenoma also suggested epithelial-myoepithelial carcinoma arising in a pleomorphic adenoma.

Key words: Epithelial-myoepithelial carcinoma, Pleomorphic adenoma, Immunohistopathologic study

I. 서론

가 ,¹⁾ ,²⁾ , 2-10% anaplasia, mitosis

가 (undifferentiated carcinoma) (poorly differentiated adenocarcinoma) , (epidermoid carcinoma) (mucoepidermoid carcinoma)^{3,5)}

1% 가 clear 가 (band) (tumor island) 가 (multinodular) clear 가

김 경 욱
330-716 충남 천안시 신부동 산 7-1번지
단국대학교 치과대학 구강악안면외과학교실
Kyung-Wook Kim
Dept. of Oral & Maxillofacial Surg., School of Dentistry,
Dankook University, 7-1 Sinbudong, Cheonan, 330-716, Korea
Tel: 82-41-550-1993 Fax: 82-41-551-8988
E-mail: kkwoms@dku.edu

가 가^{6,8)} 가

가

1cm

가

II. 증례 보고

· 환 자 : ○○, 61

· 주 소 :

· 전신 병력 :

· 병 력 : 10

· 임상적 소견 : 가

1cm

· 방사선학적 소견 :

(Fig. 1).

· 치료 및 경과 :

6

가

(Fig. 2, 3).

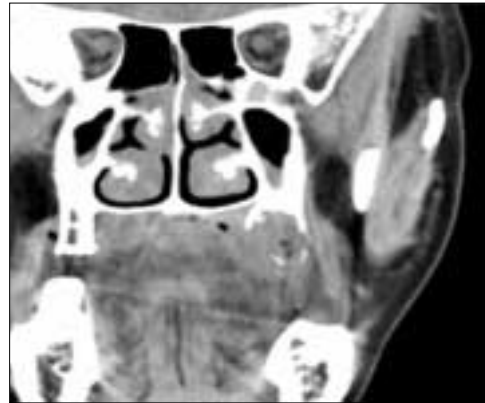
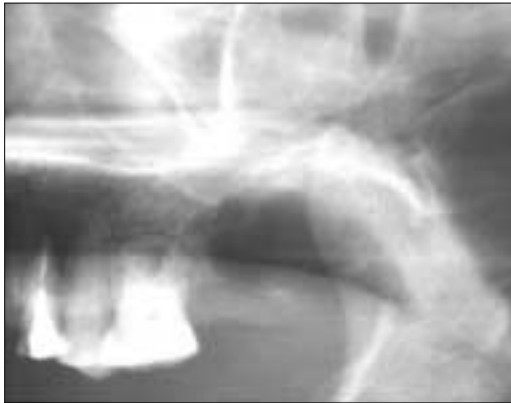
Fig. 1. Preoperative panoramic and CT view : bony involvement of the left posterior maxilla.

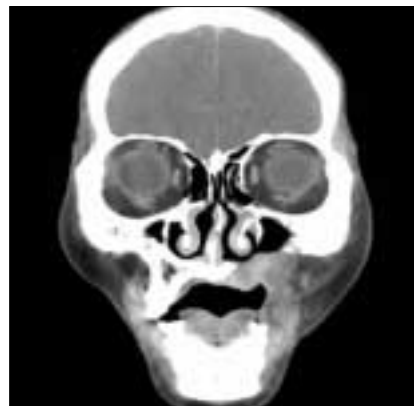
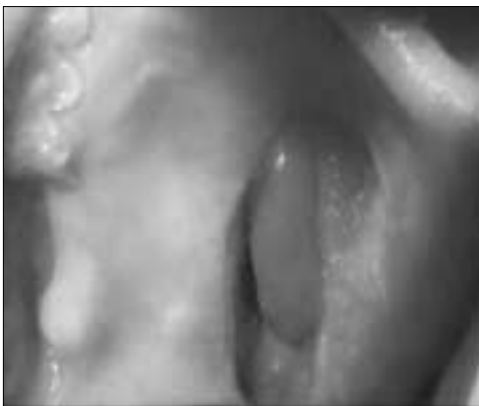
Fig. 2. After 6 months, postoperative intraoral photograph and CT view : no evidence of the recurrence.

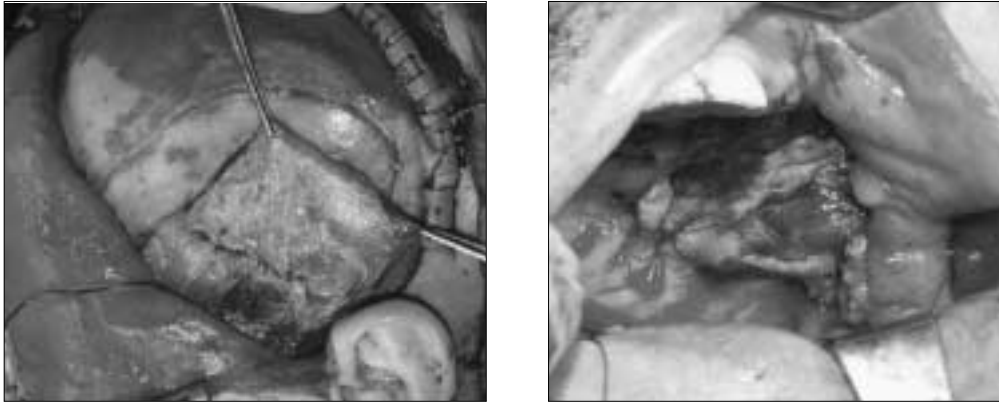


Fig. 3. Delayed reconstruction with the left temporal muscle flap.

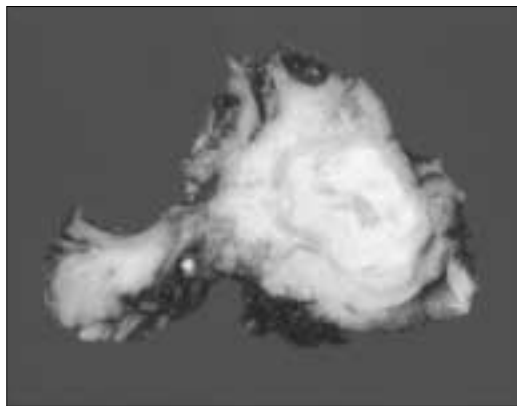


Fig. 4. Macroscopic findings in the specimen : an ovoid, non-encapsulated and gray-white solid mass, measuring 1cm in greatest dimension.

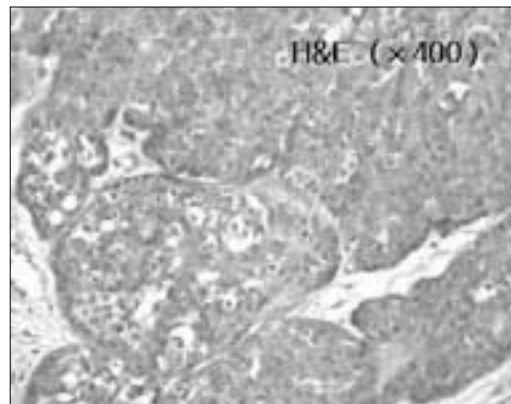
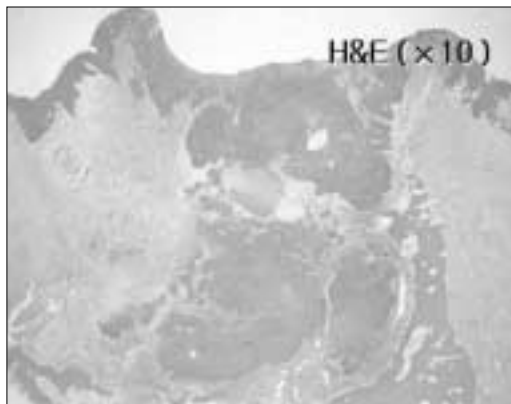


Fig. 5. H & E staining findings : Infiltrative growth into the overlying mucosa and underlying maxillary bone($\times 10$), composed of polygonal epithelioid cells with moderate nuclear pleomorphism, prominent nucleoli and occasional mitotic figures($\times 400$).

· 조직병리학적 소견 :

H&E(hematoxylin & eosin)

(Fig. 4).

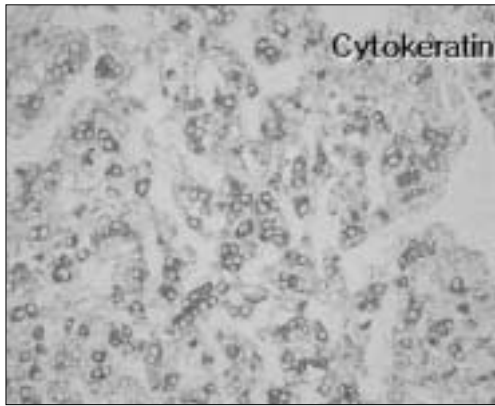


Fig. 6. Cytokeratin immunohistochemical findings : strongly positive(x200).

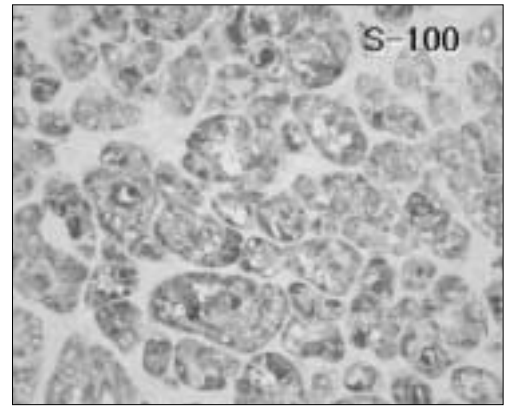


Fig. 7. S-100 immunohistochemical findings : strongly positive(x200).

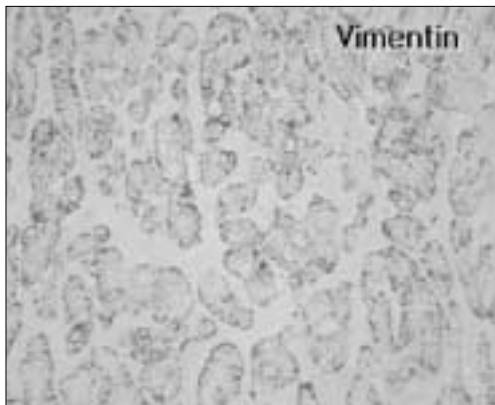

Fig. 8. Vimentin immunohistochemical findings : strongly positive(x200).




Fig. 9. Smooth muscle actin immunohistochemical findings : weakly positive(x200).

(nuclear pleomorphism), (mitotic figure) (Fig. 5).
 cytokeratin, S-100, vimentin smooth muscle actin
 , cytokeratin, S-100, vimentin smooth muscle actin (Fig. 6, 7, 8&9).

III. 총괄 및 고찰

60
 ,
 ,
 -
 -

2가
 (nest) (dense)
 (nest) (myxoid)
 가
 Steifert Donath⁹⁾
 2가
 hybrid tumor
 hybrid tumor . Grenko¹⁰⁾
 3
 2
 -

hybrid tumor
 Warthin
 가
 (monomorphic foci) 가
 (basal cell adenoma),
 clear cell change
 (bi phasic)
 가
 가
 가
 PCNA (proli-ferating cell nuclear antigen)
 11)
 Cytokeratin
 (intermediate filament)
 keratin
 S-100 2 polipepti
 de chain 가 acidic protein (myoepithelial cell),
 (ductular epithelial cell)
 (chondrocyte)
 Vimentin (mesenchymel cell)
 intermediated filament
 12-14)
 man Alguacil-Garcia¹⁵⁾
 clear cell carcinoma
 clear cell
 16),
 가
 17).

phenotypic expression
 가
 40-50% 가³⁾
 가 가
 8
 17)
 16)
 (low-grade)
 15)

IV. 요약

가

참고문헌

1. Stifert G: Histologic typing of salivary gland tumors. 2nd ed. Berlin; Springer-Verlag. 1992.
2. Waldron CA: Mixed tumor(pleomorphic adenoma) and myoepithelioma. In: Ellis GL, Auclair PL, Gnepp DR. editors. Surgical pathology of the salivary glands. Philadelphia: WB Saunders Company 1991; 65-86.
3. Gepp DR, Weinig BM: Malignant mixed tumors. In: Ellis GL, Auclair PL, Gnepp DR. editors. Surgical pathology of the salivary glands. Philadelphia WB Saunders Company: 1991;350-68.
4. Nago K, Matsuzaki O, Saiga H, et al.: Histopathologic studies in carcinoma in pleomorphic adenoma of the parotid gland. Cancer 1981;48:113-121.
5. Gnepp DR: Malignant mixed tumors of the salivary glands; a review. Path Annu 1993;28:279-328.
6. Corio RL: Epithelial-myoepithelial Carcinoma. In: Ellis GL Auclair PL, Gnepp DR. editors. Surgical pathology of the salivary glands. Philadelphia: WB Saunders Company: 1991;412-21.
7. Tralongo V, Daniele E: Epithelial-myoepithelial carcinoma of the salivary glands: a review of literature. Anticancer Res 1998;18:602-8.
8. Kusama K, Saito M, Kozu M, et al.: Epithelial-myoepithelial carcinoma of the palate. J Oral Pathol Med 1996;25:463-6.
9. Steifert G, Donath K: Hybrid tumors of salivary glands. Definition and classification of five rare cases. Oral Oncol Eur J Cancer 1996;32B:251-259.
10. Grenko RT, Abendroth CS, Davis AT, et al.: Hybrid tumors or salivary glands tumors sharing common differentiation pathway. Re-examining adenoid cystic and epithelial-myoepithelial carcinoma. Oral Sur

- g Oral Med Oral Path Oral Radiol Endod 1998;86:188-195.
11. Zhu Q, White FH, Tioe GL: The assessment of proliferating cell nuclear antigen(PCNA) immunostaining in human benign and malignant epithelial lesions of the parotid gland. Oral Oncol 1977;33:29-33.
 12. Colvin RB: Diagnostic immunopathology. 2nd. ed. Raven press 1995;455.
 13. Angelov A, Dikranian K, Trosheva M: Immunohistochemical study of pleomorphic adenoma. Bull Group Int Rech Sci Stomatol Odontol 1996;34:67-75.
 14. Moll R, Franke WW, Schiller DL: The catalogue of human cytokeratins: Patterns of expression in normal epithelia, tumors and cultured cells. Cell 1982;31:11.
 15. Litterman C, Alguacil-Garcia A: Clear cell carcinoma arising in pleomorphic adenoma of the salivary gland. Am J Clin Pathol 1987;239-243.
 16. Ostrowski ML, Font RL, Halpern J, et al.: Clear cell epithelial-myoeithelial carcinoma arising in pleomorphic adenoma of the lacrimal gland. Ophthalmology 1994;101:925-930.
 17. Asai S, Tang X, Ohta Y, et al.: Myoepithelial carcinoma in pleomorphic adenoma of salivary gland, occurring in the mandible of an infant. Pathol Int 1995;45:677-683.