

# Oral bisphosphonates induced osteonecrosis of the mandible : A case report

Hyo-jeong Son<sup>1</sup>, Ho-yeol Jang<sup>1</sup>, Yun-seon Keum<sup>1</sup>, Jang-yeol Lee<sup>2</sup>, Hyoun-chull Kim<sup>1</sup>, Sang-chull Lee<sup>1</sup>

<sup>1</sup>Department of oral and maxillofacial surgery, LivingWell Dental Hospital

<sup>2</sup>Department of oral and maxillofacial radiology, LivingWell Dental Hospital

**Abstract** (J. Kor. Oral Maxillofac. Surg. 2009;35:106-111)

Bisphosphonates have been approved for Paget's disease, cancer-related hypercalcemia, bone involvement in multiple myeloma or solid tumors and osteoporosis. Although, underlying pathophysiological mechanisms remain unclear, it seems that bisphosphonates inhibit osteoclast precursor cells, modulate migratory and adhesive characteristics and induce apoptosis of osteoclasts. Furthermore impacts on angiogenesis, microenvironment and signal transduction between osteoclasts and osteoblasts.

In this report, we present a case of oral bisphosphonates induced osteonecrosis of the mandible in a 84-year-old patient who received for two years. Two tapered screw vent implants (Zimmer, USA) were placed in the area of first and second molar. Two weeks later after crowns restored, some inflammatory signs and symptoms were observed on the second molar area. Sequestrum was formed and the sequestrum was removed with the implant. Frequent follow-up checks and oral hygiene maintenances were done and the first molar implant was restored.

There is insufficient evidence suggests that duration of oral bisphosphonate therapy correlates with the development and severity of osteonecrosis. Therefore, dentists should not overlook the possibility of development of bisphosphonate induced osteonecrosis in patients who have taken oral forms of medication for less than three years.

**Key words:** Osteoporosis, Oral bisphosphonates, Osteonecrosis, Complication

## Introduction

Bisphosphonates are drugs that are extensively used in the management of malignancy and metabolic bone conditions such as multiple myeloma, metastatic disease and Paget's disease of bone. Another important indication is in the treatment of osteoporosis.<sup>1</sup> The oral aminobisphosphonates have significantly reduced fracture incidence and the pain and disability in patient with osteoporosis. Despite the benefits related to the use of these medications there is a serious oral complication of bisphosphonate therapy involving the exposure of necrotic mandible or maxilla bone.<sup>2</sup> That is a bisphosphonate induced osteonecrosis and it is recently recognized. The first reports of osteonecrosis of the jaws caused by bisphosphonates were by Marx in September 2003 and the numbers of these cases continues to grow.<sup>2,3</sup>

Certainly, patients receiving intravenous bisphosphonate are more susceptible to bisphosphonate induced osteonecrosis of

the jaw than are those receiving oral bisphosphonates. Publications have estimated a incidence for intravenous bisphosphonate induced osteonecrosis from 0.8% to 30% and for oral aminobisphosphonate-induced osteonecrosis the incidence has been reported to be between 0.007% and 0.01%.<sup>4,5</sup> There have been numerous reports of osteonecrosis of the jaw occurring in patients treated with intravenous bisphosphonates and recently, beginning in 2006, these reports have been concerned about the safety of oral bisphosphonates in patients with osteoporosis.<sup>6</sup>

In this report, we present a case of oral bisphosphonates induced osteonecrosis of the mandible in a 84-year-old patient who received for two years.

## Case report

A 84-year-old man came for dental examination to have his missing teeth - the mandibular left first molar and second molar - restored. The patient had a history of controlled diabetes mellitus and had received medicine for twenty years. Also, he suffered from osteoporosis and received for two years oral bisphosphonates, Fosamax (Merck Co, West Point, VA) 70mg/week. His general health state was approved by the patient's physician, the bisphosphonate would be discontinued

---

**Hyo-jeong Son**

Dept. of OMFS, LivingWell Dental Hospital 110,

Juyeop-dong, Ilsan-gu, Goyang-si, Gyeonggi-do Republic of Korea

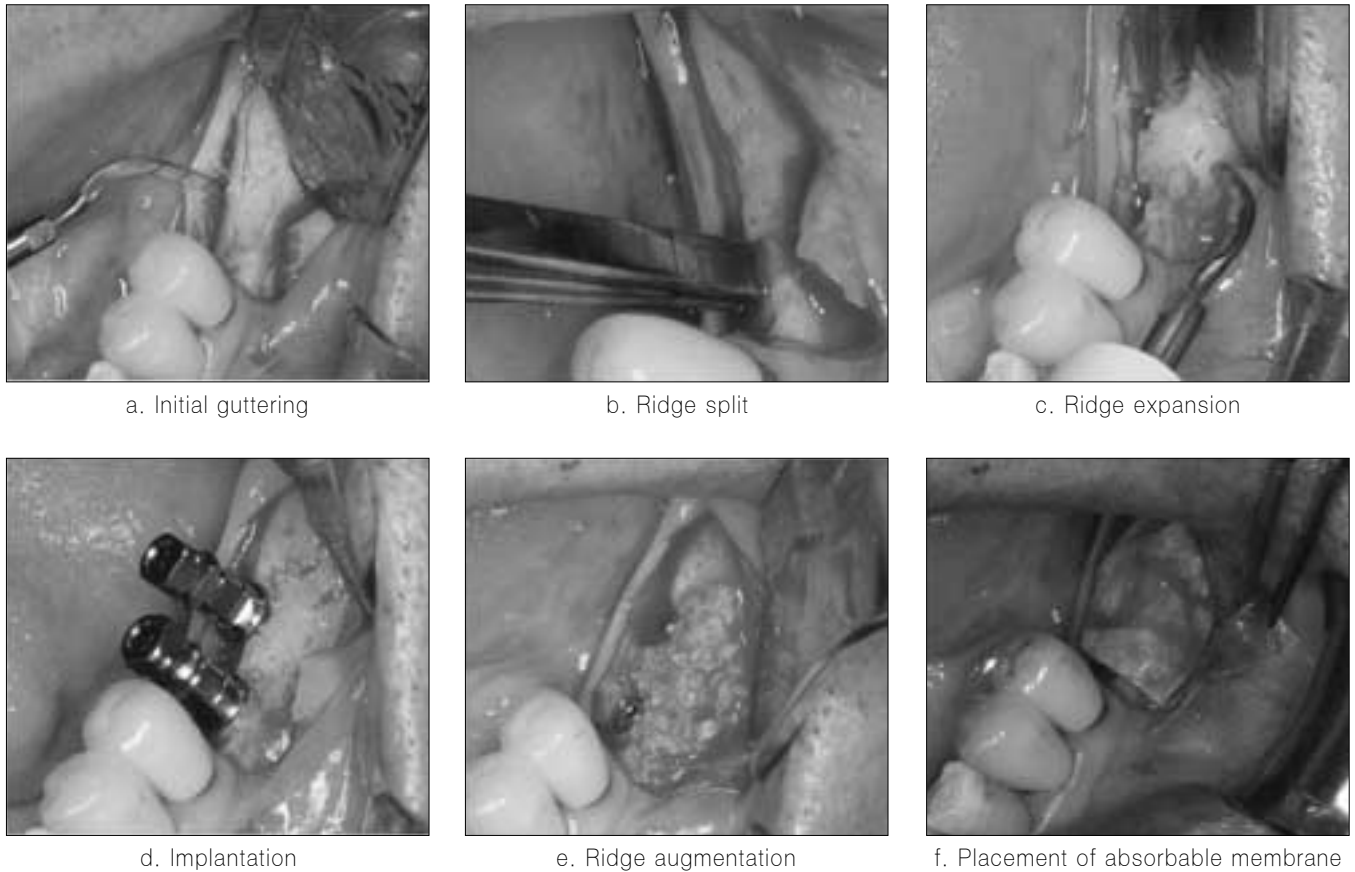
Tel: 031-916-8020 Fax: 031-916-8029

E-mail: livingwell@paran.com

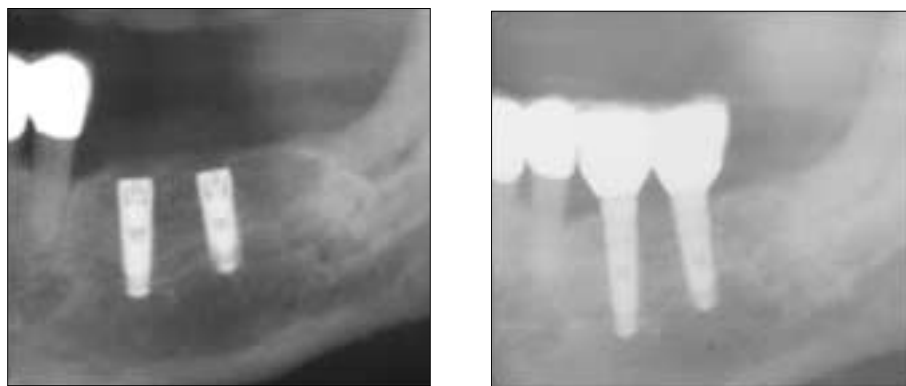for 3 months before the procedure. After thorough clinical and radiographic examination, initial periodontal therapy and implant placement were planned. After periodontal treatment, 2 tapered screw vent implants (Zimmer, USA) were placed in the area of the missing teeth(fig.1).

During the follow up period, no discomfort reported by patient and crowns were fabricated without any problems sev-

en weeks later after surgery. However, two weeks later after crowns restored, some inflammatory signs and symptoms were observed on the second molar area. First, for two weeks, the peripheral bone of the implant was disinfected by Erbium YAG laser. Next, the crowns were disconnected and local rinses with chlorhexidine. Using Erbium YAG laser disinfection was in constant. But, one month later, the peripheral bone of the



**Fig. 1.** Surgical procedure

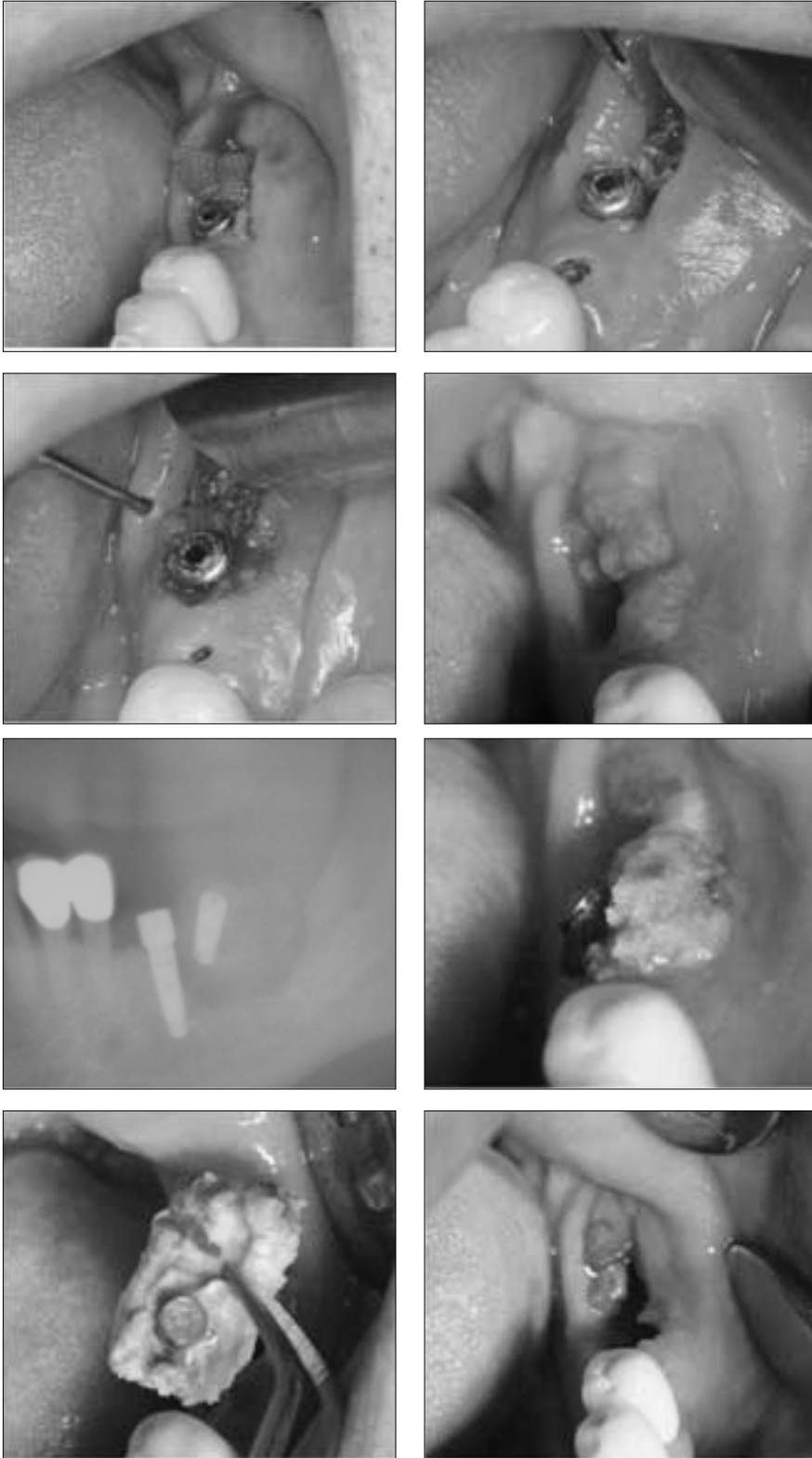


**Fig. 2.** Post operative wound healing was uneventful. Four months later, prosthesis of the implants were fabricated.

implant was exposed and long-term antibiotics were provided for eight weeks. As a result, inflammatory signs and symptoms were thought to be improved (fig. 3). However, fourth months since inflammatory signs and symptoms appeared, the exposed bone became mobile and panoramic radiograph revealed that sequestrum was formed on the second molar area. The

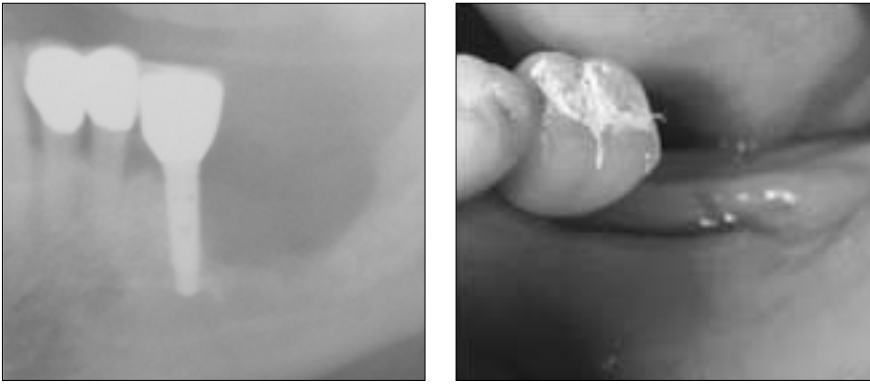
sequestrum was removed with the implant (fig. 4).

Frequent follow up check and oral hygiene maintenance was done and the large osseous defect was healed. The first molar implant was restored with crown and has remained symptom free(fig.5). The patient is called regularly for evaluation and maintenance care.



**Fig. 3.** Inflammatory signs and symptoms were observed. After 3months later, it is thought to be improved.

**Fig. 4.** Sequestrum was formed and it was removed with the implant



**Fig. 5.** The large osseous defect was healed and prosthesis of the implant on the first molar was restored.

## Discussions

Bisphosphonate induced osteonecrosis can be defined as “The unexpected development of necrosis in the oral cavity of a patient who has received bisphosphonates but no radiotherapy to the head and neck”.<sup>7</sup>

The most common clinical features associated with bisphosphonate induced osteonecrosis of the jaw is an ulcer with exposed bone. Similar to osteo-radionecrosis, in the early stages of bisphosphonate induced osteonecrosis, radiographic manifestations can not be seen. Patients may be asymptomatic but may have severe pain when sites become secondarily infected or there is trauma to the soft tissues via the sharp edges of the exposed bone.<sup>7,8</sup>

In our patient, the exposure of the jaw was exceeded more than 8 weeks and no history of radiation therapy to the jaw bones was. So, it could be diagnosed as the bisphosphonate induced osteonecrosis of the jaw by criteria of The American Academy of Oral and Maxillofacial Surgery.<sup>6</sup>

The exact mechanism of bisphosphonate induced osteonecrosis is unclear but, it seems to be as follows. Bisphosphonates bind to bone and incorporate in the osseous matrix. During bone remodeling, the drug is taken up by osteoclasts and internalized in the cell cytoplasm, where it inhibits osteoclastic function and induces apoptotic cell death. Bisphosphonates also inhibit vascularity which could potentiate the ischemic effects. These effects may be cumulative in nature, with minimal trauma resulting in a nonhealing site of bone and eventual osteonecrosis.<sup>10,11</sup>

There are many risk factors of developing bisphosphonate induced osteonecrosis of the jaws. Most common cases of bisphosphonate induced osteonecrosis of the jaws are associated with dentoalveolar surgery especially dental extractions. One study showed the frequency was 7-9 fold higher than in those who did not have extractions.<sup>12</sup> It is revealed weakness to the trauma.

Because bisphosphonates accumulate within the skeleton and have a long half-life, a longer duration of exposure results in a higher risk of bisphosphonate induced osteonecrosis of the jaws. In one study, the risk of developing bisphosphonate induced osteonecrosis of the jaws had a incidence of 1% within the first year of treatment with zoledronic acid, and 15% at 4 years.<sup>13</sup>

The risk could be different from medication routes. Pamidronate and Zoledronate are generally administered intravenously for the management in patients with metastatic bone lesions from breast cancer, multiple myeloma, prostate cancer and in patients with Paget’s disease of bone. The oral aminobisphosphonates alendronate, residronate and ibandronate are used for the treatment of osteoporosis.

Oral bisphosphonates compared with intravenous bisphosphonates, it takes longer to develop bisphosphonate induced osteonecrosis because of slower accumulation in bone. Its clinical expression is also less extensive and its risk of development can be assessed and stratified by a simple blood test.<sup>7,14</sup> The blood test is a morning fasting serum C-terminal telopeptide (CTX), It is an index of bone turnover, with lower values representing suppressed bone turnover and a reduced healing capability. Values more than 150 pg/mL represent minimal or no risk. In many studies said that who has taken an oral bisphosphonate for less than 3 years can be treated as any other patient and although CTX testing may be useful as a reference, it is not necessary with this relatively short duration of bisphosphonate use. And for patients who report oral bisphosphonate use exceeding 3 years, CTX test are recommended.<sup>14</sup>

However, dental practitioners must not overlook easily the possibility of development the bisphosphonate induced osteonecrosis in patient who has taken an oral forms for less 3 years. Because there are fewer patients with osteoporosis who develop this complication, although the one patient developed bisphosphonate induced osteonecrosis of the jaws after 2 years of oral alendronate such as in our case, it is not certain what

the median time of exposure is and other factors of inducing osteonecrosis could be present like advanced age, medical history, and so on.<sup>15</sup>

One study showed that there was a higher prevalence of diabetes in patients with bisphosphonate induced osteonecrosis of the jaws and this to be a significant factor.<sup>16,17</sup> Other suggested comorbidities that have yet to be investigated include peripheral vascular disease and cigarette smoking.<sup>15</sup> Therefore, it must be sure the precise drug, its dose, duration of therapy, and concomitant diseases and medications in their medical histories without exception. Even if the patient has taken oral forms for 2 years in our case, bisphosphonate induced osteonecrosis was developed. It seems to be affected by another factors such as advanced age and diabetes.

Because there is no effective treatment, the goal of treatment is to get the patient comfortable. If the exposed bone is asymptomatic, maintenance with 0.12% chlorhexidine is all that is initially required. If the evidence of infection is present, antibiotics should be provided in addition to the chlorhexidine rinse.<sup>18</sup>

If the exposed bone shows clinical or radiographic evidence of a sequestrum with the anticipation of uncomplicated healing, a local debridement can be planned. In extensive cases where purulent exudates or sinus tracts are visualized, culture and microbial sensitivity testing may be required for more extensive surgical procedures.<sup>19</sup>

A management protocol for patients who receiving bisphosphonate therapy was suggested by Marx, bisphosphonate discontinuation and CTx monitoring may be needed and the CTx level should be greater than 150 pg/mL before surgery. If approved by the patient's physician, the bisphosphonate would be discontinued for 3 months before the procedure and further 3 months following surgery.<sup>20</sup>

Most reports of bisphosphonate induced osteonecrosis of the jaw occur after the patient has been taking bisphosphonates for 6 months or more. So if the patients who are about to start taken bisphosphonates, it may be possible to provide dental care early in the treatment for without development of osteonecrosis from dental treatment.<sup>21</sup> If possible should be delayed receiving bisphosphonates for approximately 4 to 6 weeks after invasive procedures such as dental extractions to give the bone a chance to recover.<sup>2,22</sup> In 2006, Jeffcoat reported the results of 100% success rate of 102 implants with no clinical evidence of infection, pain, or necrosis in the patients who received oral bisphosphonates. The mean duration of bisphosphonate therapy prior to the study was 3 years.<sup>23</sup> In 2008, Bao-Thy Grant reported the results of his study, of the 115 patients taking oral bisphosphonates, none show evidence or gave symptoms of

necrosis. All have had successful implant restorations. The mean duration of oral bisphosphonate therapy was 38 months.<sup>24</sup> Despite the widespread use of oral bisphosphonates, a review of the literature found only one case of dental implant failure associated specifically with oral bisphosphonate use. The case report from 1995 suggested that failure of 5 implants was caused by bisphosphonate therapy. The drug discussed in this case report was etidronate disodium (Didronel; Procterand Gamble).<sup>25</sup>

Bisphosphonate induced osteonecrosis is by no means common, but it could be occur, all patients considering surgical treatments should be asked about bisphosphonate use and should be advised of possible risks. There is insufficient evidence suggests that duration of oral bisphosphonate therapy correlates with the development and severity of osteonecrosis. More data are needed to determine at what point invasive dental treatment such as implant placement should be routinely modified. And additional data are needed to suggest that implant placement, tooth extraction, and other surgical treatments should be routinely avoided for patients receiving oral bisphosphonate therapy.

## Conclusions

Principally, the treatment of patients receiving oral or intravenous bisphosphonates should be preventive. All potential sites of infection must be eliminated and to reinforce the importance of oral hygiene maintenance, frequent periodic follow up visits should be scheduled.

If the patients are suffered from bisphosphonate induced osteonecrosis of the jaw, all dental treatments should be done gently and atraumatically.

Also, significant to dentists, should not overlook the possibility of development the bisphosphonate induced osteonecrosis in patient who has taken an oral forms for less 3 years. each patient should be informed in full about this risk and be got wind of the early signs of development of this condition.

## Reference

1. Assael LA: The science of bisphosphonate related osteonecrosis of the jaws: the thin white line J Oral Maxillofac Surg 2007;65(7):1275-6.
2. Melo MD, Obeid G: Osteonecrosis of the jaws in patients with a history of receiving bisphosphonate therapy: strategies for prevention and early recognition J Am Dent Assoc 2005;136(12):1675-8.
3. Marx RE: Pamidronate (Aredia) and zoledronate (Zometa) induced avascular necrosis of the jaws: a growing epidemic J Oral Maxillofac Surg 2003;61:1115-7.
4. Hoff A: Expert panel recommendation for prevention, diagnosis,

- and treatment of osteonecrosis of the jaws Oncology Drug Advisory Committee Meeting East Hanover, NJ, Novartis, March 4, 2005.
5. Bamias A, Kastritis E, Bamia C, et al: Osteonecrosis of the jaw in cancer after treatment with bisphosphonates: incidence and risk factors *J Clin Oncol* 2005;23:8580-7.
  6. Marx RE: Oral and intravenous bisphosphonate-induced osteonecrosis of the jaws: history, etiology, prevention, and treatment Hanover Park(IL) Quintessence Publishing 2006.
  7. American Association of Oral and Maxillofacial Surgeons position paper on bisphosphonate-related osteonecrosis of the jaws *J Oral Maxillofac Surg* 2007; 65:369-76.
  8. Migliorati CA, Casiglia J, Epstein J, Jacobsen PL, Siegel MA, Woo SB: Managing the care of patients with bisphosphonate-associated osteonecrosis: an American Academy of Oral Medicine position paper *J Am Dent Assoc* 2005;136(12):1658-68.
  9. Catalano L, Del Vecchio S, Petruzzello F, et al: Sestamibi and FDGPET scans to support diagnosis of jaw osteonecrosis *Ann Hematol* 2007;86(6):415-23.
  10. Russell RG: Bisphosphonates: mode of action and pharmacology *Pediatrics* 2007;119 Suppl 2:S150-62.
  11. Roelofs AJ, Thompson K, Gordon S, Rogers MJ: Molecular mechanisms of action of bisphosphonates: current status *Clin Cancer Res* 2006;12(20 Pt 2):6222-30.
  12. Mavrokokki T, Cheng A, Stein B, Goss A: Nature and frequency of bisphosphonate-associated osteonecrosis of the jaws in Australia *J Oral Maxillofac Surg* 2007;65(3):415-23.
  13. Dimopoulos MA, Kastritis E, Anagnostopoulos A, Melakopoulos I, Gika D, Mouloupoulos LA, Bamia C, Terpos E, Tsionos K, Bamias A: Osteonecrosis of the jaw in patients with multiple myeloma treated with bisphosphonates: evidence of increased risk after treatment with zoledronic acid *Haematologica* 2006;91(7):968-71.
  14. Yoh Sawatari, Robert E: Marx, Bisphosphonates and Bisphosphonate Induced Osteonecrosis *Oral Maxillofacial Surg Clin N Am* 2007;19:487-98.
  15. Marx RE, Sawatari Y, Fortin M, Broumand: Bisphosphonate-induced exposed bone (osteonecrosis/osteopetrosis) of the jaws: risk factors, recognition, prevention, and treatment *J Oral Maxillofac Surg* 2005;63(11):1567-75
  16. Khamaisi M, Regev E, Yarom N, Avni B, Leitersdorf E, Raz I, Elad S: Possible association between diabetes and bisphosphonate-related jaw osteonecrosis *J Clin Endocrinol Metab* 2007;92(3):1172-5.
  17. Ardine M, Generali D, Donadio M, Bonardi S, Scoletta M, Vandone AM et al: Could the long-term persistence of low serum calcium levels and high serum parathyroid hormone levels during bisphosphonate treatment predispose metastatic breast cancer patients to undergo osteonecrosis of the jaw? *Ann Oncol* 2006; 17(8):1336-7.
  18. Hellstein JW, Marek CL: Bisphosphonate osteochemonecrosis (bisphosphonate jaw): is this phosphy jaw of the 21st century *J Oral Maxillofac Surg* 2005;63(5):682-9.
  19. Van den Wyngaert T, Huizing MT, Vermorcken JB: Bisphosphonates and osteonecrosis of the jaw: cause and effect or a post hoc fallacy *Ann Oncol* 2006; 17(8):1197-204.
  20. Courtney PA, Hosking DJ, Fairbairn K J, Deighton CM: Treatment of SAPHO with pamidronate. *Rheumatology* 2002; 41:1196-8.
  21. Marx RE: Oral and intravenous bisphosphonate-induced osteonecrosis of the jaws. History, etiology, prevention, and treatment. Quintessence Publishing Co Inc; 2007;9-96.
  22. Advisory Task Force on Bisphosphonate-Related Osteonecrosis of the Jaws, American Association of Oral and Maxillofacial Surgeons position paper on bisphosphonate-related osteonecrosis of the jaws. *J Oral Maxillofac Surg* 2007;65(3):369-76.
  23. Jeffcoat MK: Safety of oral bisphosphonates: Controlled studies on alveolar bone *Int J Oral Maxillofac Implants* 2006;21:349.
  24. Bao-Thy Grant, Christopher Amenedo: Outcomes of placing dental implants in patients taking oral bisphosphonates: A review of 115 cases *J Oral Maxillofac Surg* 2008;66:223-230.
  25. Starck WJ, Epker BN: Failure of osteointegrated dental implants after diphosphonate therapy for osteoporosis: A case report *Int J Oral Maxillofac Implants* 1995;10:74-8.