

Articular loose body, Synovial Chondromatosis of the Temporomandibular Joint : a Case Report

Byung-Joon Choi, Baek-Soo Lee, Yeo-Gab Kim, Yong-Dae Kwon, Young-Ran Kim
Department of Oral & Maxillofacial Surgery, Kyung Hee University Dental School, Seoul, Korea

Abstract (J. Kor. Oral Maxillofac. Surg. 2009;35:310-311)

Synovial chondromatosis is an uncommon disease of cartilage transformation of synovial membrane with formation of loose bodies within the joint space. The involvement of temporomandibular joint is very rare. Symptoms include swelling, pain, stiffness of the jaw, and inability to close the jaw. A case involving the temporomandibular joint(TMJ) and non-symptoms is presented.

Key words: Synovial chondromatosis, TMJ, loose body

(원고접수일 2009. 8. 21 / 1차수정일 2009. 8. 28 / 2차수정일 2009. 9. 7 / 게재확정일 2009. 9. 22)

Introduction

Radiopacities are sometimes observed inside or outside of the temporomandibular joint space. These loose bodies may be present in degenerative joint diseases¹⁾. In rare cases, synovial chondromatosis or chondrosarcoma may also mimic the appearance of loose bodies²⁾. Synovial chondromatosis is a benign pathologic condition characterized by the development of nodules of cartilage within the synovial connective tissues of articulating joints and formation of multiple small foci of hyaline cartilage or hyperplastic synovium in the joints³⁾. The etiology of the disease has not been completely clarified, but may involve secondary reactive metaplasia after trauma or chronic abnormal loading leading to detachment of chondrocytes⁴⁾. Cartilaginous nodules develop which may remain attached to the synovial membrane or detach, calcify and form loose bodies inside the articular space⁵⁾.

Case Report

A 46 years-old female was referred from the Department of Periodontics for the evaluation of right Condyle head(Fig. 1). She had not any discomfort symptoms but many radiopaque calcification were seen her right Temporomandibular joint area

in panoramic view and cone beam CT(Fig. 2).

Mouth opening limitation, tenderness and swelling around on right TMJ were not observed. Slightly flattening was existed on condyle head but it did not cause any other problems.

In fact, she was a patient who had a squamous cell carcinoma on her Mandible. So, we had to operate on marginal mandibulectomy under general anesthesia. After marginal

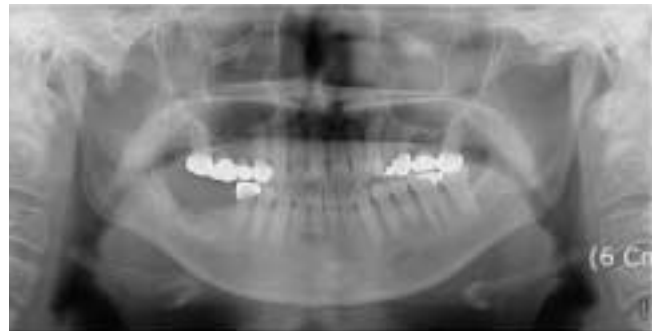

Fig. 1. multiple radiopaque mass at Rt. Condyle head.

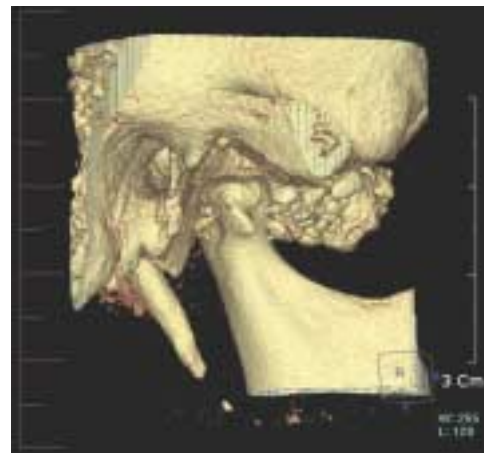

Fig. 2. multiple calcification in cone beam CT.

이백수

130-701 서울특별시 동대문구 회기동 1
경희대학교 치과대학 구강악안면외과학교실

Baek-Soo Lee

Department of Oral & Maxillofacial Surgery Kyung Hee University Dental School
1 Hoegi-dong Dongdaeman-gu, Seoul 130-701, Republic of Korea

Tel: 82-2-958-9440 Fax: 82-2-966-4572

E-mail: leebs@khu.ac.kr

mandiblectomy, we removed multiple calcified masses in the superior joint space(Fig. 3). About 30 calcifications were various size and chondrocytes with hyaline cartilage were observed in microscopic view(Fig. 4). The final diagnosis of synovial chondromatosis was confirmed. Also any other symptoms were not appeared after operation. At present, there has been no evidence of recurrence during the 1 year of follow-up period.

Discussion

Synovial chondromatosis is an uncommon articular disorder of unknown etiology. When the TMJ is involved, the most frequent clinical symptoms are pre-auricular swelling together with joint pain and limitation of mandible movement, and clicking or crepitus on joint motion. But in this case patient did not have any symptom around TMJ. Multiple calcifications were observed around right Condyle head in CT scan. MRI can better define the anatomy of the articular disc and joint cap-

sule, and visualize the boundaries of the lesion with the neighboring anatomical structures, especially extensions out of the joint. If the patient had not been a squamous cell carcinoma patient, surgical excision of the radiopaque mass might have been unnecessary because there were no pre-auricular swelling and no limitation of mouth opening. Under general anesthesia marginal mandiblectomy and multiple calcified masses removal were done in order. Various treatments have been used for synovial chondromatosis of the TMJ. When radiographic findings confirm its location in the upper space, and loose bodies are smaller than the diameter of the arthroscope, it can be treated by arthroscopic surgery. If we did arthroscopic surgery, it was lesser invasive than TMJ open surgery. Therefore further investigations and differential diagnosis are essential before deciding on TMJ open surgery.

Reference

1. Kim IK, Choi J, Oh SS, Oh NS, Kim HD, Lee SH, Yang DH. SYNOVIAL CHONDROMATOSIS OF THE TEMPOROMANDIBULAR JOINT: A CASE REPORT: J. Kor. Oral Maxillofac. Surg. 2000; 26: 109-113.
2. White SC, Pharoah MJ. Oral Radiology Principles and Interpretation, 4th ed. St. Louis, Mosby, 2000, p.520-521.
3. Xu WH, Ma XC, Guo CB, Yi B, Bao SD. Synovial chondromatosis of the temporomandibular joint with middle cranial fossa extension: Int. J. Oral Maxillofac. Surg. 2007; 36: 652-655.
4. Yokota N, Inenaga C, Tokuyama T, Nishizawa S, Miura K, Namba H. Synovial Chondromatosis of the Temporomandibular Joint With Intracranial Extension: Neurol Med Chir(Tokyo) 2008; 48: 266-270.
5. Adachi PL, Kaba SP, Martins MT, Hueb CH, Shinohara EH. Arthrocentesis in the treatment of loose bodies of the temporomandibular joint associated with synovial chondromatosis: Br J Oral Maxillofac Surg 2008; 46: 320-321.
6. Sembronio S, Albiero AM, Toro C, Robiony M, Politi M. Arthroscopy with open surgery for treatment of synovial chondromatosis of the temporomandibular joint: Br J Oral Maxillofac Surg 2008; 46: 582-584.

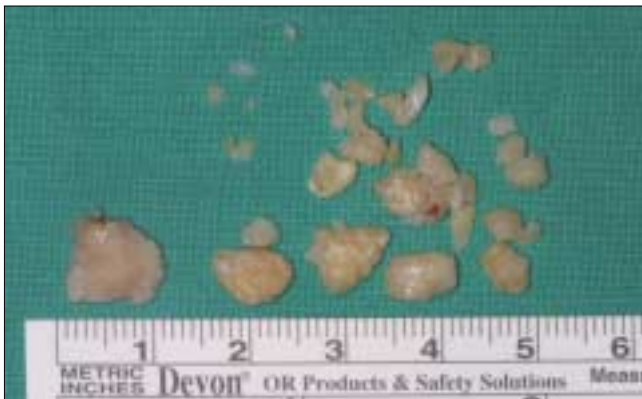

Fig. 3. removed calcified mass.

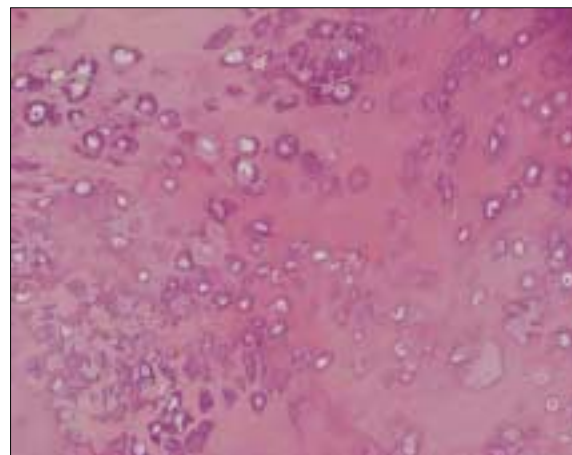
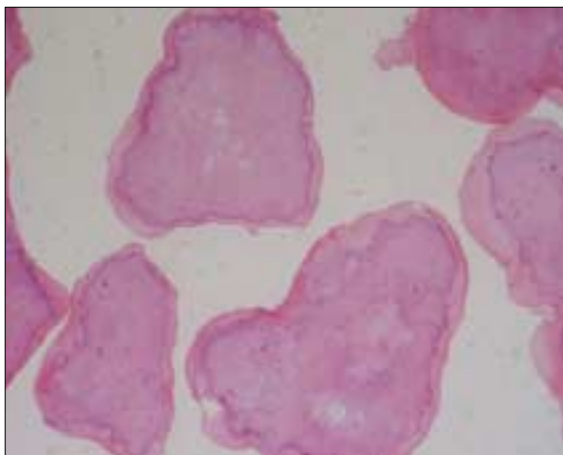


Fig. 4. hyaline cartilage and calcification in microscopic view (H-E stain. ×20 , ×200 original magnification).