

# Cemental Tear : Risk Factor of Localized Irreversible Periodontal Destruction

Assistant Professor  
Department of Periodontics, Loma Linda University

Yoon Jeong Kim DDS, MS

## ABSTRACT

### 백악질 열상 : 국소적인 치주질환의 위험 인자

김윤정

백악질 열상(cemental tear)은 백악질 일부가 치근 표면에서 분리되어 떨어지는 현상으로서, 그 동안 치주문헌에 보고되어 왔으나 많은 임상가들에게 널리 인식되지는 못하였다. 간헐적이지만 백악질 열상의 임상증례들이 지속적으로 보고되고 있으며 이에 따라 백악질 열상을 치주질환과 연관된 병증으로의 이해가 필요하다.

따라서 체계적인 백악질 열상에 관한 연구가 드문 현실에서 단편적으로나마 백악질 열상을 다룬 기존 연구들을 통해 백악질 열상의 임상적 연구의 성과를 정리하고, 병증으로서의 백악질 열상에 대한 종합적 상(像)을 제시하는 것은 중요한 의미를 갖는다. 이를 위해 본 논문에서는 문헌연구를 통해 백악질 열상의 원인과 빈도, 치료 방법, 조직학 및 임상적 소견 등을 분석하고자 한다.

정확한 연구결과는 없지만 백악질 열상의 발생은 과소진단되거나 과소보고되는 것으로 추정된다. 조직학적으로는 백악질이 전체 혹은 일부만 치근표면에서 분리된 소견을 보인다. 임상 증상 및 소견은 다양하게 나타나지만, 통증과 부종 그리고 침상형의 방사선 소견이 주로 보고되었다. 백악질 열상의 전형적인 병증은 뚜렷한 위험 요인이 없이 발생한 국소적이고 급격한 부착수준 소실로 알려져 있다. 백악질 열상의 원인 또는 기여 요인으로는 외상과 노화가 의심되어 지나 정확한 연관관계는 아직까지 연구 된 바 없다.

백악질 열상의 진단은 환자의 병력, 임상증상 및 소견 그리고 방사선 소견 등을 종합하여 이루어지고 있다. 침상형의 방사선 소견은 백악질 열상이 협착 또는 설착에 생긴 경우에는 나타나지 않으므로 진단 시 유의해야 한다는 견해도 제시되고 있다. 문헌에 보고된 백악질 열상의 치료방법은 다양하며, 치료 결과는 대부분의 경우 성공적인 치주낭 깊이의 감소와 방사선적 골의 증가로 나타났다.

본 연구에서는 첫째, 급격하고 국소적인 부착수준 소실의 감별진단 시 백악질 열상은 반드시 포함되어야 할 중요한 병증으로 고려되어야 한다는 점, 둘째, 백악질 열상의 치료계획, 즉 손상된 치주조직의 치유 또는 연관된 치아의 발치 여부 결정은 치아의 전체적인 진단과 예후에 따라 정해져야 한다는 점을 강조하였다.

주요어 : 백악질 열상, 임상 증상 및 소견, 부착수준 소실, 진단, 감별진단, 치료방법

Cemental tear is defined as a fragment of the cementum separating from the underlying root surface<sup>1</sup>. The fragment may be completely, or only partially detached<sup>2</sup>. Cemental tearing is one of “the tooth-related issues that modify or predispose to periodontitis in new classification of periodontal disease”<sup>3-5</sup>. As this entity presents itself infrequently, it has been generally ignored by dental practitioners. There are a limited number of studies or case reports published on this subject, and most concentrate on clinical management, a few supported by histologic evidence. However, continuously reported clinical cases reflect the necessity of a comprehensive understanding of cemental tearing.

Therefore, it would be meaningful to review the literature about cemental tear and emphasize its clinical implication. This article reviews cemental tear: prevalence, histologic findings, clinical characteristics, etiology, and treatment.

## Prevalence

The prevalence of cemental tearing is not known. Leknes et al.<sup>6</sup> suggested that this clinical entity is likely to be highly under-diagnosed and under-reported. While examining extracted teeth specimen, Moskow<sup>2</sup> was able to identify a number of cemental tears. Other clinicians have documented incidental cemental fractures<sup>7-9</sup>.

## Histologic findings

Histologic findings on removed fragments show lamellated layers with inner acellular and outer cellular cementum<sup>10-13</sup>. Based on the macroscopic appearance, as well as, the microscopic structure, Haney et al.<sup>10</sup> concluded that a cemental tear fragment became separated either along the cemento-dental junction or at an incremental line within the cementum (Figure 1). When the cervical portion of a cemental fragment is only partially separated, but extends into the gingival sulcus, calculus deposits may fill the separation gap, bridging the dentinal surface and the separated cementum<sup>2</sup> and junctional epithelium has also been observed in the gap<sup>7</sup>.

## Clinical symptoms and signs

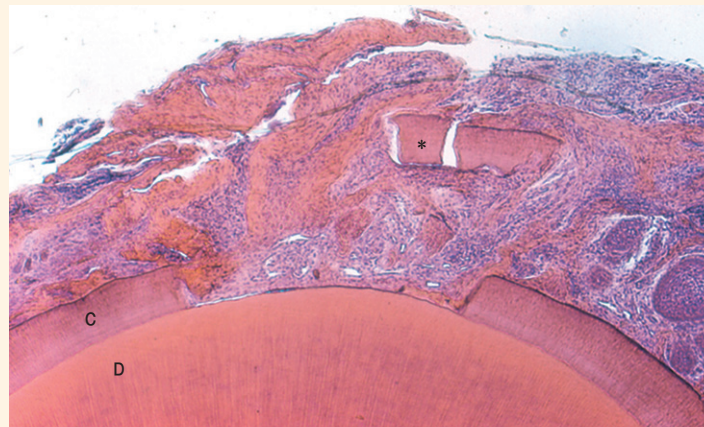


Figure 1.

Photomicrograph, cross section of an extracted tooth.

A case of cementum fracture along the cemento-dental junction

\* : cementum fragment, C : cementum, D : dentin

Originally published in Harvy B, Zander H. Root surface resorption of periodontally diseased teeth. *Oral Surgery Oral Medicine and Oral Pathology*. 1959;12:1439-1443. Courtesy of Dr Knut Selvig

The reported symptoms experienced by patients vary. They are occasionally asymptomatic<sup>14</sup>, sometimes presenting a painless swelling<sup>10, 15</sup> still others associated with acute pain<sup>16</sup>. Mobility is often an independent symptom<sup>17</sup>, but may be accompanied with pain and /or swelling<sup>13</sup>. Suppuration through the sulcus or fistula formation with or without edema is often detected<sup>10, 11, 14, 15, 18</sup>. A ledge like tactile sensation of during regular probing is frequently related to root fractures, in general, including cemental tears<sup>15</sup>.

### Radiographic appearance

Radiographic features of cemental tears depend upon the location of the separation. Only the separation at the proximal surfaces can be detected in two-dimensional imaging. It also depends on the amount of separation. If the extent of separation is minimal, the tear is unlikely to be visible by radiographic assessment.

Cemental tears often present as a radiopaque fragment<sup>10, 11, 13, 15-17</sup>. In some cases, the tear was radiographically found closely related to an intrabony defect<sup>10, 17</sup>. As a consequence of the radiographic uncertainty, Lyons et al.<sup>19</sup> refuted diagnostic dependency on radiographic analysis. The authors argued that tears on the buccal or lingual surface, which are undetectable radiographically, may present a diagnostic dilemma. Several authors have found and supported radiographic diagnostic incapability<sup>14, 18, 20</sup>.

### Localized attachment loss

Localized and rapid attachment loss is a pathognomonic feature of the cemental tear.

Typically, an isolated deep probing depth combined with a prominent attachment loss is noted on a tooth in an otherwise periodontally healthy patient<sup>10, 15, 16</sup>. Leknes et al.<sup>6</sup> demonstrated consistent histologic evidence of attachment loss associated with cemental tears on 17 extracted teeth. Occasionally, clinical attachment loss presents on a different surface than the tear<sup>14</sup>.

### Causes and predisposing factors

There are no existing studies delineating the etiology or pathogenesis regarding cemental tears. Many authors have suggested that trauma and aging are the two main factors that may cause the separation within the cementum<sup>1, 10, 14, 20-21</sup>. For the trauma theory, several authors explained that that weak interconnection at the cemento-dentinal junction is prone to break apart when heavy force is applied to the tooth<sup>6, 22, 23</sup>.

The reduction in collagen fibril attachment and adhesion of proteoglycan of the cemento-dentinal junction following histologic examination in rat and human teeth<sup>24, 25</sup> supports the concept of "weaker interconnection" at the cemento-dentinal junction.

Aging is also postulated as a contributing factor although it remains a controversial issue. Leknes et al.<sup>6</sup> speculated that the aging process of the periodontium affects the remodeling capacity of cementum leading to the cemental tear. In contrast, Lehm and Reissig<sup>12</sup> observed a high periodontal repair activity in a histologic study examining specimens from a 68-year-old female patient.

### Treatment / outcomes

Various treatment modalities have been presented. The extent of tear plays a major role on treatment planning and outcome of the treatment. Treatment modality depends on the clinical parameters of probing depth, amount of bone loss, and morphology of bony defect related to the tear.

As long as the tear is not exposed to the oral cavity, apart from the gingival sulcus, and exhibits no sign of adjacent bone resorption, repair may occur<sup>8</sup> and intervention treatment may not be necessary<sup>11</sup>.

Surgical removal of the fragment if necessary can be accomplished with open flap access<sup>11, 16, 18</sup>. Regenerative attempts have been used, including allograft material<sup>10</sup>, resorbable membrane in 3-wall defect<sup>17</sup>, or different types of resorbable membranes combined with various graft materials<sup>13, 15, 19, 20</sup>. If there is extensive destruction associated with the tear, extraction should be considered<sup>14, 20</sup>.

The longest follow-up after the treatment in the literature is 7 years<sup>16</sup>. All of the reported methods of treatment have resulted in successful

resolution, i.e. a reduction in probing depth and /or radiographic evidence of bone gain.

## Conclusion

The literature has convincingly documented cemental tearing as a clinical entity. It behooves the practicing dentist to include this phenomenon in his/her differential diagnosis, particularly when an unexplained sudden loss of periodontal clinical attachment occurs. The diagnosis should not only rely solely on conventional radiographic findings, because the tear could be on the facial or lingual side and it may not show on two-dimensional radiographic imaging. History of illness, clinical signs and symptoms should be combined to make the diagnosis. However the true diagnosis of cemental tear is only confirmed by histologic examination to determine if the fracture is limited to the cementum. The decision to treat, in hopes of repairing the damaged periodontium, or to extract should be made according to the full complement of diagnostic data pertaining to the current and past clinical characteristics of the

## References

1. Caranza F. The Cementum. In: Glickman's Clinical Periodontology, 6th ed. Philadelphia, PA, USA 1984 p6, pp 60-1
2. Moskow B. Calculus attachment in cemental separations. *J Periodontol.* 1969;40:125-30.
3. Armitage G. Development of a classification system for periodontal diseases and conditions. *Ann Periodontol.*1999;4:1-6.
4. Blieden T. Tooth-related issues. *Ann Periodontol.* 1999;4:91-7.
5. Leknes K. The influence of anatomic and iatrogenic root surface characteristics on bacterial colonization and periodontal destruction: a review. *J Periodontol.* 1997;68:507-16.
6. Leknes K, Lie T, Selvig K. Cemental tear: a risk factor in periodontal attachment loss. *J Periodontol.* 1996;67:583-8.
7. Schaffer E, Zander H. Histologic evidence of reattachment of periodontal pockets. *Parodontologie.* 1953;3:101-7.

## References

8. Grant D, Bernick S. The Periodontium of Aging Humans. *J Periodontol*. 1972;43:660-7.
9. Froum S, Kushner L, Stahl S. Healing responses of human intraosseous lesion following the use of debridement, grafting and citric acid root treatment: clinical and histologic observations six months postsurgery. *J Periodontol*. 1983;54:67-76.
10. Haney J, Leknes K, Lie T, Selvig K, Wikesjo U. Cemental tear related to rapid periodontal breakdown: a case report. *J Periodontol*. 1992;63:220-4.
11. Ishikawa I, Oda S, Hayashi J, Arakawa S. Cervical cemental tears in older patients with adult periodontitis. Case reports. *J Periodontol*. 1996;67:15-20.
12. Lehm A, Reissig D. Histology of 2 cemental tear fractures. A case report *Zahn Mund Kieferheilkd*
13. *Zentralbl*. 1989;77:157-60. Abstract was retrieved March 4, 2006, from PubMed database.
14. Harrel S, Wright J. Treatment of periodontal destruction associated with a cemental tear using minimally invasive surgery. *J Periodontol*. 2000;71:1761-6.
15. Stewart M, McClanahan S. Cemental tear: a case report. *Int Endo J*. 2006;39:81-6.
16. Marquam B. Atypical localized deep pocket due to a cemental tear: case report. *J Contemp Dent Prac*. 2003;15:52-64.
17. Chou J, Rawal B, O'Neil J, Tatakis N. Cementodentinal tear: a case report with 7-year follow-up. *J Periodontol*. 2004;75:1708-13.
18. Muller H. Cemental tear treated with guided tissue regeneration: a case report. 3 years after initial treatment. *Quint International*. 1999;30:111-5.
19. Brunsvold M, Lasho D. Cemental tears related to severe localized periodontal disease. *Practice of Periodontics and Aesthetic Dentistry*. 2000;12:539-40.
20. Lyons C, Peacock M, Cuenin M, Swiec G, Dickey J. Severe localized periodontal destruction associated with cervical cemental separation. *General Dentistry*. 2005;53:212-4.
21. Camargo M, Pirih F, Wolinsky L et al. Clinical repair of an osseous defect associated with a cemental tear: a case report. *Int J Perio Rest Dent*. 2003;23:79-85.
22. Harvy B, Zander H. Root surface resorption of periodontally diseased teeth. *Oral Surg Oral Med Oral Pathol* 1959;12:1439-43.
23. Thoma K, Goldman H. The pathology of dental cementum. *JADA* 1939;26:1949-57
24. Mikola O, Bauer W. Cementicles and fragments of cementum in the periodontal membrane. *Oral Surg Oral Med Oral Pathol*. 1949;2:1063-74
25. Yamamoto T, Wakita M. Initial attachment of principal fibers to the root dentin surface in the rat. *J Periodont Res*. 1990;25:113-9.
26. Yamamoto T, Domom T, Takahashi S. et al. The structure and function of the cemento-dentinal junction in human teeth. *J Periodont Res*. 1999;34:261-8.

## | Acknowledgement |

My great appreciation goes to Dr. Max Crigger for his support and dedicated help. Special thanks are devoted to Dr. Knut Selvig for his photomicrograph.