

Prognosis of Maxillary Sinus Augmentation in the Presence of Antral Pseudocyst: Case Reports

조선대학교 치의학전문대학원 구강악안면외과학교실

마 득 현, 김 수 관, 오 지 수, 유 재 식, 김 원 기, 양 정 은, 임 형 섭

ABSTRACT

Prognosis of Maxillary Sinus Augmentation in the Presence of Antral Pseudocyst: Case Reports

Department of Oral and Maxillofacial Surgery, School of Dentistry, Chosun University
Deuk-Hyun Mah, Su-Gwan Kim, Ji-Su Oh, Jae-Seek You, Won-Gi Kim, Jung-Eun Yang, Hyoung-Sup Lim

Purpose: Antral pseudocyst is a common benign lesion that exists in the maxillary sinus. Because of this possible complication, controversy remains with respect to sinus floor elevation operations. The purpose of this study was to analyze the antral pseudocyst related to maxillary sinus augmentation.

Patients and Methods: The radiographs of 268 patients who visited Chosun University Dental Hospital from 2008 to 2010 and underwent the maxillary bone grafting procedure were examined.

Results: Of the 268 patients who underwent the maxillary bone grafting procedure, 5 patients (1.86%) were diagnosed with antral pseudocysts. In all cases, maxillary sinus floor elevation was performed without aspiration, biopsy or extraction of the antral pseudocyst.

Conclusion: Antral pseudocysts are not considered a contraindication for maxillary sinus bone grafting procedure.

Key words : Dental implant, Cyst, Maxillary sinus

Corresponding Author

Su-Gwan Kim, DDS, PhD

Department of Oral and Maxillofacial Surgery, School of Dentistry, Chosun University, 375, SeoSukDong, DongGu, Gwangju City, Republic of Korea.

Zip Code : 501-759, Phone : 82-62-220-3819, Fax : 82-62-228-7316, E-mail : sgckim@chosun.ac.kr

I. Introduction

The use of sufficient bone volume in the implant placement area is imperative for

achieving a good long-term prognosis for intraosseous implants. To improve the stability of intraosseous implants, partial augmentation is required when vertical deficiency of the alveolar

bone is observed. Insufficient height of the alveolar bone is the most significant factor that limits the placement of the implant in the maxillary molar area. If the pneumatization of the maxillary sinus has progressed greatly or the alveolar bone underwent atrophy due to the edentulous condition over a long period of time, it is difficult to place the implants at the proper height. To resolve these problems, maxillary sinus floor elevation has been developed and makes it possible to place implants in the maxillary edentulous area because of the ridge augmentation involved in this procedure^{1,2)}.

Although the rate of complications from bone grafts in the maxillary sinus is low, various conditions may develop, including perforation of the sinus membrane, bleeding during surgery, risks of postsurgical wound infection and maxillary sinusitis, exposure to graft materials or barrier membranes, infection of graft materials that requires the removal of graft materials, and the dehiscence of valve. In addition to the maxillary sinus bone grafting procedures, dislocation within the maxillary sinus during the placement of the implant or failure of synostosis may also occur³⁻⁷⁾.

The careful selection of patients and the prevention of complications as well as efficient management leads to successful maxillary sinus augmentation⁸⁾. It has been reported that the presence of cystic lesions is a contraindication for maxillary bone grafting procedures. Nonetheless, the classification of cystic lesions in the maxillary sinus and their etiology are controversial issues⁹⁾.

Pseudocysts within the maxillary sinus are typically caused by the retention of inflammatory exudate under the maxillary sinus mucous membrane and appear as hemispheric and even radiopaque lesions in the maxillary sinus floor. Generally, antral pseudocysts are asymptomatic. Nevertheless, although rare, facial dysesthesia and pain in the affected area are observed. Based on radiological analyses, the prevalence is 1.5% - 14%^{10, 11)}. To make the appropriate diagnosis, it is essential to consider the medical history and perform a radiological examination, although biopsies are rarely required. Although antral pseudocysts do not require treatment, a comprehensive evaluation of the adjacent teeth is required. When found, the cause of infection should be removed^{10, 11)}.

The purpose of this study was to evaluate the prognosis of the maxillary bone grafting procedure when antral pseudocysts were detected in the maxillary edentulous area.

II. Patients and methods

The radiographs of 268 patients who visited Chosun University Dental Hospital from 2008 to 2010 and underwent the maxillary bone grafting procedure were examined. Among these, the electronic medical records of patients who were diagnosed with antral pseudocysts by radiography were examined. Age, gender, general disease, medical disease history, the method of sinus floor elevation, the area of implant placement, the diameter and length of the

implant, the bone graft material, complications, follow-up periods, and the treatment of antral pseudocysts were monitored. Using panoramic radiographs and computed tomography images, the location and size of vague radiopaque lesions with a round shape in the maxillary floor, the volume of remaining bones, and the pattern of changes after the procedure were examined.

For maxillary bone graft, either the lateral approach or the alveolar approach was used depending on the volume of the remaining bone in the edentulous ridge of the patient and the preference of the surgeon. Similarly, depending on the bone quality, either a 1-stage or 2-stage method was selected. After the maxillary sinus elevation, depending on the preference of the surgeon, autologous, allogenic, or xenogenic bones, or mixtures thereof were used, and implants with a length of greater than 11 mm were inserted. Each patient received a 375 mg

dose of the antibiotic Augmentin three times per day for 7 days after the procedure, as well as an anti-inflammatory analgesic, 0.2% chlorhexidine, solution for gargling. After the maxillary bone grafting procedure, patients were informed about the potential risks and side effects. In addition, continuous clinical and radiological follow-ups were performed once a month.

III. Results

Of the 268 patients who underwent the maxillary bone grafting procedure, 5 patients (1.86%) were diagnosed with antral pseudocysts (Table 1). Typical hemispheric shapes with an even radiopaque pattern were detected in all patients with antral pseudocysts. Although the lesion boundary was clear, the characteristic thin radiopaque boundary line of the cortical bones

Table 1. Clinical data on patients diagnosed antral pseudocysts

Case	Gender	Age	Diameter of pseudocyst (width x height,mm)	Residual bone height	Sinus augmentation procedure	Site	Implant (diameter x length)	Grafted material	Complication	Follow-up period(m)
1	M	38	19.8 x 18.3	2.5 mm	Lateral app.	#16,17	Osstem GSIII® 5x11.5 2 stage app.	Tutoplast® + Bio-Oss®		28
2	M	65	18.6 x 15.4	3.2 mm	Lateral app.	#24,25,26	3i® 4.5x11.5 2 stage app.	Autogenous bone + Bio-Oss®		43
3	F	60	20.2 x 19.6	6.2 mm	Crestal app.	#15,16	3i® 4.5x11.5 1 stage app.	Autogenous bone + Bio-Oss®		27
4	M	54	24.4 x 22.0	6.4 mm	Crestal app.	#26,27	Dentis® 4.3x12 4.8x12 1 stage app.	Tutoplast® + OCS-B®		17
5	M	75	26.4 x 18.8	4.4 mm	Lateral app.	#14,15,16,17	Astra® 4x13 4x11 4x11 5x11 1 stage app.	Tutoplast® + Bio-Oss®	Sinus membrane perforation	26

typically observed in dental cysts was not visible (Fig. 1). Using panoramic radiographs and computed tomography images, radiopaque lesions with a size ranging from 18.6 mm x 15.4 mm to 26.4 mm x 18.8 mm were observed. However, deformities in adjacent structures, such as humps in the internal and external wall of maxillary sinus, deformities in the external wall of the nasal cavity, and the destruction of the eye socket, among others were not detected. In addition, movability of the teeth in the corresponding area,

facial pain, edema, nasal obstruction and other specific clinical symptoms were not detected.

In all cases, maxillary sinus floor elevation was performed without aspiration, biopsy or extraction of the antral pseudocyst. The remaining bone in the maxillary molar area for implant placement was measured to be 2.5 - 6.4 mm; thus, the maxillary sinus floor elevation and bone grafting procedures were performed by either the alveolar crest approach or the lateral approach (Fig. 2). During surgery, complications

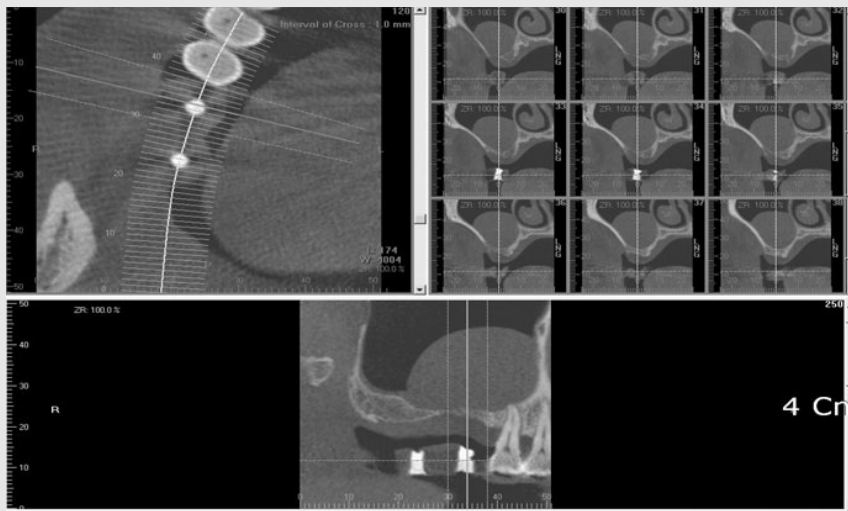


Fig. 1. Cone beam CT findings show a dome-shaped radiopacity diagnosed as an antral pseudocyst.

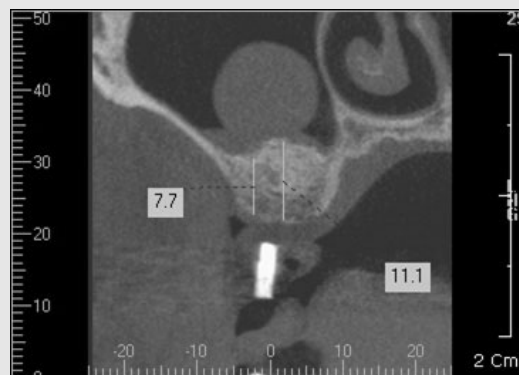


Fig. 2. After sinus floor elevation, cone beam CT finding shows the remaining radiopaque lesion.

from the perforation of the maxillary membrane were observed in only one case; therefore, treatments applying absorbable membranes were performed. With the exception of these perforations, no other complications during or after surgery were observed. Follow-ups were continued for 17 to 43 months. Bone resorption in the vicinity of implant was not observed, the prostheses were maintained, and additional clinical symptoms in the surgical area did not develop. During the radiological examinations, specific changes such as the expansion of the radiopaque lesion within the maxillary sinus or the deformation and destruction of adjacent bones were not observed (Fig. 3).

IV. Discussions

Maxillary sinus floor elevation considered an effective method with low failure rate. Maxillary sinus floor elevation is a procedure that has been widely applied for the past 20 years. Nonetheless, frequent erroneous treatment plans and improper implementation of the procedure

has caused various complications¹². The possibility of postsurgical complications is always present and thus should be carefully considered.

One of the most important causes of postsurgical complications is the presence of a poor pre-surgical clinical condition. For evaluation of diseases in the maxillary sinus that are pertinent to the maxillary sinus floor elevation, the application of computed tomography is recommended for all cases. If a non-infectious maxillary sinus disease are detected, a biopsy should be performed immediately. If cysts or tumors are found, their removal should be considered. To optimize the surgical procedure environment, chronic maxillary sinusitis should be managed with decongestants, anti-histamines, steroids, and antibiotics. If conservative treatments fail, endoscopic maxillary surgery to induce the release of maxillary sinus secretion by widening the original opening of the maxillary sinus should be performed¹³.

Radiopaque cystic lesions within the maxillary sinus can be divided into the following: sinus

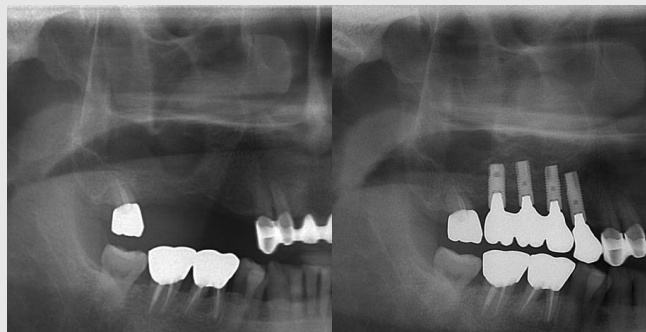


Fig. 3. A different patient's radiological profile comparing the pre-operation and post-operation appearance of the antral pseudocyst.

mucocele, postoperative maxillary cyst, mucous retention cyst, and antral pseudocyst. Sinus mucocele is a true cyst lined with epithelium, wherein the obstructed maxillary sinus space is filled with a mucous secretion. When the normal excretion route of the maxillary sinus is obstructed or the obstructed gland expands continuously, a maxillary sinus mucocele may develop, which may completely fill the maxillary sinus and thus appear as a radiopaque lesion that fully or partially fills the maxillary sinus. In the maxillary bone structure, due to inflammatory reactions, bone remodeling gradually takes place, and eventually, the maxillary sinus wall becomes thin. A conservative treatment of maxillary sinus mucocele includes cyst enucleation or marsupialization.

Maxillary sinus mucocele could expand and invade the adjacent structures such as the eye socket and the cranial cavity, among others and can be observed in radiographic images. Because these characteristics are difficult to distinguish from malignant lesions, a biopsy must be performed during the diagnosis. A postoperative maxillary cyst is a type of maxillary sinus mucocele that is developed after a Caldwell-Luc procedure and other surgeries or trauma. Common clinical symptoms include headaches, ophthalmic abnormalities, expansion of the cheek area and nasal obstruction, and sometimes, the dislocation of maxillary teeth. The inside of the cyst is filled with yellow, green or gray mucus or a suppurative exudate, and the epithelial lining of the cyst reveals a pattern of the maxillary mucous membrane consistent with

a chronic inflammatory condition. The postoperative maxillary cyst should be surgically removed. A mucous retention cyst develops because of the obstruction of mucous glands. Normally, the mucous glands are present in the vicinity of the maxillary ostium, but due to continuous infection, they proliferate and can be detected as polyp patterns. Because most mucous retention cysts are small, it is challenging to detect them using clinical radiography. Their etiology is considered to be an allergic reaction. Unless they expand greatly and become obstructive lesions, treatment is not required. Antral pseudocyst is a disease that is detected most frequently in panoramic radiographs obtained during dental treatments and presents as a hemispheric lesion with even radiopacity in the maxillary sinus floor caused by the retention of inflammatory exudate under the maxillary mucous membrane. The level of radiopacity is such that normal anatomical structures within the lesion can be observed without hyperosteotics. The definition of a pseudocyst is that it lacks the cystic wall formed by the epithelium. It has been reported that the incidence of antral pseudocyst is 1.5% - 14%^{10, 11, 14, 15}, and they may develop in cases of odontogenic infection in the vicinity, infection within the maxillary sinus, and allergic reactions. Nonetheless, the precise etiology of this condition is not known. Clinical disease history and radiological examination are essential for a proper diagnosis, whereas biopsies are not required because the disease can be adequately diagnosed by the radiological characteristics. Antral pseudocysts do not require

special treatment. Nevertheless, a comprehensive evaluation of adjacent teeth is required. If the cause of infection is detected, it should be removed^{10, 11, 14, 15}.

In patients with cystic lesions in the maxillary sinus, the indication for a maxillary sinus floor elevation is not obvious. Ziccardi considered maxillary mucous retention cysts to be a contraindication for maxillary sinus augmentation⁹. However, in their study, the definition of a mucous retention cyst and an antral pseudocyst was not clear. They suggested removing or aspirating cysts prior to maxillary sinus floor elevation. Nevertheless, most maxillary mucous retention cysts and pseudocysts are asymptomatic, and if they are not associated with the symptoms of maxillary obstruction, surgery is not generally recommended⁹. In addition, in other studies, antral pseudocysts were not considered a contraindication for maxillary sinus floor elevation¹⁶⁻¹⁸. It has been reported that when pseudocysts are present, the risk of perforation is rare due to thickening of the maxillary mucosal membrane¹⁹.

Recently, a study has been performed wherein a small bone window with a diameter of 5 mm in the lateral wall of the maxillary sinus was formed, and an antral pseudocyst was removed 3 months prior to performing the maxillary sinus floor elevation²⁰. In this study, follow-ups on antral cystic lesions were performed for 38 to 102 months using Water's radiography. The size of the lesions increased by 29.4%²⁰. Therefore, obstruction of the maxillary sinus ostium was

induced, indicating that bone grafting and implant placement had failed. The removal of antral pseudocysts was achieved using a minimally invasive procedure because cystic lesions could not be definitively diagnosed without a biopsy²¹.

The prevalence of antral pseudocysts can be determined by the presence of hemispheric radiopaque shapes in the radiographs and is estimated to be 1-10% by panoramic radiography²², 12% by CT, and 21% by MRI²³. In most cases, unless the enlargement of the lesion is clearly detected radiologically or associated with symptoms such as headaches, treatment is not required. Nonetheless, if a lesion is large or if the diagnosis is not clear, more evaluation is necessary prior to performing surgical procedures.

In our cases, the patients did not show symptoms pertinent to diseases within the maxillary sinus; moreover, bone destruction and other findings were not detected radiologically. Thus, the patients were diagnosed with antral pseudocysts, and maxillary sinus floor elevation was performed without any presurgical treatments for the cystic lesions. Afterwards, the clinical and radiological follow-up results confirmed that maxillary sinus floor augmentation was performed in a typical fashion, and the bones adjacent to implants were well-maintained without significant changes after the placement of the implant and even after completion of the prosthesis. In addition, the antral pseudocysts that were detected during the evaluation prior to the procedure did not exhibit

any enlargement of the lesion or symptoms of diseases in the maxillary sinus.

V. Conclusions

When antral pseudocyst lesions are present, prior to performing maxillary sinus bone grafting procedure, precise diagnosis by the surgeon is required. Antral pseudocysts are not considered a

contraindication for maxillary sinus bone grafting procedure. However, to avoid various complications associated with the maxillary sinus bone grafting procedure, it is necessary to understand the anatomical and physiological characteristics of the maxillary sinus to exercise proper caution. Furthermore, to develop more definitive outcomes, long-term studies on additional cases must be performed.

참고 문헌

1. Aghaloo TL, Moy PK. Which hard tissue augmentation techniques are the most successful in furnishing bony support for implant placement? *Int J Oral Maxillofac Surg* 2007;22:49-70.
2. Browaeys H, Bouvry P, De Bruyn H. A literature review on biomaterials in sinus augmentation procedures. *Clin Implant Dent Relat Res* 2007;9:166-177.
3. Barone A, Santini S, Sbordone L, Crespi R, Covani U. A clinical study of the outcomes and complications associated with maxillary sinus augmentation. *Int J Oral Maxillofac Surg* 2006;21:81-85.
4. Jensen J, Sindet-Pedersen S, Oliver AJ. Varying treatment strategies for reconstruction of maxillary atrophy with implants: results in 98 patients. *J Oral Maxillofac Surg* 1994;52:210-6; discussion 216-218.
5. Schwartz-Arad D, Herzberg R, Dolev E. The prevalence of surgical complications of the sinus graft procedure and their impact on implant survival. *J Periodontol* 2004;75:511-516.
6. Ardekian L, Oved-Peleg E, Mactei EE, Peled M. The clinical significance of sinus membrane perforation during augmentation of the maxillary sinus. *J Oral Maxillofac Surg* 2006;64:277-282.
7. Regev E, Smith RA, Perrott DH, Pogrel MA.

참 고 문 헌

- Maxillary sinus complications related to endosseous implants. *Int J Oral Maxillofac Implants* 1995;10:451-461.
8. Mardinger O, Manor I, Mijiritsky E, Hirshberg A. Maxillary sinus augmentation in the presence of antral pseudocyst: a clinical approach. *Oral Surg Oral Med Oral Pathol Oral Radiol Endod* 2007;103:180-184.
 9. Ziccardi VB BN. Complications of maxillary sinus augmentation. In: Jensen OT, ed. *The Sinus Bone Graft*. Chicago: Quintessence; 1999:201-208.
 10. Allard RH, van der Kwast WA, van der Waal I. Mucosal antral cysts. Review of the literature and report of a radiographic survey. *Oral Surg Oral Med Oral Pathol* 1981;51:2-9.
 11. Carter LC, Calamel A, Haller A, Aguirre A. Seasonal variation in maxillary antral pseudocysts in a general clinic population. *Dentomaxillofac Radiol* 1998;27:22-24.
 12. Jensen OT, Shulman LB, Block MS, Iacono VJ. Report of the Sinus Consensus Conference of 1996. *Int J Oral Maxillofac Implants* 1998;13:11-45.
 13. RSJ. Maxillary sinusitis: Medical and surgical treatment rationale. Philadelphia, PA: Oral and Maxillofacial Surgery Clinics of North America; 1999:68-69.
 14. Gardner DG. Pseudocysts and retention cysts of the maxillary sinus. *Oral Surg Oral Med Oral Pathol* 1984;58:561-567.
 15. Gardner DG, Gullane PJ. Mucoceles of the maxillary sinus. *Oral Surg Oral Med Oral Pathol* 1986;62:538-543.
 16. Nukhet Celebi, Zeynep Burcin Gonen, Erdem Kilic, Etöz O, Alkan A. Maxillary sinus floor augmentation in patients with maxillary sinus pseudocyst: case report. *Oral Surg Oral Med Oral Pathol Oral Radiol Endod* 2011;112:97-102.
 17. ZH Tang, MJ Wu, WH Xu. Implants placed simultaneously with maxillary sinus floor augmentations in the presence of antral pseudocysts: a case report. *Int J Oral Maxillofac Surg* 2011;40:998-1001.
 18. İsa M Kara, Derviçhan Küçük, Serkan Polatç. Experience of Maxillary Sinus Floor Augmentation in the Presence of Antral Pseudocysts. *J Oral Maxillofac Surg* 2010;68:1646-1650.
 19. Bhattacharyya N. Do maxillary sinus retention cysts reflect obstructive sinus phenomena? *Arch Otolaryngol Head Neck Surg* 2000;126:1369-1371.
 20. Wang JH, Jang YJ, Lee BJ. Natural course of retention cysts of the maxillary sinus: long-term follow-up results. *Laryngoscope* 2007;117:341-344.
 21. Lin Y, Hu X, Metzmacher AR, Luo H, Heberer S, Nelson K. Maxillary sinus augmentation following removal of a maxillary sinus pseudocyst after a shortened healing period. *J Oral Maxillofac Surg* 2010;68:2856-2860.
 22. Lindgren C, Mordenfeld A, Hallman M. A prospective 1-year clinical and radiographic study of implants placed after maxillary sinus floor augmentation with synthetic biphasic calcium phosphate or deproteinized bovine bone. *Clin Implant Dent Relat Res* 2012;14:41-50.
 23. MacDonald-Jankowski DS. Mucosal antral cysts observed within a London inner-city population. *Clin Radiol* 1994;49:195-198.