

2

The importance of individualized and multiple landmarks for the identification of facial nerve trunk: a narrative review

Running title : Identification of facial nerve trunk

KangMi Pang¹, Su Kyung Kuk², Eunhye Choi³

¹Department of Oral and Maxillofacial Surgery, School of Dentistry, Seoul National University

²Division of Biomedical Informatics, College of Medicine, Seoul National University

³Department of Oral Medicine, School of Dentistry and Dental Research, Seoul National University

ORCID ID

KangMi Pang,  <https://orcid.org/0000-0001-9148-9080>

Su Kyung Kuk,  <https://orcid.org/0000-0001-9793-2602>

Eunhye Choi,  <https://orcid.org/0000-0002-6972-4387>

ABSTRACT

The importance of individualized and multiple landmarks for the identification of facial nerve trunk: a narrative review

Running title : Identification of facial nerve trunk

KangMi Pang¹, Su Kyung Kuk², Eunhye Choi³

¹Department of Oral and Maxillofacial Surgery, School of Dentistry, Seoul National University

²Division of Biomedical Informatics, College of Medicine, Seoul National University

³Department of Oral Medicine, School of Dentistry and Dental Research, Seoul National University

The identification of the facial nerve trunk(FNT) is an important step in surgical procedures involving the parotid gland and adjacent structures to minimize the risk of inadvertent nerve damage which leads to facial muscle paralysis. Despite the availability of various anatomic landmarks such as the tragal pointer, posterior belly of digastric muscle, tympanomas-toid suture, digastric branch of facial nerve and styloid process, no single landmark is perfect, with variations observed between individuals. Therefore, a comprehensive knowledge of facial nerve anatomy is essential for FNT identification. In this review, we tried to introduce clinically meaningful methods for the localization of facial nerve trunk. The preference of landmark could be changed by the major of the surgeon or the location of the tumor of the patients. Understanding the characteristics and drawbacks of the landmarks and choosing multiple landmarks that were convenient for surgeon would be necessary.

Key words : facial nerve, anatomic landmarks, parotid region, anatomy regional

Corresponding Author

KangMi Pang, DDS, PhD

Department of Oral and Maxillofacial Surgery, Seoul National University

101, Daehak-ro, Jongno-gu, Seoul, 03080, Republic of Korea

Email : pkm81@snu.ac.kr

I. Introduction

The facial nerve, the 7th cranial nerve, carries nerves involved in facial expression, taste perception for the anterior 2/3 of the tongue, tear production, and moderating sensitivity to noise volume by controlling the stapedius muscles. After emerging from the base of the skull through the stylomastoid foramen(SMF), the facial nerve gives rise to the posterior auricular nerve and the digastric nerve. The main trunk of the nerve then continues anteriorly and inferiorly into the parotid gland, where it bifurcates into upper and lower divisions. Subsequently, it splits into five branches(temporal, zygomatic buccal, marginal mandibular and cervical), responsible for innervating the muscles of facial expression. The portion of the nerve that extends from the SMF to the bifurcation is commonly known as the facial nerve trunk(FNT).

The identification of FNT is a crucial step in parotid surgery because inadvertent damage to the nerve can result in paralysis of half of all the facial muscles of expression, leading to cosmetic deformity, psychological trauma and corneal irritation form lack of motor function¹⁾. Common anatomic landmarks that can indicate the position of FNT include the tragal pointer, posterior belly of digastric muscle, tympanomastoid suture, stylomastoid artery, styloid process and posterior auricular artery^{2,3)}. However, none of these landmarks are perfect, and there can be variations between individuals and even between living patients and cadavers⁴⁾. Therefore, a comprehensive knowledge of its anatomy, meticulous dis-

section and experience are the keys for identification of FNT. The purpose of this review is to provide an overview of the landmarks and methods for the identification of FNT during surgery or anatomic dissection.

II. Anatomical landmarks

There are osseous and soft tissue landmarks in identification of FNT. Well-known bony landmarks include the tympanomastoid suture, mastoid process, C1 transverse process and styloid process. Soft tissue landmarks include the posterior belly of digastric muscle and the tragal pointer(Fig. 1).

1. Tragal pointer

The tragal pointer is the anterior/inferior tip of the tragus portion of the external ear cartilage(Fig. 2). The anterior/inferior part of the tragus, named 'pointer', takes a bluntly pointed shape, directing anterior, inferior and deep to the superficial surface of the preauricular area⁵⁾. It is a widely used landmark, with FNT typically located around 1 cm deep and inferior to the pointer. Additionally, the direction of the tragal cartilage is indicative of the location of the facial nerve. However, the tragal pointer has a blunt, asymmetric and variable tip that can change with retraction, resulting in significant variation in distances from the pointer to the facial nerve⁶⁾. The mean distance from tragal pointer to FNT ranges from 6.37 to 34mm with the overall average of

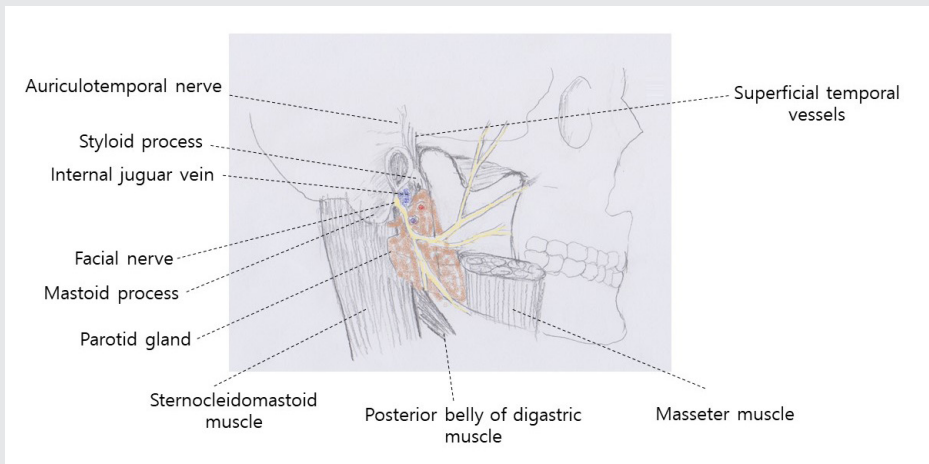


Figure 1. Regional anatomy of facial nerve trunk.

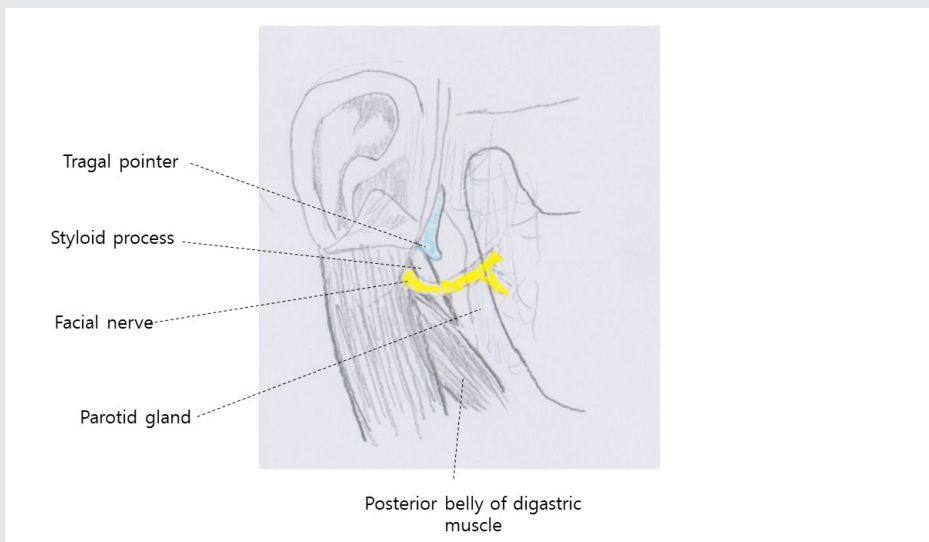


Figure 2. Relation of facial nerve trunk with tragal pointer and the posterior belly of digastric muscle. Facial nerve trunk is known to lie around 1 cm deep and inferior to the pointer. The part of the tragal cartilage is known to direct the facial nerve. As for the digastric muscle, facial nerve trunk runs approximately 1 cm above and parallel to the upper border of the digastric muscle near its insertion point at the mastoid tip.

13.60±11.00mm³). A study compared the cadaver and live patients reported a longer distance in cadaver(13.04 ± 5.238mm) than live patients(9.95 ± 3.967mm) with a statistically significant difference($p = 0.036$)⁴). Considering the direction of the pointer, 20 percent of the pointer pointed to FNT⁷). Nevertheless, due to its ease of dissection, superficial position and reproducibility, the tragal pointer is still routinely used with other landmarks in the identification of FNT.

2. Posterior belly of digastric muscle

During parotidectomy, lateral retraction of the sternocleidomastoid muscle reveals the posterior belly of digastric muscle. This muscle is easily identifiable due to its location and the orientation of muscle fibers, which extend towards the mastoid tip. FNT lies deeper than this plane and runs approximately 1cm above and parallel to the upper border of the digastric muscle near its insertion point at the mastoid tip⁸). Therefore, the upper border of the muscle near the attachment of the mastoid process has frequently been utilized as a landmark for identifying FNT. The mean distance from the digastric muscle ranges from 4.5 to 14.6 with an average of 8.79 ± 3.99 mm³) and Shah et al, reported that the mean distance was similar in cadaver and live patients⁴). Due to its proximity to FNT, minimum anatomical variation, ease of dissection, and exposure during parotidectomy, the posterior belly of digastric muscle is still used as a landmark along with the tragal pointer³).

3. Tympanomastoid suture

The tympanomastoid suture is a bony landmark for identifying FNT. Brintnall et al. described the identification method of FNT using the tympanomastoid suture⁹). Dissection proceeds deeply in the zone behind the parotid gland and close to the cartilaginous ear canal. Between two bony prominences, 1) superiorly, the sharp, fingernail-like bony ridge at the anteroinferior margin of the external auditory meatus of the skull, and 2) inferiorly, the broad blunt anterior margin of the mastoid process of the temporal bone, there is a V-shaped sulcus. The nerve cannot be more than 2 to 3 mm from the depth of the dissection in a pad of loose areolar tissue(Fig. 3). FNT will be exposed by gently spreading the areolar tissue.

The use of tympanomastoid suture as a landmark is controversial. Osseous landmarks are known to be more reliable because of their rigidity. It is a convenient landmark for otolaryngologists who encounter it regularly in tympanoplastic surgery¹). Additionally, the distance to FNT is shorter than other landmarks and there were no significant differences between live patients and cadavers and its relation to the nerve is reliable because it leads to the stylo-mastoid foramen(Fig. 4)⁴). The tympanomastoid suture can be identified in cadavers without much difficulty. However, in surgery, this requires dissection to the periosteum of the fissure, adding unnecessary complexity¹⁰). If the periosteum is not dissected, it is essentially a palpable landmark and direct visualization of the suture is practically not possible⁸).

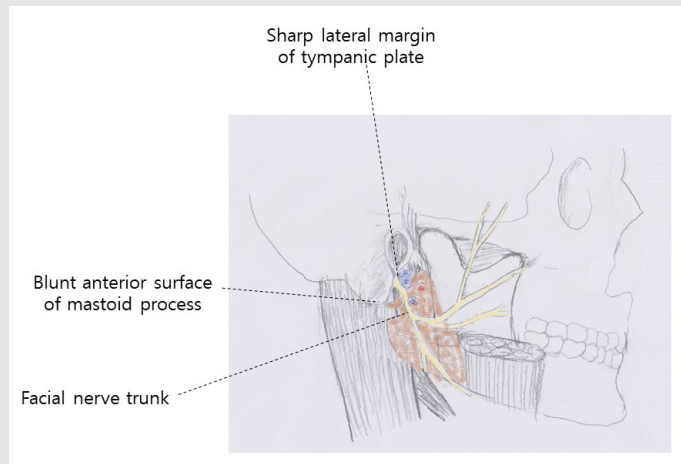


Figure 3. Two bony landmarks utilized to locate the 'palpable sulcus' in which the trunk of the facial nerve is found.

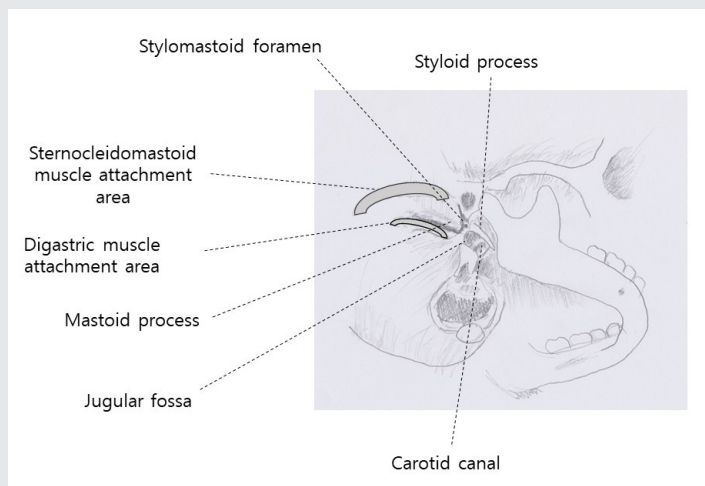


Figure 4. Skeletal bed of the facial nerve from an inferior view. The region containing the tympanomastoid suture extends to the stylomastoid foramen.

Furthermore, it is a comparatively deeper structure, requiring comprehensive digital palpation for its exact identification¹⁰.

4. Digastric branch of the facial nerve

Previous landmarks could be classified as quantitative landmarks as they were based on their distance to FNT, while the digastric branch of the facial nerve(DBFN) could be described as a qualitative landmark. Quantitative landmarks may be unreliable in patients whose anatomy and measurements differ from known measured distances. In such cases, following qualitative landmarks can lead to FNT, because of their direct anatomic relationship with FNT¹¹. DBFN is the second branch of the extratemporal FNT. After exposing the posterior belly of digastric muscle and separating the insertion of the sternocleidomastoid muscle(SCM) onto the tip of the mastoid process to expose the mastoid tip, superomedial aspect of the posterior belly of digastric muscle was evaluated to find the point of innervation by DBFN. Then, DBFN was retrogradely dissected until the identification of its main trunk^{11,12}. The insertion point of DBFN onto the posterior belly of digastric muscle was located on the superomedial aspect of the muscle with a distance of $13.6 \pm 2.0\text{mm}$ (range: 10~17mm) from the tip of the mastoid process. Anterior and medial to DBFN, the stylo-mastoid artery was accompanied¹¹. Although DBFN seemed reliable and consistently identified at the estimated location, only a few studies have been reported and the major anatomical study by Meybodi

et al.(2019)¹¹ was limited to cadaveric study. The fact that DBFN accompanies the artery may cause unexpected bleeding. Therefore, inexperienced surgeons need caution when using this landmark.

5. Styloid process

The styloid process, a bony landmark, lies deep to the facial nerve. Therefore, when the surgeon reached the styloid process, the nerve has already been passed. Additionally, the accuracy of this landmark is compromised due to the cases of elongation, calcification of the stylohyoid ligament or absence⁷.

III. Identification of FNT using multiple landmarks

Due to the lack of consensus on the best single landmark to use, it is now becoming standard to utilize multiple landmarks when identifying and locating FNT⁵.

1. Tragal pointer and junction of posterior belly of digastric muscle and SCM

Using tragal pointer and posterior belly of digastric muscle is the most widely used method. After incision, the cartilage of the pointer is followed medially. The tragal pointer is located superficially to the main trunk of the facial nerve and points to the deeply located main trunk, thereby indicating that FNT is near. Then, the junction of the posterior belly

of the digastric muscle and SCM is used for FNT identification. This junction is located approximately 4mm inferior to FNT and at the same depth as the main trunk. Then, FNT can be located using a nerve stimulator when approaching this junction³⁾.

The dissection method of posterior belly of digastric muscle is as following. The tail of the parotid gland is located at the anterior border of SCM. The tail of the parotid gland is separated from SCM and from the cartilaginous external auditory canal. The greater auricular nerve was divided as close to the parotid gland as possible to preserve the posterior branch. The parotid gland is retracted medially and blunt dissection is performed to the posterior border of the gland. Then, SCM is retracted posteriorly and the posterior belly of digastric muscle will be visualized¹³⁾. Tracing the posterior belly of digastric muscle upwards and backwards to the mastoid process will encounter the FNT.

2. Tragal pointer, posterior belly of digastric muscle and tympanomastoid suture

Some authors introduced methods for identifying FNT using the tympanomastoid suture, posterior belly of digastric muscle and tragal pointer, together during parotid surgery^{4,14,15)}. The dissecting methods until the tragal pointer and the posterior belly of digastric muscle are the same as described previously, and the tympanomastoid suture serves as a more specific guide to locate FNT. Between the tragal pointer and the superior border of the posterior belly of digastric muscle, deeper to the level of these

landmarks, the tympanomastoid suture is palpable. This region containing tympanomastoid suture is identified as the “valley” of the nerve and FNT would be found a few millimeters inferiorly at this level^{14,14)}. Using tympanomastoid suture is controversial as described previously. This method can be useful in cases where it is difficult to find facial nerves due to recurrence or surrounding lesions.

3. Use of triangle made by mastoid process, posterior belly of digastric muscle and posterior border of mandibular ramus,

Borle et al. proposed an anatomical triangle for ease of identification of FNT¹³⁾. Briefly, the first line starts from the tip of the mastoid process, along the superior border of the posterior belly of digastric muscle. The second line is drawn along the posterior border of the ramus after palpation. The third line runs anteriorly from the tip of the mastoid process until it joins the second line along the posterior border of the ramus(Fig. 5). FNT is often found within this triangle, just above the angle formed at the tip of the mastoid process with blunt dissection. The mean distance of FNT from the angle of mastoid process tip was reported as $12.18 \pm 2\text{mm}$ (range 9~15mm). This method uses another landmark, the posterior border of the ramus, but it is similar to existing methods in the concept of finding FNT around the mastoid process.

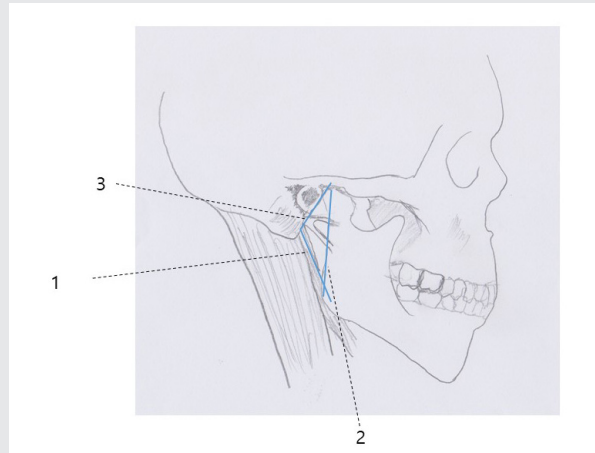


Figure 5. The anatomical triangle for the identification of the facial nerve trunk. The first line (1) extends from the tip of the mastoid process along the superior border of the posterior belly of digastric muscle. Second line (2) is drawn along the posterior border of the ramus after palpation. The third line (3) runs anteriorly from the tip of the mastoid process, until it joins line 2 along the posterior border of the ramus. The facial nerve trunk is commonly located within this triangle, just above the angle formed by line 1 and 3.

IV. Summary

In this review, we tried to introduce clinically meaningful methods for the localization of facial nerve trunk. The tragal pointer, the posterior belly of digastric muscle and the tympanomastoid suture are the most frequently described landmarks in literature. However, no single landmark is best to use and it has now become standard practice to utilize multiple landmarks. The preference of landmark could be changed by the major of the surgeon or the location of the tumor of the patients. Accurate knowledge of the anatomy and combining these landmarks which were convenient to surgeon would

minimize the risk of nerve injury and achieve optimal surgical outcomes.

Conflict of interest

No conflict

참고문헌

1. Tabb HG, Scalco AN, Fraser SF. Exposure of the facial nerve in parotid surgery. (Use of the tympanomastoid fissure as a guide). *Laryngoscope* 1970;80:559-67. <https://doi.org/10.1288/00005537-197004000-00004>.
2. Elvan O, Bobus A, Erdogan S, Aktekin M, Olgunus ZK. Fetal anatomy of the facial nerve trunk and its relationship with posterior auricular artery. *Surg Radiol Anat* 2019;41:153-9. <https://doi.org/10.1007/s00276-018-2126-x>.
3. Ji YD, Donoff RB, Peacock ZS, Carlson ER. Surgical Landmarks to Locating the Main Trunk of the Facial Nerve in Parotid Surgery: A Systematic Review. *J Oral Maxillofac Surg* 2018;76:438-43. <https://doi.org/10.1016/j.joms.2017.06.039>.
4. Shah AS, Nair S, Pavithra V, Aishwarya JG, Brijith KVR, Thakur D. Anatomical and Surgical Study to Evaluate the Accuracy of "C-M-S" Technique in Facial Nerve Identification During Parotid Surgery. *Indian J Otolaryngol Head Neck Surg* 2021;73:188-92. <https://doi.org/10.1007/s12070-020-02329-3>.
5. Muhleman MA, Wartmann CT, Hage R, Matusz P, Shoja MM, Tubbs RS, Loukas M. A review of the tragal pointer: anatomy and its importance as a landmark in surgical procedures. *Folia Morphol* 2012;71:59-64.
6. Witt RL, Weinstein GS, Rejto LK. Tympanomastoid suture and digastric muscle in cadaver and live parotidectomy. *Laryngoscope* 2005;115:574-7. <https://doi.org/10.1097/01.mlg.0000161343.85009.4c>.
7. Ru JA, Benthem PP, Bleys RL, Lubsen H, Hordijk GJ. Landmarks for parotid gland surgery. *J Laryngol Otol* 2001;115:122-5. <https://doi.org/10.1258/0022215011907721>.
8. Saha S, Pal S, Sengupta M, Chowdhury K, Saha VP, Mondal L. Identification of facial nerve during parotidectomy: a combined anatomical & surgical study. *Indian J Otolaryngol Head Neck Surg* 2014;66:63-8. <https://doi.org/10.1007/s12070-013-0669-z>.
9. Brintnall ES, Tidrick RT, Huffman WC. A simplified and rapid anatomical approach to parotidectomy. *AMA Arch Surg* 1955;71:331-6. doi:10.1001/archsurg.1955.01270150025002.
10. Zhong W, Ashwell K. Facial nerve trunk variations with surgical implications: A cadaveric study. *International Journal of Surgery Open* 2015;1:35-40. <https://doi.org/10.1016/j.ijso.2016.02.011>.
11. Meybodi AT, Moreira LB, Lawton MT, Preul MC. Anatomical assessment of the digastric branch of the facial nerve as a landmark to localize the extratemporal facial nerve trunk. *Surg Radiol Anat* 2019;41:657-62. <https://doi.org/10.1007/s00276-019-02222-x>.
12. Kanatas AN, McCaul JA. Use of digastric branch of the facial nerve for identification of the facial nerve itself in parotidectomy: technical note. *Br J Oral Maxillofac Surg* 2011;49:493-4. <https://doi.org/10.1016/j.bjoms.2010.10.019>.
13. Borle RM, Jadhav A, Bhola N, Hingnikar P, Gaikwad P. Borle's triangle: A reliable anatomical landmark for ease of identification of facial nerve trunk during parotidectomy. *J Oral Biol Craniofac Res* 2019;9:33-6. <https://doi.org/10.1016/j.job-cr.2018.08.004>.
14. Conley J. Search for and identification of the facial nerve. *Laryngoscope* 1978;88:172-5.
15. Righini CA. Facial nerve identification during parotidectomy. *Eur Ann Otorhinolaryngol Head Neck Dis* 2012;129:214-9. <https://doi.org/10.1016/j.anori.2011.12.002>.